

# roots

international magazine of endodontics

including

**ROOTS**  
S U M M I T

special

## interview

ROOTS SUMMIT “is not to be missed”

## case report

Automatic assistance:  
Freedom to navigate root canals

## technique

High-end technology  
for simplicity



**dti** Dental  
Tribune  
International



## The Power of ASP

### SWEEPS<sup>®</sup> Photoacoustic Endodontics

Looking for a more effective endodontic treatment?

- Shock Wave Enhanced Emission Photoacoustic Streaming
- Improved debridement and disinfection
- Minimally invasive
- Faster, safer and more effective
- More patient friendly

Visit [www.fotona.com](http://www.fotona.com) to find out more!

Available with  LightWalker<sup>®</sup> and SkyPulse<sup>®</sup>

For related patents see: [www.fotona.com/patents](http://www.fotona.com/patents)

Steve Jones

Co-chairman  
ROOTS SUMMIT



# ROOTS SUMMIT ~~2020~~ ~~2021~~ 2022!

**“Third time’s the charm”** is our rallying cry as we close in on this year’s ROOTS SUMMIT. When the world entered a pandemic two months before the originally scheduled dates, we thought we would reschedule the event for a couple of months later. Who knew it would be a couple of years?

After this extremely stressful, upsetting and isolating time for all, many of our participants are suddenly affected by war on their border. Let’s hope that the madness of this war in Ukraine will soon end. During this heartless and brutal time, it is more important than ever that we get together as friends, learning and improving our skills together.

The ROOTS Facebook group of around 30,000 members and ROOTS SUMMIT represent the camaraderie, fellowship and mutual interest endodontists around the world share. We do it every day online, but the strength of our online community over the last 20 or so years has been greatly enhanced by meeting on a semi-annual basis. Those who were in Berlin in Germany in 2018 had the experience of sharing their passion and profession with friends from around the planet, and many signed up immediately for the next ROOTS SUMMIT. At last count, we had people coming to join us from over 30 countries.

To appreciate the global appeal of ROOTS SUMMIT, you need look no further than our speakers list, which includes dentists from the Czech Republic, Egypt, France, Guatemala, India, Israel, Italy, Lebanon, Portugal, Romania, Spain, Switzerland, Syria and the US.

We are extremely appreciative of the fact that all our lecturers have stuck with us, as have the 40 sponsoring companies and a couple of hundred participants. The sponsors should be especially thanked, as they come to ROOTS SUMMIT because that is where research findings are translated into clinical practice better than any other meeting. They do not come to ROOTS SUMMIT because they have purchased a spot on the podium. They come because of the quality of the speakers and the enthusiasm and passion the participants have for endodontics! We all thank them for this open and ethical approach.

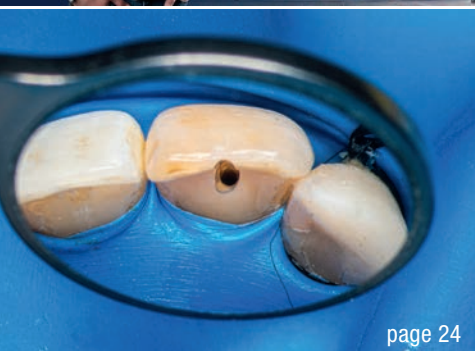
We are accepting registrations up to and including 26–29 May, and we hope that you will consider joining us in the beautiful city of Prague in the Czech Republic for the best and most inclusive meeting in endodontics.

Steve Jones  
Co-chairman of ROOTS SUMMIT

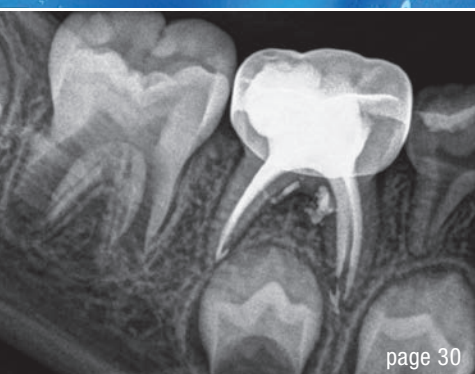



page 08



page 24



page 30

Cover image courtesy of  
FKG (www.fkg.ch).



## editorial

**ROOTS SUMMIT 2020 2021 2022!**

Steve Jones

03

## ROOTS SUMMIT special

**ROOTS SUMMIT “is not to be missed”**

An interview with Dr Gianluca Plotino

06

**ROOTS SUMMIT 2022—**

**“I can’t wait to experience the best endo meeting again”**

An interview with Dr Jenner Argueta

07

**ROOTS SUMMIT means “practical lectures,  
enough time for the topics, no need to skip anything”**

An interview with Dr Daniel Černý

08

Lecture programme, **abstracts and speaker** information

10

## case report

**Automatic assistance: Freedom to navigate root canals**

Prof. Eugenio Pedullà

20

**Digital technology** in endodontics

Dr Bartłomiej Karaś

24

**Root canal therapy of necrotic primary molars—  
using a single-file reciprocating system**

Drs Benjamín Rodríguez & Jenner Argueta

30

## technique

**High-end technology for simplicity**

Adj Prof. Philippe Sleiman

36

**The golden era of root canal shaping**

Dr Ahmed Shawky

38

## interview

**Laser protocol for peri-implantitis treatment**

An interview with Dr Michał Nawrocki

42

**“The correct choice of an animal model is vital”**

An interview with Dr Alexis Gaudin

46

## research

**The key role of vitamin D in immune health and regeneration**

Prof. Shahram Ghanaati, Dr Karl Ulrich Volz & Dr Sarah Al-Maawi

48

## manufacturer news

54

## meetings

**International** events

56

## about the publisher


submission guidelines

57

international imprint

58





RECIPROCATION

**THE SAFEST.\***  
**SIMPLY.**

Smooth to use, minimally invasive.  
Why choose anything else?

**Come to visit us at our booth FW09**

\*Based on cyclic fatigue internal tests, compared with equivalent competitors' instruments.

# ROOTS SUMMIT “is not to be missed”

## An interview with Dr Gianluca Plotino

By Franziska Beier, Dental Tribune International



Dr Gianluca Plotino

**ROOTS SUMMIT**, one of the most exciting endodontic events of this year, will kick off in May in Prague in the Czech Republic. One of the speakers will be Dr Gianluca Plotino, who will contribute to the rich programme with a hands-on course and a lecture. In this interview, Dr Plotino, who maintains a private practice specialising in endodontics and restorative dentistry in Rome in Italy, gives a preview of his congress topics and explains why endodontists should attend the event.

**Dr Plotino, you will be very busy at this year's ROOTS SUMMIT, as you will present two different topics. What do you find most rewarding about teaching?**

I love it when people thank me and tell me that my suggestions, tips and tricks have changed their professional lives! That is a priceless experience!

**For your hands-on course, which will focus on how to use different files for root canal anatomy, you encourage participants to bring well-preserved extracted teeth to practise on. What instruments and clinical techniques will participants get to know during your workshop?**

During my workshop, the clinical procedures for treating root canals having various difficulties will be explained and demonstrated on resin teeth in order to show the standard clinical techniques and the use of various instruments. I encourage all participants to bring natural teeth because trying the instruments on extracted teeth that have open access cavities will give them a better overview of the performance of the tools. I will show them how to integrate the reciprocating instruments R-PILOT (VDW) and RECIPROC blue (VDW) and the VDW.ROTATE rotary files into their practices.

**Could you briefly summarise your lecture on minimally invasive approaches in endodontic procedures and tell us what the take-home message for attendees will be?**

Following the trend of minimally invasive dentistry, the concept of minimally invasive endodontics emerged. However, I prefer to call it anatomically invasive endodontics as all endodontic procedures must be guided by the original root canal anatomy. In my lecture, I will describe how to find a good balance between maximising the preservation of the tooth structure and keeping endodontic procedures safe and efficient.

**What are you personally looking forward to at the upcoming ROOTS SUMMIT?**

All lectures given by my colleagues and friends deserve to be followed with the utmost attention, and I will be there to learn. In addition, I will be happy to see so many friends in person after such a long time!

**Can you name three reasons why everyone interested and involved in endodontics should come to the event?**

It's one of the most important endodontic events of the year, one of the first to take place as an in-person event after a long time, and it has a great scientific, cultural and social offering. It is not to be missed!

# ROOTS SUMMIT 2022—

## “I can’t wait to experience the best endo meeting again”

### An interview with Dr Jenner Argueta

By Franziska Beier, Dental Tribune International

**Dr Jenner Argueta** from Guatemala is a speaker at ROOTS SUMMIT, which is held from 26 to 29 May in Prague in the Czech Republic. During his hands-on course, the expert, who runs a practice that focuses on micro-endodontics and micro-restorative dentistry, will show attendees how to handle complex clinical scenarios with the help of 3D magnification. Prior to the event, Dr Argueta shared how this technology can benefit dental professionals and what he is most looking forward to at the event.

**Dr Argueta, what skills will participants learn in your hands-on course and how are these going to benefit them in treating patients?**

As clinicians, we face complex clinical scenarios in everyday practice, such as root canals with ledges, radicular resorptions, perforations and areas having difficult access during surgery. The objective of my workshop is to show attendees how to handle this type of situation in the most comfortable and predictable manner by using novel materials, state-of-the-art equipment and 3D magnification.

**During your hands-on course participants will experience how to work with 3D magnification. What are some of the advantages for dental professionals of using such technology?**

Having the possibility of moving the optical pod of the 3D microscope to any angle in order to focus on any area of the oral cavity while maintaining the correct ergonomic posture is a priceless advantage of 3D microscopic technology. This advantage is enhanced by high-definition 3D imaging with outstanding depth of field, which is transmitted to a monitor that is perfectly positioned in front of the clinician. These advantages make the clinical workflow easier, more predictable and more enjoyable.

**Is your course open to experienced endodontists as well as to dental students?**

Certainly! The goal is to show simplified techniques for solving complex clinical situations, and these simplified techniques will be applicable for both dental students



Dr Jenner Argueta

and trained endodontists. However, experienced endodontists will experience at first hand how 3D technology can contribute to their clinical practice.

**You have attended previous editions of the endodontic meeting. Looking back now, how would you sum up these events and how excited are you that you will be back at ROOTS SUMMIT in Prague soon?**

I attended ROOTS SUMMIT 2016 in Dubai in the UAE and ROOTS SUMMIT 2018 in Berlin in Germany. Both were high quality events in terms of organisation, science, lectures, camaraderie and friendship. I can't wait to experience the best endo meeting again. It is time to get the ROOTS family reunited in Prague!



# ROOTS SUMMIT means “practical lectures, enough time for the topics, no need to skip anything”

## An interview with Dr Daniel Černý

By Franziska Beier, Dental Tribune International



Dr Daniel Černý

**Dr Daniel Černý**, who has been the president of the Czech Endodontic Society since 2015, is one of many renowned and enthusiastic speakers at this year's ROOTS SUMMIT. Ahead of the event, Dental Tribune International spoke with Dr Černý about what visitors can expect from the city of Prague and from his lecture topic and asked him how he applies the things he has learned at ROOTS SUMMIT in his daily practice.

**Dr Černý, this year's ROOTS SUMMIT will take place in your home country. Can you tell us a bit about the event venue and also about Prague itself? What are three city highlights which international participants should not miss?**

I am excited about ROOTS SUMMIT coming to Prague. There are those highlights you can find in every guide, such as Charles Bridge, the astronomical clock in Old Town Square or Prague Castle, and they are certainly worth a visit.

But if you want to delve a little deeper, I recommend visiting Prague Botanical Gardens on an early morning in May. From there, you can climb up to the historic Vyšehrad Fortress to sense a bit of early Prague history and enjoy the great views. Afterwards you can casually stroll through the winding streets of the Praha 1 district with its small shops, restaurants and cultural institutions.

The congress venue is quite new and technologically advanced, and I believe the ROOTS community will enjoy it as much as I did last year when the annual meeting of the Czech Endodontic Society was held there.

**Together with Dr Radek Mounajjed, you will hold a lecture on the advanced adhesive endodontic/restorative concept. What can attendees expect to take away from it?**

The concept is something we have been developing and practising for the last 16 years. Its main message is that you can restore endodontically treated teeth with a high degree of predictability. It may not be simple or foolproof but following the correct steps will take you safely to the desired result while maintaining teeth with large structural damage. In this concept, we combine knowledge from modern biology of endodontics, adhesion to hard tissue, material science, biomechanics and occlusion. We want to present the key ideas that define this approach: reasonable structural savings, replacing the structure with similar material, adhesion and the fail-safe principle.

**What are some of the highlights of this year's ROOTS SUMMIT that you are personally looking forward to?**

I can imagine that the social events in Prague might be quite epic. The scientific programme of the congress is classic ROOTS SUMMIT: practical lectures, enough time for the topics, no need to skip anything. I am interested in Dr Catherine Ricci's lecture on large lesions and Dr Hugo Sousa Dias's lecture on the management of pulp canal obliteration. I also want to learn more on bioceramics from Dr Meetu Ralli Kohli and, of course, it is always nice to hear new thoughts from Dr Stephen Buchanan.

**How do you translate the things that you pick up at ROOTS Summit into your daily practice?**

Relatively easily. It is not that difficult since we all share similar ideas, and my knowledge gain is often in the clinical applications and from the tips on how to integrate new ideas into the current knowledge. If I don't apply what I have learned directly, then at least I have understood it and can subconsciously integrate it into my approach. And for this reason, I think meetings like ROOTS SUMMIT are better than hasty depersonalised scientific meetings or just reading. We are social beings; we like to see and hear one another.

**This will be your second time at ROOTS SUMMIT. What would you like to tell all the endodontists around the world who have not booked their ticket yet? Why should they attend this year's edition?**

I would give them three different reasons for booking their ticket. Firstly, because of the ROOTS SUMMIT programme and clinical approach as I described earlier. Secondly, because of the city of Prague in spring—beautiful, blossoming, welcoming and friendly. And finally, because of the opportunity to meet old friends after having been locked up for two years!

With four years since the last event in Berlin, this has been the longest break in ROOTS SUMMIT history. I think we should all make the most of it right now. *Carpe diem!*

AD

BEST

## ALPHA II & BETA

### Root Canal Obturation System

NEW

## B&L GP GAUGE & CUTTER

### Snip the GP Cone at the Exact Diameter!





# Lecture programme

## ROOTS SUMMIT 2022

### Day 1: Thursday, 26 May 2022

8:30–16:30 The first day is designated for hands-on coursework

### Day 2: Friday, 27 May 2022

8:30–10:00 Digital planning in intentional replantation and auto-transplantation  
*Dr Francesc Abella*

10:45–12:30 Large lesions:  
Endodontic or surgical treatment  
*Dr Catherine Ricci*

13:30–15:00 Bioceramics in endodontics  
*Dr Meetu Ralli Kohli*

15:45–17:15 Endodontic microsurgery:  
Management of complex cases  
*Dr Jaime Silberman*

### Day 3: Saturday, 28 May 2022

8:30–10:00 Root to crown: Advanced adhesive endodontic/restorative concept  
*Drs Daniel Černý & Radek Mounajjed*

13:30–15:00 Evidence-based treatment choices in modern endodontic treatment  
*Dr Igor Tsesis*

15:30–17:00 Endodontic algorithms in decision-making and clinical workflow  
*Dr Roberto Cristian Cristescu*

17:15–18:45 Two-dimensional vs 3D endodontics  
*Prof. Gianluca Gambarini*

### Day 4: Sunday, 29 May 2022

8:30–10:00 Minimally invasive approaches in endodontic procedures  
*Dr Gianluca Plotino*

10:45–12:30 Irrigation and disinfection of the root canal  
*Prof. Matthias Zehnder*

13:30–15:30 The art of endodontics in the age of MIE  
*Dr Stephen Buchanan*

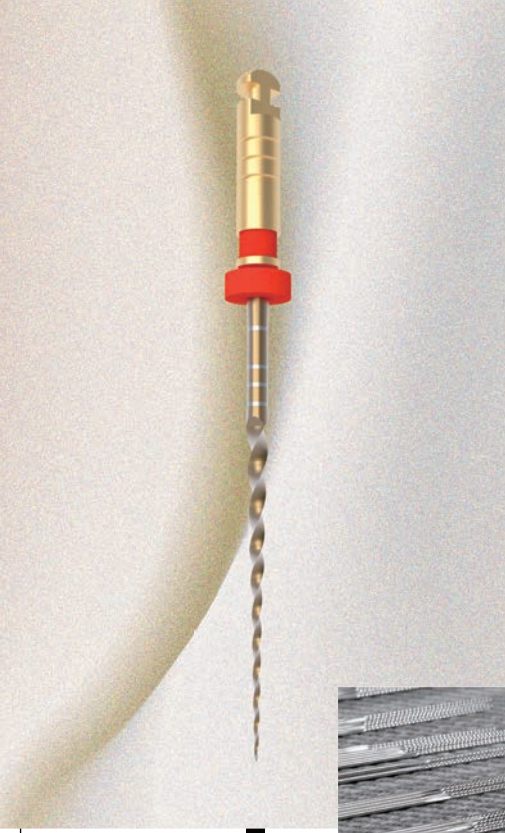Please visit [www.roots-summit.com](http://www.roots-summit.com) for the ROOTS SUMMIT 2022 programme.



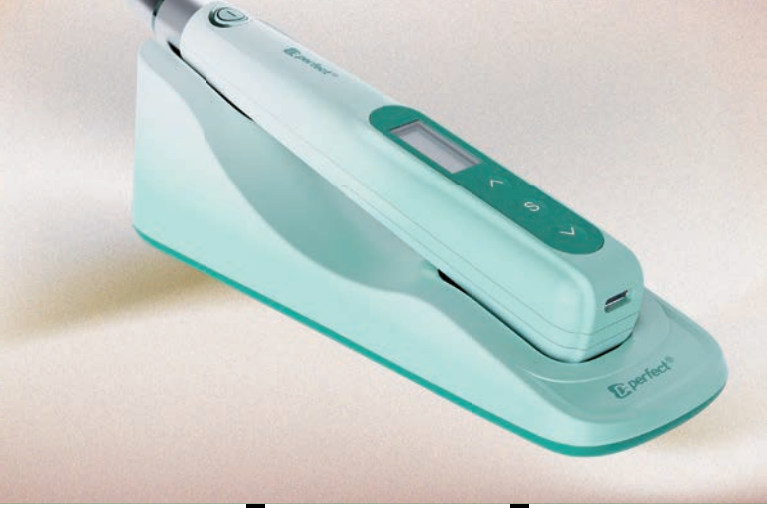# PERFECT



MG3 —



— ZR TOUCH




[www.dental-perfect.com](http://www.dental-perfect.com)




PERFECT  
ENDO.

**perfect**

since 2007



We are proud to provide you with  
the whole circle of endodontic solutions.



# ENDO.



# Speakers

## ROOTS SUMMIT 2022



**Dr Francesc Abella**  
(Spain)

Dr Francesc Abella graduated in 2005 in dentistry from the Universitat Internacional de Catalunya, Barcelona, Spain. From 2005 to 2014, he completed his master's degree and PhD in endodontics at the same university. He works in a private practice limited to endodontics and restorative dentistry in Barcelona, and in clinical endodontics, his areas of special interest include CBCT in endodontics, microcomputed tomography, dental anatomy, dental traumatology, periapical pathology, adhesive restoration and restoration of endodontically treated teeth. Besides his work in private practice, he is involved in endodontic research projects in the postgraduate endodontic programme of the Universitat Internacional de Catalunya.

Over the years, Dr Abella has given several lectures and hands-on courses worldwide. He is the author of several papers in peer-reviewed journals and part of the expert committee convened by the European Society of Endodontology on the use of CBCT. Dr Abella is also an active member of the Asocia-

cion Española de Endodoncia [Spanish association of endodontics] and the secretary of the Sociedad Española de Odontología Conservadora y Estética [Spanish society of conservative and aesthetic dentistry].



**Dr Stephen Buchanan**  
(US)

Dr Buchanan received his dental degree in 1978 from the University of the Pacific Arthur A. Dugoni School of Dentistry in San Francisco, US. In 1980, he completed the endodontic graduate programme at Temple University in Philadelphia, US. He began pursuing 3D anatomy research early in his career. In 1989, he established Dental Education Laboratories, a state-of-the-art training facility devoted to hands-on instruction where he still teaches endodontic treatment, retreatment and segmented file retrieval. Early in his career, Dr Buchanan identified the power of video and film media in training and produced the award-winning video series, The art of endodontics. Dr Buchanan also holds a number of patents for dental instruments and techniques. Most notably, he was the first dentist to introduce



variable-tapered instruments in endodontic therapy and pioneered a system-based approach to treating root canals. Dr Buchanan is a diplomate of the American Board of Endodontics and a fellow of the International and American College of Dentists. He currently serves as a clinical guest professor at the Herman Ostrow School of Dentistry of the University of California and the University of California Los Angeles School of Dentistry and as a guest lecturer at Loma Linda University School of Dentistry. He maintains a full-time private practice limited to endodontics and implantology in Santa Barbara, California.



**Dr Daniel Černý**  
(Czech Republic)

Dr Daniel Černý received his dental degree from the Charles University's Faculty of Medicine in Hradec Králové, Czech Republic, in 1998. Between 1998 and 2007, he worked as an assistant professor at the same faculty. He completed his doctoral degree with a focus on adhesive post-endodontic treatment at Palacký University Olomouc in the Czech Republic in 2018 and has been a part-time faculty member at the university since 2019. Since 2001, he has maintained a private practice limited to adhesive dentistry and endodontics in Hradec Králové. Černý has been the President of the Czech Endodontic Society since 2015. He was the co-founder and first President of the Česká akademie dentální estetiky [Czech academy of dental aesthetics] from 2007 to 2009. From 2009 to 2013, he served on the editorial board of LKS—Časopis České stomatologické komory [journal of the Czech Dental Chamber]. He is also the co-founder of the Dental Summit congress in Prague, Czech Republic. He has been the co-owner and director of the HDVI continuing education institute since 2010. Dr Černý has contributed four chapters to dental books and lectures both nationally and internationally.



**Dr Roberto Cristian Cristescu**  
(Romania)

Dr Roberto Cristian Cristescu began his dental education in 1998 in Bucharest, Romania, where he studied dental medicine

at the Carol Davila University of Medicine and Pharmacy. In 2004, he pursued a master's degree in biomaterials science at the University POLITEHNICA of Bucharest, from which he graduated in 2006.

Moving on to Amsterdam, Netherlands, from 2008 to 2011, Dr Cristescu took part in an endodontic postgraduate programme at the Academic Centre for Dentistry Amsterdam. During his studies and in between his years of education, Dr Cristescu was able to attain a great deal of clinical experience while working as a general dentist at the Dan Theodorescu university hospital in Bucharest (2004–2005) and two practices limited to endodontics both in his hometown of Bucharest and his home of choice in Amsterdam.

In addition, he has held teaching positions in the UK and Portugal and is an active member of the Nederlandse Vereniging voor Endodontologie, European Society of Endodontology and American Association of Endodontists.



**Prof. Gianluca Gambarini**  
(Italy)

Prof. Gianluca Gambarini is head of endodontics and restorative dentistry at the Sapienza University of Rome, Italy, and director of the dental school's master of endodontics programme. He maintains a private practice limited to endodontics in Rome, where his focus is on endodontic materials and clinical endodontics.

As an international lecturer and researcher, Prof. Gambarini has held more than 500 presentations at world's most renowned international congresses and universities. He has also received several awards and led research projects funded by national and international grants. In addition to that, Prof. Gambarini is an active consultant in the development of new technologies, surgical procedures and materials for root canal therapy.

Furthermore, he holds patents concerning endodontic technologies he has developed. Currently, Prof. Gambarini serves as Chairman of the Clinical Practice Committee of the European Society of Endodontology.





**Dr Meetu Ralli Kohli**  
(India/US)

Dr Meetu Ralli Kohli earned her BDS from the Government Dental College and Research Institute, Bangalore, India, and pursued her DMD and specialty training in endodontics at the

University of Pennsylvania, Philadelphia, US. During the course of her training, she received the esteemed Louis I. Grossman Award, Samuel R. Rossman Scholarship and Sherrill Ann Siegel award and scholarship for demonstrating excellence in patient care, clinical skills and research. She is Clinical Associate Professor of Endodontics and the Director of the Continuing Education and International Programme at the Department of Endodontics of the University of Pennsylvania School of Dental Medicine. She also maintains a part-time private practice limited to endodontics in Pennsylvania.

Dr Kohli has published in national and international peer-reviewed journals and has contributed to books on microsurgical retreatment. Her publications have been recognised as best clinical research papers by the *Journal of Endodontics*. She is on the scientific advisory board as a reviewer for the *Journal of Endodontics*, *International Endodontic Journal* and *Quintessence International*, and is the associate editor of the *Color Atlas of Microsurgery in Endodontics*. Dr Kohli has served on the American Association of Endodontists Constitution and Bylaws Committee and currently serves on its Research and Scientific Affairs Committee. She is a diplomate of the American Board of Endodontics and an examiner for the Indian Board of Endodontics.



**Dr Radek Mounajjed**  
(Czech Republic)

Dr Radek Mounajjed graduated from the Damascus University Faculty of Dentistry, Syria, in 1994. He then completed his residency in general dentistry in 1997 and

in prosthodontics in 2000, respectively. He completed his PhD in 2004 at the Charles University Faculty of Medicine, Hradec Králové, Czech Republic. Dr Mounajjed has been working at the multidisciplinary

D.C.M clinic in Hradec Králové as a full-time prosthodontist since 2001, and at Palacký University Olomouc, Czech Republic, as an external teacher since 2012.

Dr Mounajjed is the author of many publications and book chapters. He has presented more than 150 talks, both nationally and internationally, and has been invited to speak at Harvard University and Mayo Clinic, both US.

On top of that, Dr Mounajjed is the co-founder of HDVI, an accredited dental continuing education centre in the Czech Republic. He is also a fellow of the Academy of Prosthodontics in the US and International College of Prosthodontists. Outside of dentistry, he enjoys building and flying radio-controlled model airplanes.



**Dr Gianluca Plotino**  
(Italy)

Dr Gianluca Plotino graduated in dentistry from the Università Cattolica del Sacro Cuore, Rome, Italy, in 2002. He obtained his PhD

there in 2009 and received

certification as first and second level professor in 2018. Dr Plotino works in his own private practice limited to endodontics and restorative dentistry in Rome. He has received several international prizes, published more than 90 articles in scientific peer-reviewed journals on various endodontic and restorative topics, and contributed numerous chapters to textbooks. Plotino is an associate editor of the *European Endodontic Journal* and the *Giornale Italiano di Endodonzia* and serves on the editorial board of several other journals. He is a certified member of the European Society of Endodontology, an international member of the American Association of Endodontists, and an active member of the Italian Academy of Endodontics and the Italian Society of Conservative Dentistry.



**Dr Catherine Ricci**  
(France)

Dr Catherine Ricci graduated from the Université Paris Diderot (Paris 7) in France in 1983. In the same year, she became a certified member of the Société Française



d'Endodontie [French society of endodontics]. Also, at Paris 7, she completed her postgraduate studies six years later while working as an assistant professor from 1986 to 1990. During this period, Dr Ricci decided on specialising in endodontics only. From 2001 to 2010, she represented Europe as regent director on the board for the International Federation of Endodontic Associations World Endodontic Congress. Today, Dr Ricci has among her achievements authoring work in various publications, lecturing nationally and internationally, and co-directing the postgraduate programme at the Université Nice Sophia Antipolis in France.



### Dr Jaime Silberman (US)

Dr Jaime Silberman is a graduate of the Universidad Peruana Cayetano Heredia, Lima, Peru, where he completed his dental education. He then received an MSc and a certificate in operative dentistry from the University of Iowa, Iowa City, US. Dr Silberman continued his postdoctoral education at Columbia University in the City of New York, US, where he received his specialty training certificate in endodontics and his DDS. Before settling in Palm Beach County, Florida, US, Silberman served as a full-time assistant professor in the Division of Endodontics at Columbia University for five years. Since 1997, he has been working in a private practice limited to endodontics in the New York/New Jersey area and later in Florida. Currently, Dr Silberman is a faculty member of the endodontic postgraduate programmes at Nova Southeastern University, Davie, Florida, US, and Columbia University. He has been invited to give lectures in New York, locally in the US and internationally in South America. In addition, Dr Silberman is a board-certified endodontist and a member of the American Association of Endodontists, American Dental Association and Florida Dental Association.



### Dr Igor Tsesis (Israel)

Dr Igor Tsesis received his DDM from the then Moscow Medical Stomatological Institute in Russia in 1990. In 2003, he graduated cum laude from the post-

graduate endodontic programme at the School of Dental Medicine of Tel Aviv University in Israel. Currently, he serves as an associate professor and director of graduate endodontics at this university. In addition, he is editor of the book *Complications in Endodontic Surgery* (Springer, 2014) and co-editor of the books *Vertical Root Fractures in Dentistry* (Springer, 2015) and *Evidence-Based Decision Making in Dentistry* (Springer, 2017). Dr Tsesis' research concerns the diagnosis and treatment of complications after root canal therapy and endodontic surgery. Most of his research has been published in internationally leading endodontic journals. Dr Tsesis is a past President of the Israeli Endodontic Society and a member of the Scientific Council of the Israeli Dental Association. He also serves on the scientific advisory board of the *Journal of Endodontics* and is an editor-in-chief of the *Evidence-Based Endodontics*.



### Prof. Matthias Zehnder (Switzerland)

Prof. Matthias Zehnder graduated from the University of Bern School of Dental Medicine in Switzerland in 1994, where he received his doctoral degree in dentistry in 1996. Subsequently, he worked in private practice and part time as a postdoctoral research fellow at the Department of Oral Cell Biology of the same dental school. Between 1998 and 1999, he was employed at the Department of Oral Biology and Periodontology of Boston University Henry M. Goldman School of Dental Medicine, Massachusetts, US. He then pursued specialist training in endodontics at Columbia University in the City of New York, US, from which he graduated in 2001. In addition, Prof. Zehnder completed his PhD at Turku University in Finland in 2005 and received the title of "docent" from the University of Zurich in Switzerland in 2007. Currently, he is the tenured Head of the Division of Endodontology at the Clinic of Preventive Dentistry, Periodontology and Cariology at the university.

Zehnder's main research interests are the development of dental biomaterials, diagnosis of pulpal disease using molecular markers and improvement of approaches to disinfection of dental hard tissue. He is a former associate editor of the *International Endodontic Journal*, current editor-in-chief of the *Swiss Dental Journal*, and on the editorial board of other scientific journals.



# Lecture abstracts

## ROOTS SUMMIT 2022

### Day 1: Friday, 27 May 2022

8:30–10:00

#### Digital planning in intentional replantation and auto-transplantation

*Dr Francesc Abella*

In recent years, primary endodontic treatment, nonsurgical retreatment and microscopical surgery have achieved success rates of around 90%. However, there are situations in which the tooth cannot be saved using these techniques. The first part of this lecture will discuss intentional replantation. This is an accepted endodontic treatment procedure in which a tooth is extracted and treated outside the oral cavity and then reinserted into its socket to correct an obvious radiographic or clinical endodontic failure. It should not be considered a last-resort treatment prescribed only for “hopeless” teeth as proposed by Grossman. Although intentional replantation is not a frequently performed procedure, it yields a tooth survival rate of 88% according to a recent meta-analysis. In addition, the new advances in computer-aided rapid prototyping (CARP) models (tooth replicas) and 3D-printed guiding templates allow us to apply this technique in a much more predictable way.

In situations where the tooth cannot be saved, there is the option of performing an auto-transplant (both open and closed apex). The complications observed in the past can be overcome thanks to advances in diagnostic and surgical techniques,

particularly CARP models and 3D-printed guiding templates. The digital planning not only allows for selection of the most suitable donor tooth according to tooth morphology, but also shows the ideal 3D position and the required dimensions of the alveolus during surgery. Moreover, the use of tooth replicas can reduce the additional socket time and possible donor tooth injury during the procedure. Through the results of two *in vivo* investigations, as well as clinical cases and videos, we will teach the digital step by step to plan all types of cases.

After this lecture, participants should:

- 1) know the main indications for intentional replantation, as well as how to digitally plan the whole process;
- 2) know the advantages and possible complications of tooth auto-transplantation; and
- 3) know the indications for the different types of auto-transplantation: fresh extraction sockets, early extraction sockets with soft-tissue healing, early extraction sockets with partial bone healing, and surgically created sockets.

10:45–12:30

#### Large lesions:

#### Endodontic or surgical treatment

*Dr Catherine Ricci*

Lesions are the result of the evolution of apical periodontitis and are due to bacterial proliferation. Sometimes, root canal disinfection allows, with



endodontic treatment only, healing with a suspension of clinical signs and complete tissue regeneration. However, when a large periapical lesion is diagnosed radiographically, most of the time, the first idea is to ask how to eliminate it and then who can remove it surgically: the general practitioner, the oral surgeon or possibly the endodontist.

But could we consider that a simple endodontic treatment can solve this problem, without any surgery? In fact, faced with this situation, the first step is a precise diagnosis to determine the origin of the lesion and ensure that it is a lesion of endodontic origin, in order to avoid treating endodontically vital teeth or performing unnecessary surgery. Different tests will be necessary (vitality tests, CBCT and clinical examination) and the analysis of the results and their comparison with the patient's perception will allow us to make this diagnosis and to determine our therapeutic choice between an endodontic or surgical treatment or both. Throughout this presentation, the participants will learn to diagnose and treat large periapical lesions on the basis of many clinical cases.

After this lecture, participants should:

- 1) know how to make a differential diagnosis of large lesions;
- 2) know how to choose the right treatment planning; and
- 3) know how to decide on the use of bone tissue regeneration.

13:30–15:00

### **Bioceramics in endodontics**

*Dr Meetu Ralli Kohli*

The advent of MTA two decades ago brought about a significant change in the clinical practice of endodontics: a material that suited our workspace and the periradicular tissue perfectly. It has been extensively investigated *in vitro*, animal and clinical studies. It has been used from the coronal-most application in the tooth as a pulp capping material to the apical end as a root end filling material. With due diligence in the literature, the material has our academic and investigative endorsement. However, there are limitations to the use of MTA, for example the inability to use it for routine obturation, its handling properties and its tendency to cause discoloration. Materials scientists in recent years have introduced several new and improved versions of bioceramics to the field. The lecture will provide an

overview of the current research in the literature on bioceramics. Clinical cases will be presented, demonstrating application, advantages and disadvantages in various aspects of endodontics.

After this lecture, participants should be:

- 1) able to understand the concept of bioactivity especially as an obturation material;
- 2) aware of key literature on bioceramics pertaining to use in endodontics; and
- 3) able to recognise various clinical scenarios where the material can be used effectively.

15:45–17:15

### **Endodontic microsurgery:**

#### **Management of complex cases**

*Dr Jaime Silberman*

Literature has shown that there is a tendency in the endodontic community to avoid challenging conditions owing to factors associated with a lack of surgical training and practice, the perception of the surgical endodontic procedures by our referrals and other specialists, and financial aspects. Over the last 20 years, the practice of endodontic surgery has changed dramatically. The development of microsurgical procedures, the capability of diagnosing, treatment planning and assessing our surgical cases with the use of computed tomography, the constant development of guided tissue/osseous regeneration techniques, and the use of 3D-printed surgical guides have allowed us, as clinicians, to confront the most challenging cases. The purpose of this lecture is to provide a clinical discussion of multiple challenging conditions faced during the daily practice of surgical endodontics based on a solid literature review.

After this lecture, participants should be able to:

- 1) evaluate and discuss the impact of microsurgical endodontics in challenging cases such as mandibular second molars, anatomically complex mandibular premolars and palatal roots of maxillary molars;
- 2) evaluate the significance of CBCT as a tool for the surgical endodontic management of complex cases, from diagnosis and treatment planning to the final outcome; and
- 3) describe and discuss multiple GTR and GBR techniques associated with surgical endodontic complex cases (allografts with membranes, PRF, Emdogain).



## Day 2: Saturday, 28 May 2022

8:30–10:00

### Root to crown: Advanced adhesive endodontic/restorative concept

*Drs Daniel Černý & Radek Mounajjed*

Long-term data show that survival of nonvital teeth has always been a challenge. Both endodontic and restorative dentistry contribute critically to the treatment outcome. The presented concept of care has been developed by both endodontists and prosthodontists over 18 years of cooperation. It is based on four main ideas common to both fields: tissue preservation (unnecessary hard dental tissue loss should be prevented); replacement with similar materials (lost tissue should be replaced with material of similar physical properties); adhesion (all components of reconstruction should adhere to each other) and safety (when failure occurs, it should not be catastrophic).

Over the years, the protocol has been extended from nonvital teeth only to teeth with compromised integrity and challenged vitality. The endodontist delivers a ready-to-use abutment tooth free of pathology for the final reconstruction regardless of the tooth vitality. In this lecture, the decision-making process, material selection, complete workflow and long-term outcomes will be presented.

After this lecture, participants should be able to:

- 1) identify clinically relevant factors for reconstruction of nonvital teeth and teeth with challenged vitality;
- 2) indicate the need for different adhesive tools to construct the build-up of the abutment tooth with fibre posts and various resin composites; and
- 3) describe critical details of ideal final restoration of nonvital teeth.

13:30–15:00

### Evidence-based treatment choices in modern endodontic treatment

*Dr Igor Tsesis*

The treatment alternatives for apical periodontitis include nonsurgical endodontic retreatment, surgical endodontic treatment, or tooth extraction, and in certain cases, a follow-up protocol may be considered. The long-term prognosis, the alternatives in case of treatment failure, post-treatment quality of life, and patient's preferences should all be recognised and incorporated in the treatment choice

considerations. A decision on intervention for an endodontically treated tooth with a periapical radiolucency should be based on the technical feasibility of the treatment, systemic factors and patient values.

This presentation will discuss a patient-focused clinical decision-making process regarding the management and preservation of natural teeth based on the principles of evidence-based medicine.

After this lecture, participants should be able to:

- 1) identify the main reasons for the persistence of endodontic disease and possible treatment alternatives;
- 2) recognise the possibilities and limitations of modern endodontic treatment; and
- 3) incorporate an evidence-based approach in the decision-making process on treatment choice.

15:30–17:00

### Endodontic algorithms in decision-making and clinical workflow

*Dr Roberto Cristian Cristescu*

This lecture will focus on some decision-making steps during endodontic clinical procedures in the dental office. The current standard of care requires dentists to base their actions on scientific evidence and to be able to put that evidence into clinical practice while keeping in focus the patient's quality of life during the treatment. We will follow some important guidelines for clinical endodontics and will exemplify them with clinical cases that reflect the diagnosis and treatment spectrum of a general dental office.

After this lecture, participants should:

- 1) have a clearer decision-making algorithm for their clinical work;
- 2) be able to understand how to start making their own clinical decision flowcharts for different endodontic procedures; and
- 3) have a better understanding of the possible outcomes of different treatment paths.

17:15–18:45

### Two-dimensional vs 3D endodontics

*Prof. Gianluca Gambarini*

This lecture will address the use of CBCT in endodontics for diagnosis, the treatment plan, access cavity design, working length determination, man-



agement of complex cases, obturation, restoration, follow-up and surgery. The various steps of the dental treatment will analyse the differences between 2D and 3D radiographs to demonstrate the benefits of routine use of CBCT technology. There will also be a focus on the use of clinical software for case assessment and navigation systems using 3D CBCT images.

After this lecture, participants should:

- 1) understand the advantages of CBCT in all the phases of endodontic treatment;
- 2) know how CBCT can be associated with endodontic and static/dynamic navigation software; and
- 3) be able to evaluate the possible use of dynamic navigation systems in surgical and nonsurgical endodontic treatment.

### Day 3: Sunday, 29 May 2022

8:30–10:00

#### Minimally invasive approaches in endodontic procedures

*Dr Gianluca Plotino*

Clinical studies demonstrate that long-term prognosis of root filled teeth is influenced by the quality of the restoration, as well as by the quality of the root canal therapy itself. The most recent trends in the restoration of endodontically treated teeth follow the concept of minimally invasive dentistry, proposing more conservative, less expensive and bioeconomic restorations, based mostly on adhesive dentistry and the introduction of new materials and technologies.

Following these trends, access procedures in endodontics and root canal preparation are changing in a conservative way, sometimes drastically if compared with the traditional concepts of cavity outline opening and coronal straight-line access to reach the apical region. The endodontic literature appears to be poor on demonstrating how these minimally invasive access procedures can influence the quality and prognosis of root canal therapy. This lecture will analyse the technical procedures of minimally invasive access and preparation in different clinical situations and the possible mechanical improvements derived from these.

Moreover, the limits of these procedures will be critically analysed to define how minimally invasive

clinicians should be in order to ensure gold standard endodontic treatments.

After this lecture, participants should:

- 1) understand the basic concepts of minimally invasive endodontic procedures;
- 2) be able to apply new strategies to optimise minimally invasive endodontic procedures; and
- 3) be able to evaluate critically the advantages and disadvantages of present technologies, instruments and techniques.

10:45–12:30

#### Irrigation and disinfection of the root canal

*Prof. Matthias Zehnder*

This lecture will discuss what we need to do to obtain adequate disinfection of the root canal system with subsequent healing of periapical lesions. The most important aspect in this context is neither new tools nor special disinfectants, but a thorough understanding of the actual case we are treating. It will be shown that not all endodontic cases are equal and how we can address the more difficult cases by choosing our approach wisely. One core issue is timing.

How much time are we prepared to spend on a case, and what is best for our patient? In this context, the effectiveness and compatibility of the means we use to debride and disinfect are key. The other core issue is anatomy. While many clinicians are aware of the macroanatomy of root canal systems, fewer consider microanatomy.

After this lecture, participants should be able to:

- 1) appreciate the importance of diagnostics and anatomy in current and future treatment concepts;
- 2) understand the efficacy versus the effectiveness of different protocols under different conditions; and
- 3) understand the core characteristics and interactions of the main chemical agents used in root canal cleansing.

13:30–15:30

#### The art of endodontics in the age of MIE

*Dr Stephen Buchanan*

No Abstract Available



# Automatic assistance: Freedom to navigate root canals

Prof. Eugenio Pedullà, Italy

## Introduction

Mechanical root canal preparation with nickel–titanium (NiTi) instruments activated by endodontic motors has made root canal preparation more predictable in the clinical setting, as well as significantly reduced working time and stress on the practitioner. Since the introduction in the late 1980s of centric continuous rotary motion for NiTi files, new mechanised techniques have been proposed with the aim of minimising the risk of fracture of endodontic instruments by exploiting the benefits of different kinematics in endodontic therapy.

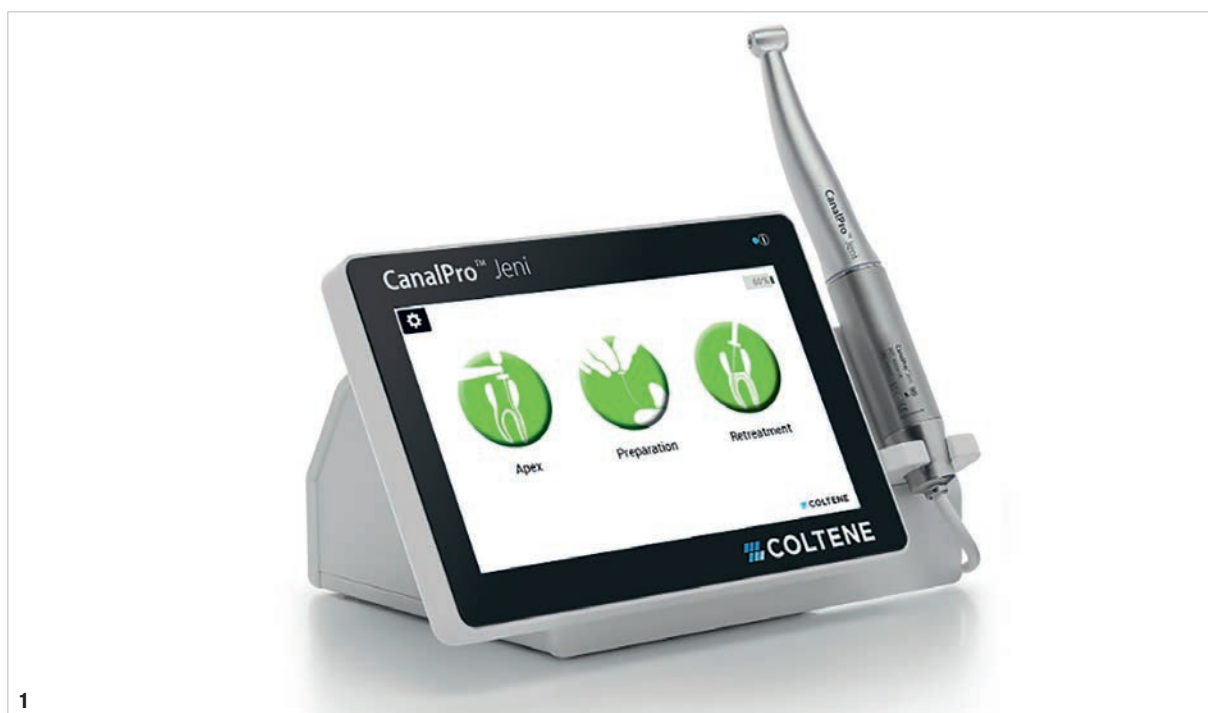Thus, trans-axial, eccentric and reciprocating motion were introduced for the activation of NiTi instruments to shape root canals. In particular, reciprocating motion (better classified as partial reciprocation with rotational effect) has asymmetrical angles of rotation in the anti-clockwise and clockwise directions.

Continuous rotation and reciprocation have advantages but also disadvantages. Indeed, the former allows easy progres-

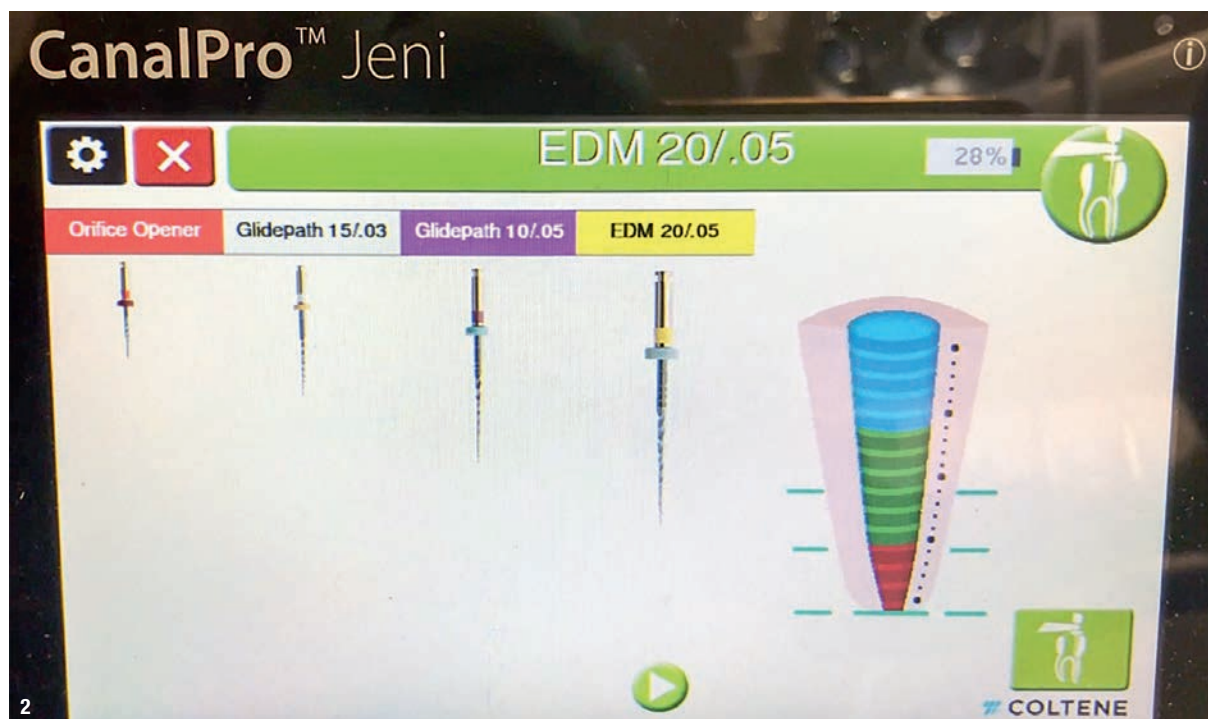sion in root canals, but it does not protect the NiTi files from the risk of torsional fracture. Reciprocation increases file fracture resistance, reducing the screw-in effect but increasing the possibility of apical debris accumulation or extrusion.

Therefore, hybrid motions have been designed to combine rotary and reciprocating movements, taking advantage of each. Hybrid endodontic motors have just two movements, changing the angle during activation, passing from a complete (360°) rotation to a single asymmetrical reciprocation with fixed and asymmetrical angles (clockwise differing from anticlockwise) depending on the torsional stress applied to the NiTi file.

However, digital technology can facilitate continuous control of the file movement. The CanalPro Jeni endodontic motor (COLTENE; Fig. 1) allows fully automatic assistance in the shaping of root canals using different rotary motion, angle, speed and torque, automatically changed by the complex and patented algorithms of the motor. Rotary movement, speed and torque are



**Fig. 1:** The fully automatic CanalPro Jeni endodontic motor (COLTENE).



**Fig. 2:** Apex reached as signalled by the integrated apex locator on the touch screen monitor of CanalPro Jeni.

continuously adapted to the prevailing conditions in the root canal. The file movement of Jeni motion is adapted to the changing pressure exerted on the instrument. Light pressure is applied steadily from coronal to apical.

The reaction time of CanalPro Jeni is in the millisecond range and thus significantly faster than that of humans. This means greater safety, because of the reduced risk of NiTi file fracture and decreased subjectivity of treatment because the advancement of the files is always automatically controlled by the motor. With CanalPro Jeni, the dentist just holds the contra-angle handpiece and the motor does the rest, adjusting to the root canal anatomy and thereby increasing the efficiency and reducing treatment errors.

CanalPro Jeni not only changes the file movements, but also continuously indicates the position of the file in the root canal with its integrated apex locator (Fig. 2) and suggests rinsing with irrigants when file progression is compromised. This can guide the clinician to irrigate for longer in complex cases.

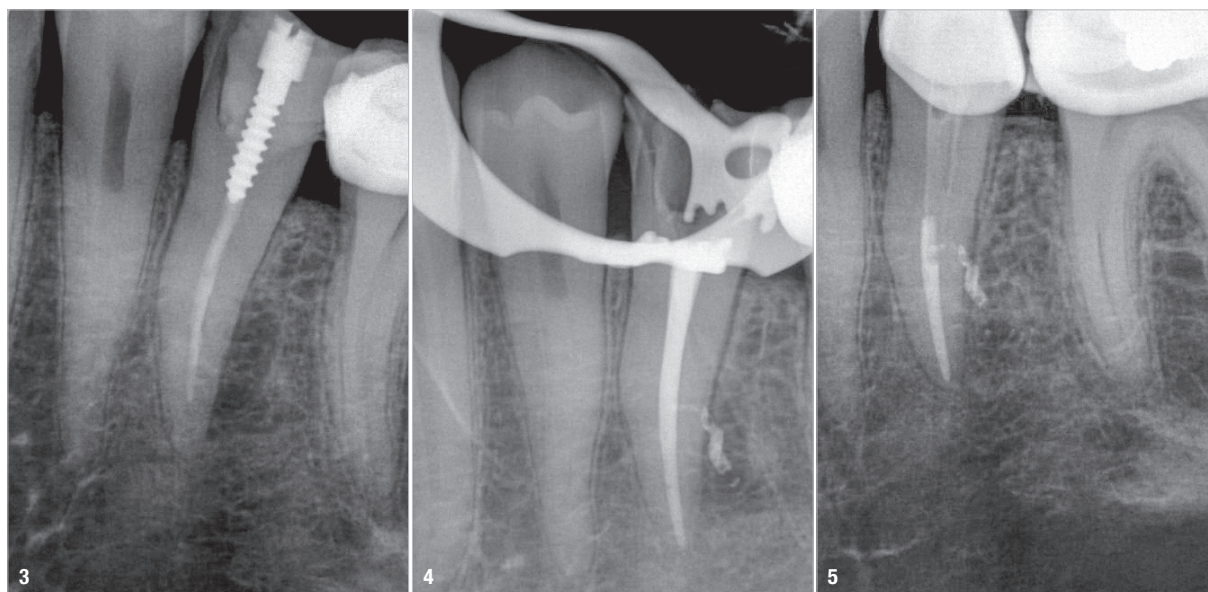
The functionalities of CanalPro Jeni provide many advantages to dentists. The motor starts in continuous rotation; however, if the file is stopped and blocked in the root canal for any reason, the dentist will be safe and will be able to continue his or her work easily because the motor will activate the file with movements employing more reverse action until the file is unblocked.

Safety is also increased by the signal to rinse. When progression of the file is not allowed (such as in the case of debris accumulation), the clinician could exert greater

pressure on the file in order to obtain instrument advancement. However, CanalPro Jeni will intercept this and immediately advise the dentist with a long beep and by activating reverse rotation to suggest the need to stop, remove the file and irrigate rather.

Efficiency is ensured with CanalPro Jeni because the movement by the motor always ensures some degree of file advancement and cutting action. Therefore, it is possible to advance into the root canal without the need to perform the up and down motion controlled by the subjective tactile feedback of the clinician. Moreover, brushing motion with lateral cutting action on root canal walls to favour the progression of the file is also allowed by all the different movements effected by the motor. This consistent forward motion can ultimately save time during mechanical preparation. Root canal therapy and retreatment can be performed safely and efficiently.

Different file systems can be selected in the control program via the touch screen. Presently, the HyFlex EDM, HyFlex CM, MicroMega One Curve, MicroMega 2Shape and Remover for HyFlex and MicroMega file systems (all COLTENE) are already pre-installed in the software. In addition, the Doctor's Choice program gives the clinician the freedom to choose even different movements, like twist off (continuous rotation), twist on (continuous rotation with an alternative movement automatically activated when the set torque is surpassed), and reciprocating motion with settable milliseconds in order to decide how much and in which direction the NiTi instruments should be moved and the anticlockwise motion that is helpful when the tip is blocked.



**Fig. 3:** Pre-op radiograph of tooth #35. Incomplete endodontic obturation and a metal post were visible. A radiolucent periradicular lesion was detectable laterally on the distal aspect of the root. **Fig. 4:** Final radiograph of the endodontic retreatment (with the dental dam still on the tooth) showing complete and compact filling of the endodontic space, including the filling of a lateral canal and a little extrusion of sealer though it in the site of the lateral radiolucent lesion. **Fig. 5:** Follow-up radiograph at one year of the endodontic retreatment of tooth #35. Healing of the lateral radiolucent lesion confirmed the success of the endodontic retreatment performed with HyFlex Remover and EDM files activated by CanalPro Jeni.

## Case 1

In this first case, periapical periodontitis of tooth #35 is presented. The 44-year-old patient was first diagnosed with acute pulpitis of a mandibular premolar in 2017. Tooth #35 received root canal therapy and was then obturated with gutta-percha and sealer and restored with a metal post and composite materials. Unfortunately, the success of the treatment was not long-lasting. In 2020, the patient presented at our practice with acute pain symptoms and pain on percussion or biting. The preoperative periapical radiograph showed periapical periodontitis even laterally on the distal aspect of the root of tooth #35 (Fig. 3). The patient finally agreed to the necessary endodontic retreatment.

The first step in retreatment is the complete removal of inadequate or aged gutta-percha filling. Therefore, after the removal of the composite and metal post with ultrasonic tips, the 30/07 HyFlex Remover file (COLTENE), activated by the automatic Jeni motion of CanalPro Jeni, was used for the gutta-percha disassembling procedure. The fast and continuous changes of the movement performed by the automatic Jeni motion, combined with the efficiency of the heat-treated HyFlex Remover file, allowed fast and safe removal of the previous obturation material. In a recent paper, it was reported that the use of the innovative CanalPro Jeni kinematics accelerates the time for removal of root filling materials.<sup>1</sup> Indeed, within seconds, clean access to the apical third was achieved.

Subsequently, when the untreated part of the root canal was reached, scouting was done with a #10 and

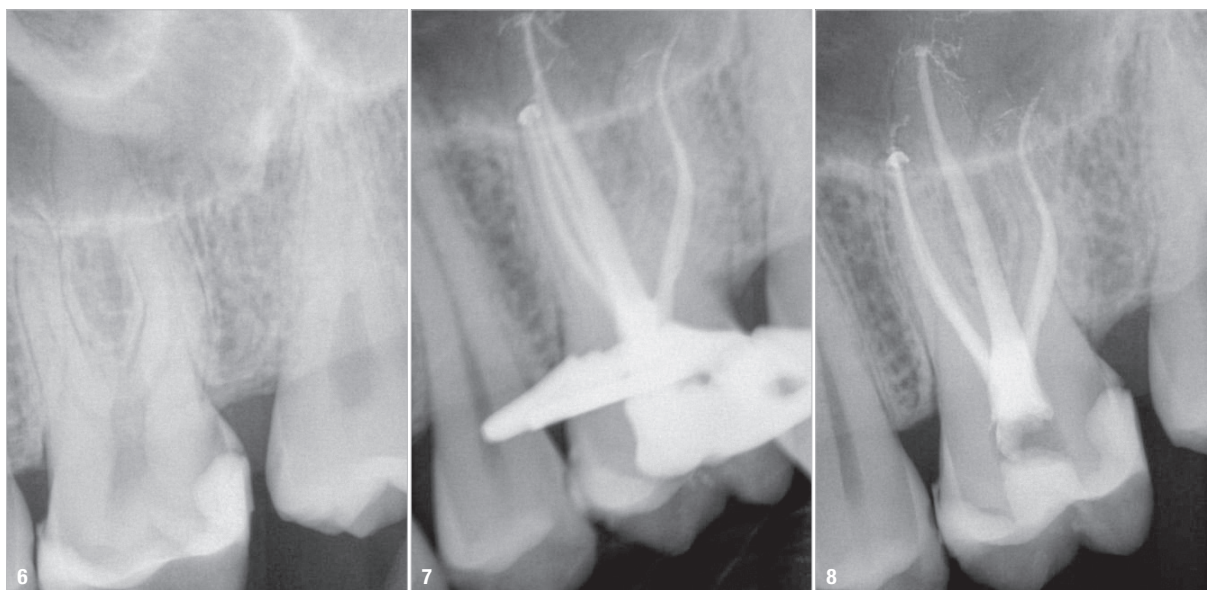
15 K-type file. After determination of the working length (WL), the HyFlex EDM file system, activated by the fully automatic Jeni motion of CanalPro Jeni, was used in the single-length technique. Thus, after the 20/05 HyFlex EDM file reached the WL, the 25/~ HyFlex EDM OneFile and then the 40/04 file were used to WL. Jeni motion allowed the files to reach the WL just by guiding the files in the apical direction and removing the files from the root canal and irrigating on the sounding of the long beep. After this, the reinsertion of the file into the root canal was deeper than the previous depth of insertion, and this procedure was repeated until the WL was reached. In this case, the 20/05 file reached the WL in one pass, the OneFile in two passes and the 40/04 file in one pass of the instrument. The 50/03 HyFlex EDM finishing file was then used to 1 mm from the WL in order to create a stop for the 50/02 master cone used for the micro-seal thermoplasticised obturation technique.

The postoperative periapical radiograph showed perfect adaption of the obturation material used and filling of a large lateral distal canal that probably was the cause of the periapical lesion and symptoms of the tooth (Fig. 4). The one-year follow-up radiograph showed the healing of the periapical lesion, and the patient reported no symptoms during that time (Fig. 5).

## Case 2

A 32-year-old male patient presented at our practice, having been referred to us by his dentist for further endodontic evaluation of pain in the left side of his maxilla. During the





**Fig. 6:** Pre-op radiograph of tooth #26 showing decay under a previous composite restoration close to the pulp chamber that caused the patient pain. Irreversible pulpitis was the diagnosis. **Fig. 7:** Periapical radiograph of tooth #26, the beam angulated mesially to verify the correct obturation of the separate mesiobuccal canal after endodontic treatment with the HyFlex EDM file system and CanalPro Jeni. **Fig. 8:** Post-op periapical radiograph of the endodontic treatment of tooth #26.

initial examination, the patient experienced pain when a gentle jet of cold air was blown between teeth #26 and 27. The preoperative periapical radiograph confirmed the suspected decay of the distal root of tooth #26 under its previous composite restoration (Fig. 6). The patient was informed about the situation, and he agreed to endodontic therapy in order to obtain a predictable result of the treatment.

The entire treatment was performed exclusively under the microscope. This allowed optimisation of the view of the work field.

Full preparation was performed with a sequence of flexible NiTi files using CanalPro Jeni. After placement of a dental dam, the access cavity was prepared, and coronal flaring was obtained with the HyFlex EDM orifice opener. In addition, to the composite in the canal entrance, the extreme curvature of the root canals, especially in the apical third of the distal one, presented a challenge.

In the mesiobuccal, independent second mesiobuccal and distal buccal root canals, the 15/.03 HyFlex EDM file was followed by the next size files, 10/.05 and 20/.05. The palatal root canal was prepared with the same sequence, plus the use of the 25/~ HyFlex EDM OneFile and 40/.04 HyFlex EDM file. CanalPro Jeni suggested irrigation for the progression of the files with a long beep. This happened more in the second mesiobuccal and distal root canals, where the preparation was more difficult because of the narrow and curved anatomy. After a final rinse and drying procedure with dedicated paper points, the carrier-based thermoplasticised gutta-percha obturation technique was used to fill the root canals (Figs. 7 & 8).

## Conclusion

Digital endodontic assistance systems such as CanalPro Jeni navigate the dentist step by step through mechanical and chemical preparation by adjusting the variables of file movement. The instantaneous control of CanalPro Jeni improves the safety and efficiency of root canal therapy, reducing the subjectivity of tactile feedback control and possible errors during endodontic treatment and retreatment.

## contact



**Prof. Eugenio Pedullà** graduated in dentistry and dental prosthetics from the University of Catania in Italy in 2003. He obtained his PhD at the same university in 2007. From 2009 to 2014, he was a research fellow at the University of Catania, where he is now associate professor of conservative dentistry and endodontics.

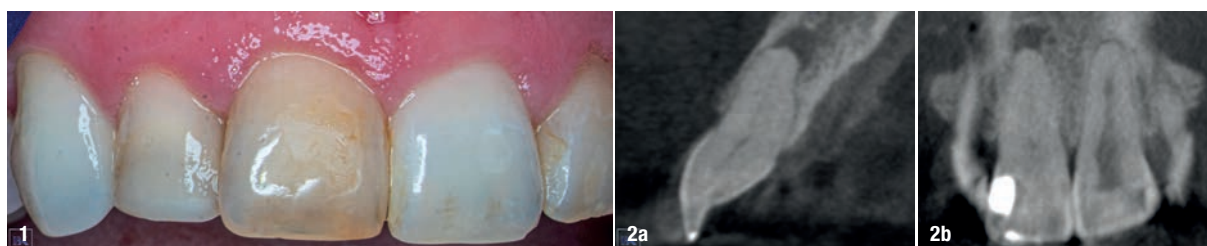
Prof. Pedullà carries out his clinical and research activities mainly in the field of endodontics and conservative dentistry.

Prof. Pedullà is an active member of the Italian Academy of Endodontics and Società Italiana di Odontoiatria Conservatrice (Italian society of conservative dentistry), an ordinary member of the Italian Society of Endodontics, an international member of the American Association of Endodontists and a member of the European Society of Endodontology. He can be contacted at [eugenioipedulla@gmail.com](mailto:eugenioipedulla@gmail.com).

# Digital technology in endodontics

## Use of dynamic navigation to access and shape canals in teeth with pulp canal obliteration after trauma

Dr Bartłomiej Karaś, Poland



**Fig. 1:** Intra-oral view of the initial situation. Visible discoloration of the right central incisor. **Figs. 2a & b:** CBCT scan, sagittal (a) and coronal planes (b). Visible pulp canal obliteration and periapical lesion.

### Introduction

Pulp canal obliteration (PCO) is one of the complications which may occur in dental pulp after tooth trauma. It is also one of the mechanisms of pulp healing after trauma; however, pulp necrosis too may occur as a result of trauma. PCO can be recognised clinically as early as three to 12 months after trauma. PCO is an effect of the deposition of hard tissue, such as sclerotic or reparative dentine; however, the underlying mechanisms of PCO are still unclear. Oginni et al. report that partial obliteration was present in 56.9% and total obliteration in 43.1% of 276 cases of teeth after trauma, and they suspect that the mechanism of formation of obliteration is related to damage to the neurovascular supply.<sup>1</sup>

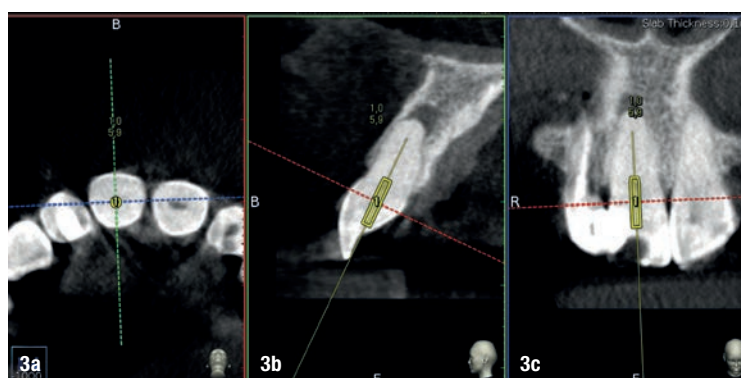
The types of injuries mostly responsible for PCO have also been investigated. It was revealed that luxation, subluxation, intrusion and concussion are the most frequent causes of trauma. In the case of concussion, teeth with developing apices have a better prognosis and a lower likelihood of developing PCO.

Jacobsen and Kerekcs report that, although PCO necrosis and periapical disease are rare, they can occur after many years after the trauma. Bastos and Cortes emphasise that crown discoloration can be present in many cases and can be a first visible factor of PCO. Usually, the colour changes to dark yellow or even grey.

Management of PCO owing to a lack of patency can be very challenging for clinicians. Creating a proper access cavity (one that will not sacrifice too much tooth structure) and locating the root canal orifice in the calcified tooth requires experience and additional equipment, like a dental operating microscope. According to Carvalho and Zuolo, using the dental operating microscope increases the probability of finding all the orifices located in the pulp chamber floor. Boveda and Kishen state that creating a constricted access cavity should be very valuable in terms of a long-term prognosis, but can require an additional diagnostic protocol, for example capturing a CBCT scan before the treatment.

### Dynamic navigation

Nowadays, thanks to the development of modern technologies, it has become possible to perform treatment more conservatively and more predictably. The Navident dynamic navigation system (ClaroNav) is to a clinician what a GPS is to a driver. Navident uses a stereoscopic camera and marker (or reference) spheres so that the camera can track the movement of the operator. Also the system requires a CBCT scan of the patient and a digital guide, which is designed in the Navident software. After designing the guide, the clinician needs to register the patient's teeth to calibrate the CBCT scan with a special tool (the wand). After registration of the patient's teeth, the clinician needs to calibrate the drill and the handpiece with dedicated markers. With



**Figs. 3a-c:** Planning of the virtual guide in Navident software (ClaroNav). The axis and depth of the preparation are shown.



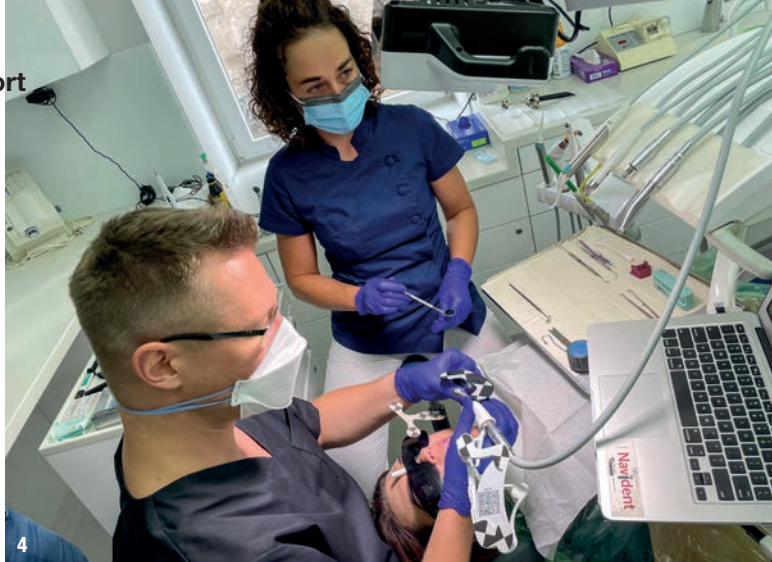# FONE<sup>®</sup>



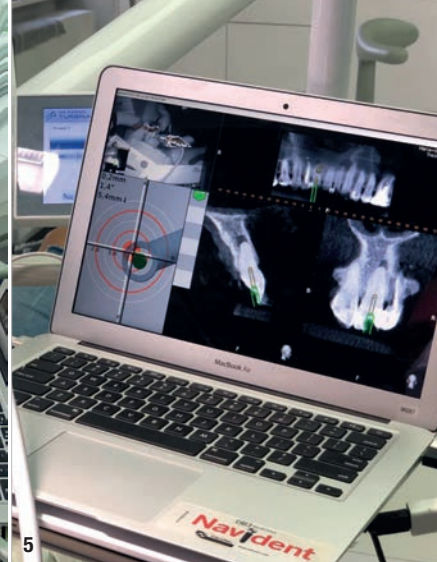
PROFESSIONAL PRECISE RELIABLE  
ENDODONTIC SOLUTIONS

[www.fanta-dental.com](http://www.fanta-dental.com)





**Fig. 4:** Calibration of the Navident device. The tracers and camera are shown. **Fig. 5:** Intra-op view of the software.



the combination of the prepared guide, tracking markers and dynamic tracking of the camera, the dentist can see the actual position of the drill and its angulation with a lag of 0.3–0.5 seconds on the computer screen. According to available data, the accuracy of the equipment is 0.1 mm and 1°, which is significantly better than CAD/CAM-fabricated guides for endodontic treatment. It must be considered that the accuracy of the procedure may differ depending on the clinician.

## Case 1

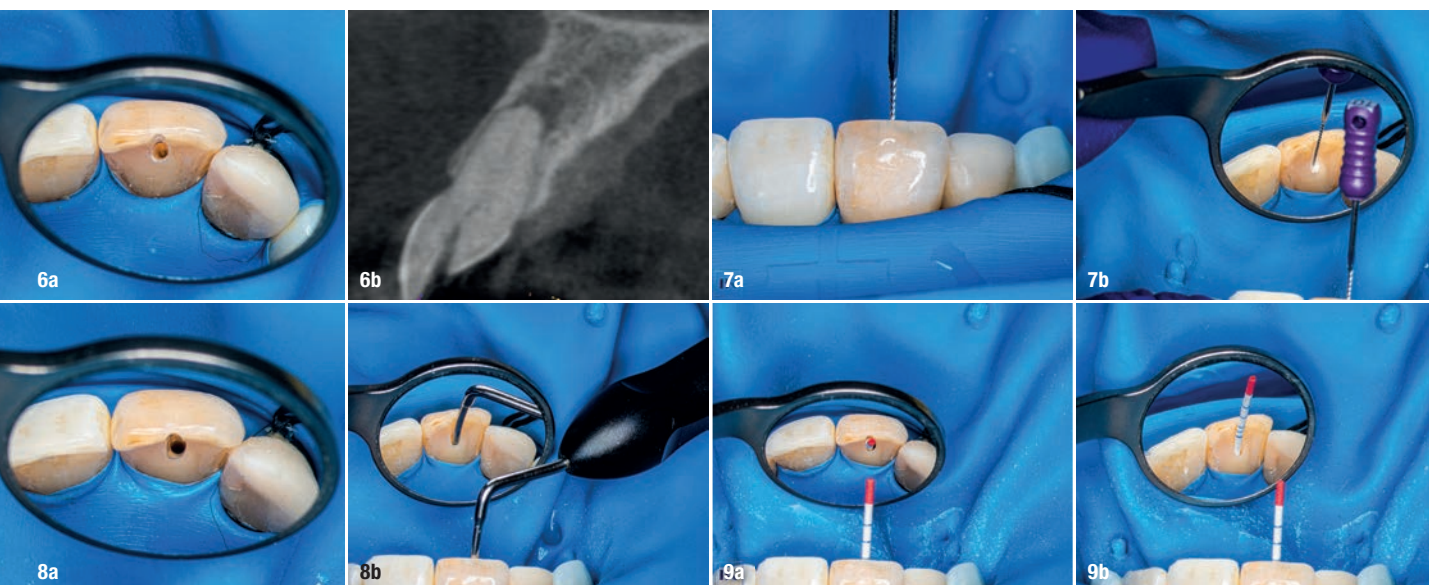
A 36-year-old female patient came to the dental office with discoloration and pain of the maxillary right first incisor (Fig. 1). In the medical history taking, she reported a trauma approximately 15 years earlier. During the radiographic examination in the office of her general dentist, PCO was revealed. She was referred for a CBCT scan and endodontic treatment.

During the consultation, the CBCT scan was performed with the 9000 C 3D with a voxel size of 0.1 mm (Carestream). The CBCT scan revealed a highly calcified pulp chamber

and an almost invisible trace of the root canal (Fig. 2). The patient was informed about the new, beneficial technology which can help to preserve additional tooth structure during treatment.

Before the treatment, the CBCT scan was uploaded to the software and the virtual guide was planned (Fig. 3). This is one of the most important parts of the protocol because during the treatment the Navident software tracks the handpiece and shows the correlation between the clinician's work and the already planned guide. If the depth or direction is missed on the guide, there is a very high risk of root perforation.

During the clinical procedure, the jaw tracker was placed on the patient's teeth and fixed with impression material. Registration of the patient's tooth position and calibration of the CBCT scan was performed with the help of the wand tool. The drill tag was attached to the handpiece, and the calibration of the handpiece and drill was performed with the calibration tool (Fig. 4). After all the registration and




**Figs. 6a & b:** First stage of the access cavity creation (a). CBCT check, sagittal plane (b). The axis of the access cavity was visible. **Figs. 7a & b:** Hand file scouting of the canal orifice. **Figs. 8a & b:** Final preparation (a). The size of the access cavity and of the root canal orifice was checked with the #80 hand plugger (b). **Figs. 9a & b:** Drying the canal before obturation.



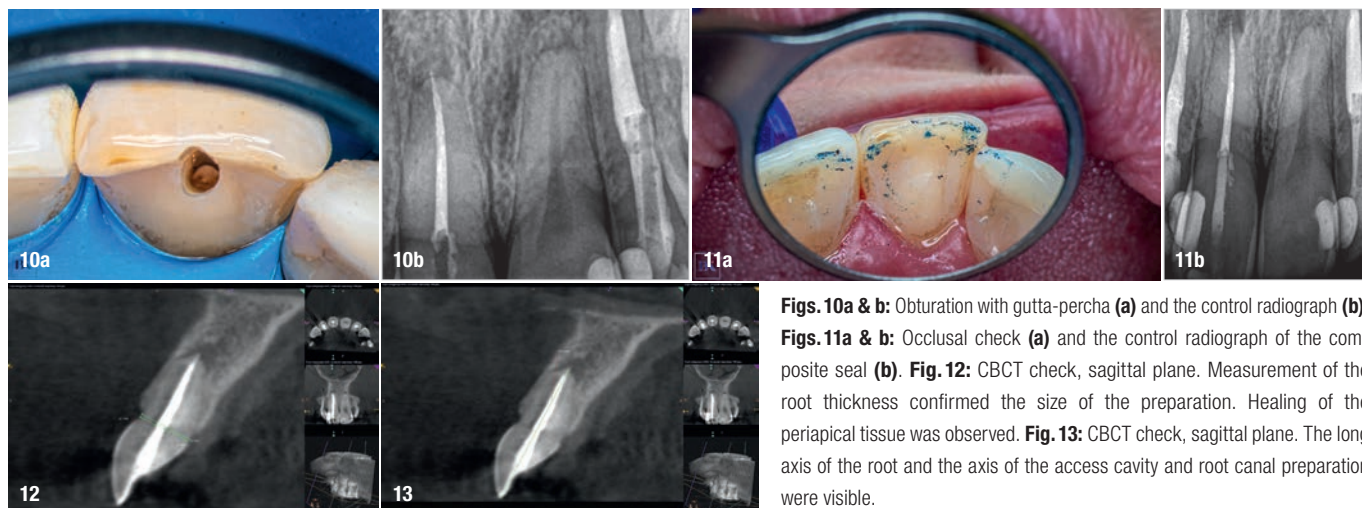
19<sup>th</sup> **ESCD** ANNUAL MEETING  
13 - 15 OCTOBER 2022, ROME

# DIGITAL TRENDS IN **ESTHETIC DENTISTRY**

DR. GIACOMO ARMANI, ITALY  
PROF. DR. CAMILLO D'ARCANGELO, ITALY  
DR. JAVIER TAPIA GUADIX, SPAIN  
DR. RONALDO HIRATA, USA  
PROF. DR. IVO KREJCI, SWITZERLAND  
DR. VINIO MALAGNINO, ITALY  
DR. MARCO MARTIGNONI, ITALY  
PROF. BART VAN MEERBEEK, BELGIUM  
DR. ROBERTO PISTILI, ITALY  
PROF. DR. MASSIMO SIMION, ITALY  
DR. TIZIANO TESTORI, ITALY







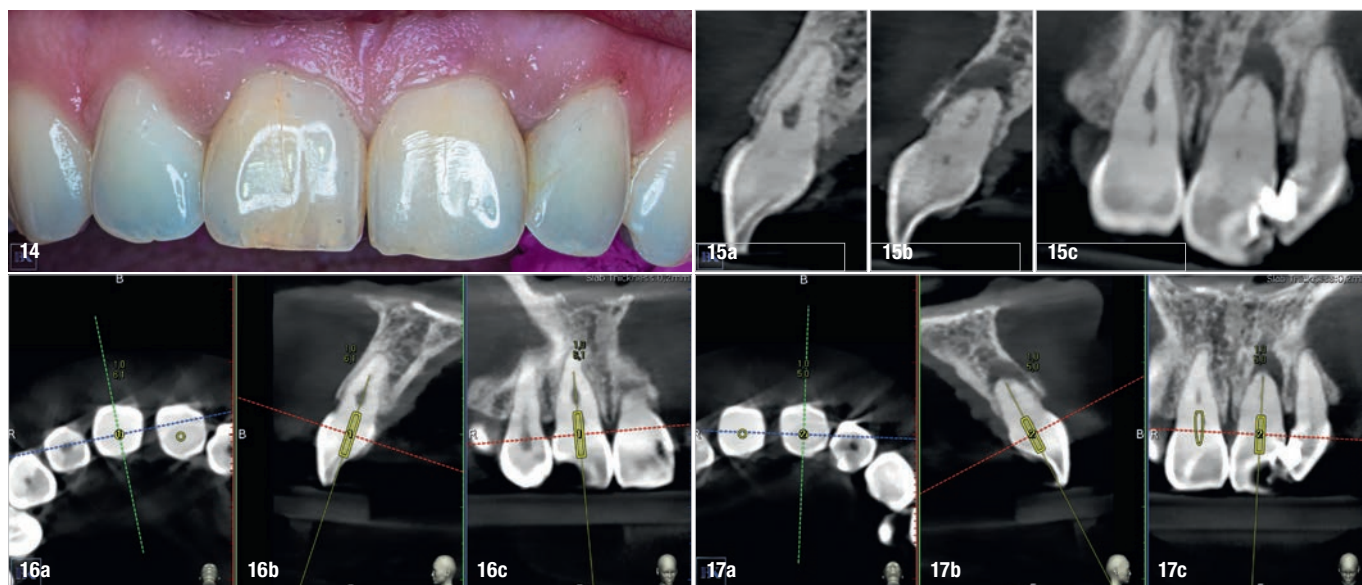
**Figs. 10a & b:** Obturation with gutta-percha (**a**) and the control radiograph (**b**). **Figs. 11a & b:** Occlusal check (**a**) and the control radiograph of the composite seal (**b**). **Fig. 12:** CBCT check, sagittal plane. Measurement of the root thickness confirmed the size of the preparation. Healing of the periapical tissue was observed. **Fig. 13:** CBCT check, sagittal plane. The long axis of the root and the axis of the access cavity and root canal preparation were visible.

calibration procedures, the patient, tooth and guide were prepared for the access cavity creation. The access cavity was created with the EndoGuide bur (SS White Dental) with the aid of the Navident software. The greatest challenge of the procedure for the clinician is to work simultaneously with the fast-speed handpiece in the tooth and trace the position and angulation of the drill on the computer screen, potentially leading to trouble with coordination in the first procedures (Fig. 5).

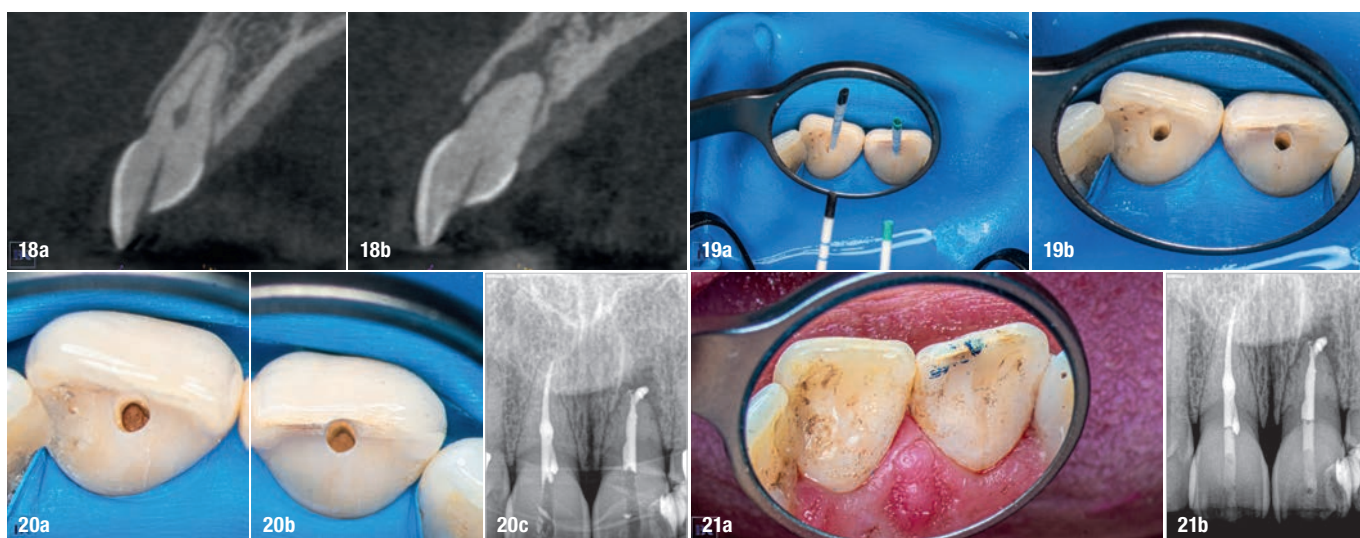
After reaching the depth of drilling on the prepared guide, another CBCT scan was performed to check the accuracy of the access cavity (Fig. 6). According to the image, the angulation of the access cavity had changed slightly to the palatal side and the root canal was reached with the #10 K-file (Kendo, VDW; Fig. 7). Shaping of the root canal was performed with Endostar E3 Azure (Poldent) up to size 30/04. After the shaping protocol, the size of the root canal orifice was checked with the #80 hand plugger,

and it was indicated that the size was larger than #80 but smaller than #100 (Fig. 8). The irrigation protocol was performed with 5.25% sodium hypochlorite and 40.0% citric acid. Both solutions were activated with EDDY sonic tips (VDW), and sodium hypochlorite was additionally activated with elements free (Kerr) for intra-canal heating. The canal was dried with paper points (Fig. 9) and obturated with warm gutta-percha using the continuous wave technique, and a control radiograph was performed (Fig. 10). The access cavity was sealed with a composite material, and another radiograph was performed (Fig. 11).

The recall appointment took place four months after treatment. Healing of the periapical tissue was observed. Despite the limitations of the CBCT imaging related to the voxel size (0.1 mm), the size of the access cavity was found to be  $1.1 \text{ mm} \pm 0.2 \text{ mm}$ , confirming the measurement performed during treatment (Fig. 12). Moreover, we could also



**Fig. 14:** Intra-oral view of the initial situation. Visible discoloration of the right central incisor. **Figs. 15a–c:** CBCT scan, sagittal (**a** & **b**) and coronal planes (**c**). Pulp canal obliteration was visible in both teeth, and a periapical lesion was present around the left incisor. Internal resorption in the right incisor was suspected. **Figs. 16a–c:** Planning of the virtual guide for the right incisor. The axis and depth of the preparation are shown. **Figs. 17a–c:** Planning of the virtual guide for the left incisor. The axis and depth of the preparation are shown.



**Figs. 18a & b:** CBCT check, sagittal plane. The axis of the access cavity was visible for both teeth. **Figs. 19a & b:** Drying the canal before obturation (a). The final shape of the access cavity (b). **Figs. 20a–c:** Obturation with gutta-percha (a & b) and the control radiograph (c). **Figs. 21a & b:** Occlusal check (a) and the control radiograph of the composite seal (b).

confirm that the access cavity and the root canal preparation had the same angulation, parallel to the long axis of the root, and remained in the centre of the root (Fig. 13).

## Case 2

A 30-year-old female patient presented to the dental clinic complaining of constant pain of the left central incisor. Moreover, the patient was unhappy with the aesthetics of both incisors and had a history of trauma (Fig. 14). CBCT examination was performed with the 9000 C 3D (Fig. 15). The CBCT scan revealed a periapical lesion around the left central incisor and PCO for 12mm from the incisal edge. The root of the left incisor was approximately 5mm shorter than the root of the right incisor, which could indicate apical inflammatory root resorption. Moreover, PCO was present in the right central incisor up to 12mm from the incisal edge, and an irregular shadow in the central area of the root was present. This image could indicate internal resorption. There was no lesion in the periapical area. In both teeth, the size of the canals in the periapical area were narrower than the typical size of the canals in the central incisors.

Before the treatment, the CBCT scan was uploaded to the software and the virtual guide was planned (Figs. 16 & 17). All the registration and calibration procedures were performed in the same manner as the previous case.

The access cavity was performed with the EndoGuide bur with the aid of the software. After reaching the depth of drilling on the prepared guide, another CBCT scan was performed to check the accuracy of the access cavity (Fig. 18). The CBCT scan revealed that the angulation of the access cavity was suitable but that the depth was insufficient. The EndoGuide drill and Navident were used one more time to reshape the access cavity. After gaining patency in the canal, the #10 K-file was used to establish the working length. The canal in the right incisor was shaped

with Endostar E3 Azure up to size 40/04, and the canal in the left incisor was shaped up to size 45/04. In both canals, the irrigation protocol was performed with 5.25% sodium hypochlorite and 40.0% citric acid. Both solutions were activated with EDDY sonic tips, and sodium hypochlorite was additionally activated with elements free for intracanal heating. The canals were dried with paper points (Fig. 19) and obturated with warm gutta-percha using the continuous wave technique, and a control radiograph was performed (Fig. 20). Finally, the composite sealing was performed and the occlusal check was done (Fig. 21).

## Conclusion

Although dynamic navigation in endodontics is a very new and uncharted technology, the three teeth with massive PCO in these case reports proved that it offers very promising utility for endodontists. This technology requires further investigation, but it appears that it could help many clinicians to treat teeth with PCO and perform non-surgical retreatment with a better outcome. Moreover, using this technology in preparing constricted access cavities appears to be very promising in terms of the survival of the treated teeth thanks to preserved tooth structure such as peri-cervical dentine. Therefore, digital solutions like Navident should be used more often in endodontics to gather more data and create a new standard for treating teeth with PCO in the future.

## contact



**Dr Bartłomiej Karas**  
MAXDENT  
Ul. Hallera 53/2  
53–325 Wrocław  
Poland

kontakt@bkaras.com



# Root canal therapy of necrotic primary molars—using a single-file reciprocating system

Drs Benjamín Rodríguez & Jenner Argueta, Guatemala

## Introduction

Pulpectomy is a root canal procedure for pulp tissue that is irreversibly infected or necrotic owing to caries or trauma. The root canal pulp tissue is removed, and the canal is commonly shaped with hand or rotary files.<sup>1</sup> This procedure is the standard of care when normal shedding coupled with the eruption of the permanent successor or long-term tooth retention is the priority goal and evidences a good healing outcome.<sup>2</sup>

Like in permanent teeth, it is crucial to achieve adequate disinfection in the root canal system of primary teeth.<sup>3</sup> Premature extraction of necrotic primary molars leads to space loss, an important oral health concern in children because of the consequent improper arch length and altered successor eruption.<sup>3</sup> Therefore, pulpectomy of primary teeth with severe pulp involvement should be considered the treatment of choice when indicated.<sup>3,4</sup>

However, it represents a challenge because of the morphological complexities of the root canal system, presenting multiple roots, uneven apical resorption, fused roots, two mesiobuccal canals and two distobuccal canals in maxillary molars, as well as fins and isthmuses, among others.<sup>2</sup> The disinfection protocol involves biomechanical preparation with hand or rotary instruments and mainly employs 0.5–5.5% sodium hypochlorite (NaClO) and 17% EDTA.<sup>5</sup> Additionally children are more prone to anxiety and stress during dental treatment,<sup>4,5</sup> which may require, in addition to well-established paediatric behaviour management, techniques inherent to the endodontic field that help to make the procedure simpler and less time-consuming.<sup>6,7</sup>

Stainless-steel hand files have been traditionally and, to some degree, successfully used for pulpectomy procedures in primary molars.<sup>7</sup> Despite this, when they are used exclusively, they have multiple drawbacks because of their rigidity, making it difficult to negotiate the canals properly and to avoid procedural errors like ledge formation and perforation.<sup>8</sup> Rotary instrumentation was later introduced and has proved to be very beneficial in the practice of

paediatric endodontics.<sup>8,9</sup> It takes less time, is less skill dependent and reduces the probability of errors that arise with hand files. Consequently, rotary instrumentation facilitates the creation of better conical space for a superior obturation protocol.<sup>10</sup> However, these systems almost always require a long sequence, and may become fatigued, owing to the rotational movement, increasing the probability of file fracture or distortion.<sup>11,12</sup>

Continuous advances in the field of endodontics have resulted in reciprocating instruments that have been applied in root canal therapy of permanent teeth. The clockwise and anticlockwise movement produces less binding of the instrument to the dentine wall, resulting in a decrease in cyclic fatigue and instrument fracture.<sup>13</sup> Reciprocating instruments advocate the use of a single file for the entire root canal preparation. Being less time-consuming, it allows for a longer irrigation protocol. The technique used involves a cycle of instrumentation of in and out pecking motions of 2–3 mm in amplitude with slight apical pressure. Each cycle requires irrigation of the root canal with the irrigating solution and cleaning the file flutes of all dentine remnants, debris and pulp tissue between each cycle.<sup>12,13</sup>

In the research on primary molar pulpectomies, the results of the use of reciprocating instruments have been encouraging so far, demonstrating good cleaning and shaping properties and shortened instrumentation time, thus being beneficial for the preparation of primary teeth.<sup>14–17</sup> However, we found no *in vivo* studies or clinical reports on the use of the R25 file (RECIPROC, VDW) in primary molar pulpectomy. In this article, we present a case series of primary molar pulpectomy using R25 in RECIPROC ALL motion in five primary molars with a diagnosis of pulp necrosis and periapical disease.

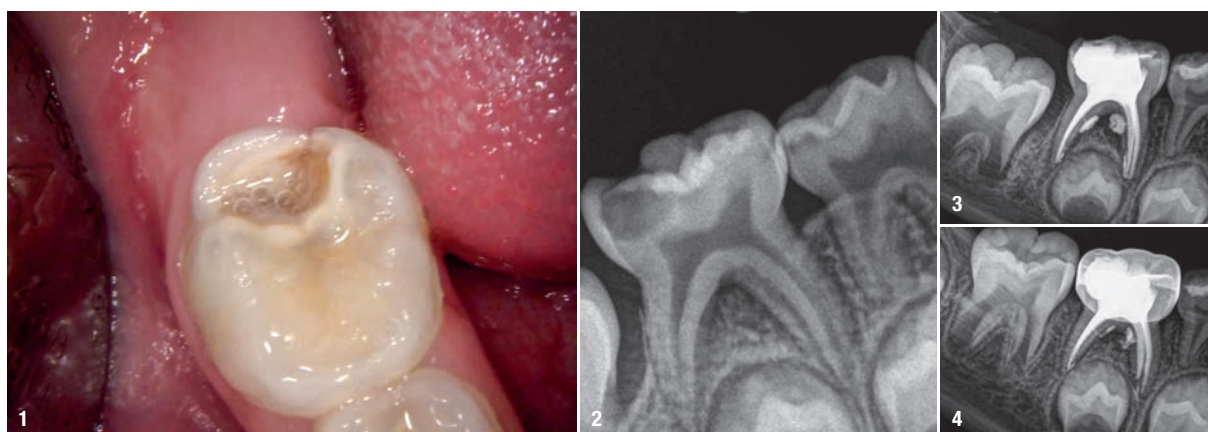
## Pulpectomy procedure

All the patients' parents (or legal guardians) were informed about the procedure protocol and prognosis and signed a written consent. The pulpectomy procedures were performed by the same operator, an endodontist with ten

years of experience in primary molar pulp therapy. All the cases were non-vital teeth with a diagnosis of pulp necrosis. Radiography confirmed bone loss in the apical or furcal area, severe decay compromising the pulp chamber and at least two-thirds remaining of the root surface. All the children were cooperative and did not have systemic disease or special care needs. Follow-up time ranged from 14 months to 36 months.

The treatment protocol was performed in the following steps:

- Local anaesthetic (1 carpule of 2cm<sup>3</sup> of 2% lidocaine hydrochloride with 1:100,000 adrenaline) was slowly injected and negative aspiration confirmed.
- Under complete isolation with a clamp and dental dam, the access cavity was performed with a high-speed #4 round bur under the operating microscope (OM-100, Ecleris), and the access was redefined with a diamond bur.
- The canals were searched with the aid of the DG16 endodontic explorer (Hu-Friedy) and negotiated with 10/.02 K-type files (SybronEndo; Kerr).
- The final irrigation protocol per root was 2cm<sup>3</sup> of alcohol and 1cm<sup>3</sup> of 17% EDTA for 1 minute, followed by 2cm<sup>3</sup> of alcohol, 5cm<sup>3</sup> of 2.5% NaClO and 3cm<sup>3</sup> of saline, and then paper points (Meta Biomed) were inserted to ensure canal dryness.
- A mixture of zinc oxide eugenol (ZOE) in a powder-liquid form (Proquident) was delivered into the canals on a 40/.04 gutta-percha cone (Meta Biomed). Owing to its diameter at the tip, the cone was intended to fall short of the apical working length to avoid over-extrusion of the material.
- An intermediate radiograph was taken to visualise the quality of obturation. If further condensation was required, more ZOE paste of a harder consistency was gently plugged with a sterile cotton pellet.
- Intermediate obturation was performed in the cavity above the ZOE using a glass ionomer luting cement (Ketac Cem Easymix, 3M ESPE).
- At a second appointment, 15 days later, upon confirming the absence of signs or symptoms of disease, a stainless-steel crown was adapted and cemented with glass ionomer in a powder-liquid form (Ketac Cem Easymix).



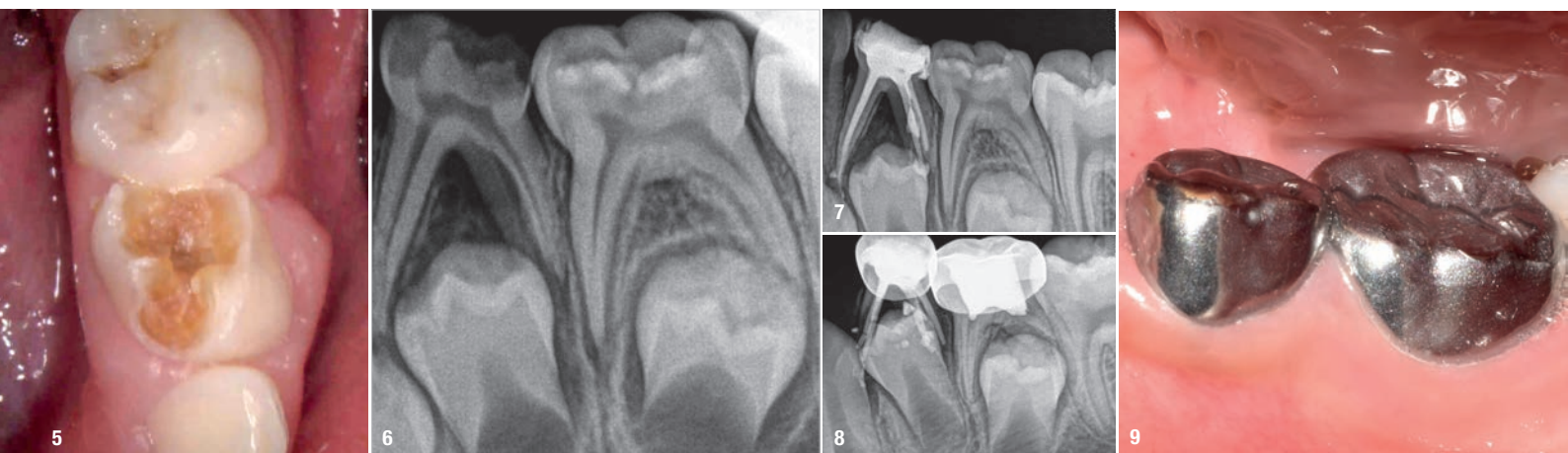**Case 1—Fig. 1:** Initial situation. **Fig. 2:** Deep cavity and bone loss in the furcal area. **Fig. 3:** Three canals, lateral canal filling. **Fig. 4:** Fifteen-month control showing bone deposition in the furcal area.

- The canal length was determined with an electronic apex locator (Root Zx II, Morita) and confirmed with a peri-apical radiograph. From the measure obtained, 1 mm was subtracted to calculate the working length.
- The irrigation was realised with 2.5% NaClO delivered passively 2mm short of the working length in 27 gauge, 3cm<sup>3</sup> Luer lock endodontic syringes (PlastCare).
- The root canal preparation was performed with a 21 mm long R25 file according to the manufacturer's recommendations in reciprocating motion (VDW.SILVER RECIPROC, VDW) in the RECIPROC ALL mode, without apical pressure, using in and out movements of 2–3mm in amplitude, allowing the instrument to advance in the canal in a safe way until it reached the working length.
- No lateral pressure against or brushing of the canal walls was done, in order to reduce the risk of weakening the thin tooth structure.

### Case 1 (Figs. 1–4)

This female patient was 4 years and 7 months old and presented with pain that had lasted for several days affecting the mandibular right second primary molar. On clinical examination, a buccal gingival swelling and facial initial oedema were noted, and the tooth was found to have deep occlusal decay. Pulp necrosis and a symptomatic apical abscess were diagnosed. The patient was prescribed medication to control acute infection and rescheduled after the antibiotic treatment. At the second appointment, no pain was reported and the buccal abscess had partially receded. A decision was made to perform pulpectomy and restoration. Over-extrusion of the obturation material was observed. The 15-month re-evaluation confirmed no clinical or radiological signs of disease, and bone deposition was evident in the furcal area.





**Case 2—Fig. 5:** Initial condition. Severe decay and buccal abscess. **Fig. 6:** Four long root canals were detected. **Fig. 7:** Obturation and temporary restoration. **Fig. 8:** Fourteen-month control showing the successor eruption process advancing normally. **Fig. 9:** Clinical aspect at final evaluation showing healthy gingival tissue.

### Case 2 (Figs. 5–9)

This male patient was 6 years and 7 months old and presented with severe tooth decay on the mandibular left first primary molar without any symptoms of pain. He experienced slight discomfort to percussion and palpation of the buccal gingiva. A buccal abscess and no mobility were observed. The radiograph showed a large area of interradicular bone loss. The tooth was diagnosed with pulp necrosis and asymptomatic apical abscess. Pulpectomy was performed, and at a second appointment, a stainless-steel crown was placed upon confirming absence of signs or symptoms of disease. At the 14-month recall, no clinical pathology was detected and a normal eruptive process of the permanent premolars was observed in spite of the extrusion of the obturation material.

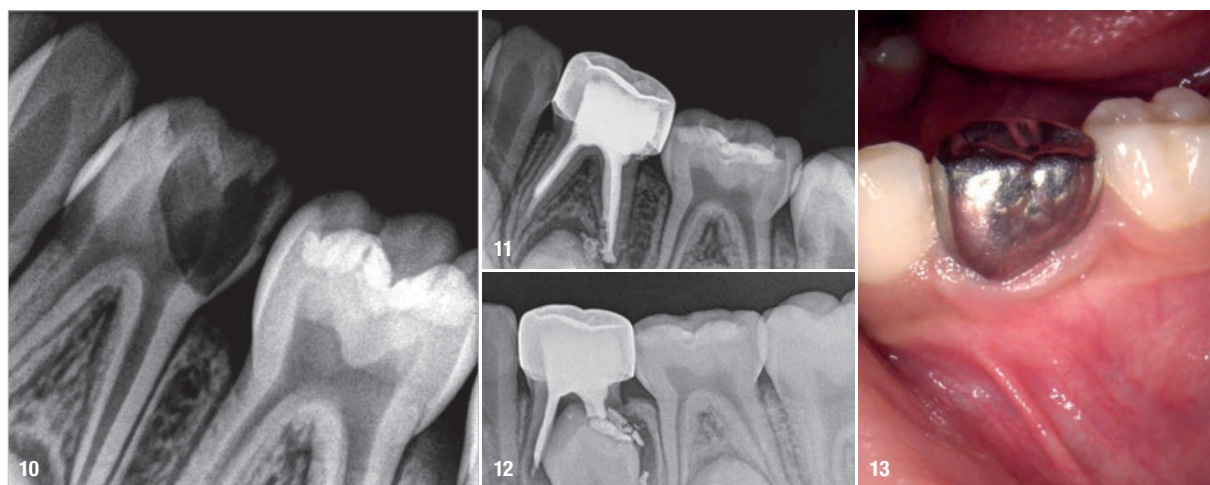
### Case 3 (Figs. 10–13)

This male patient was 7 years old and presented with mild pain that had lasted for several days. An extensive and deep cavity

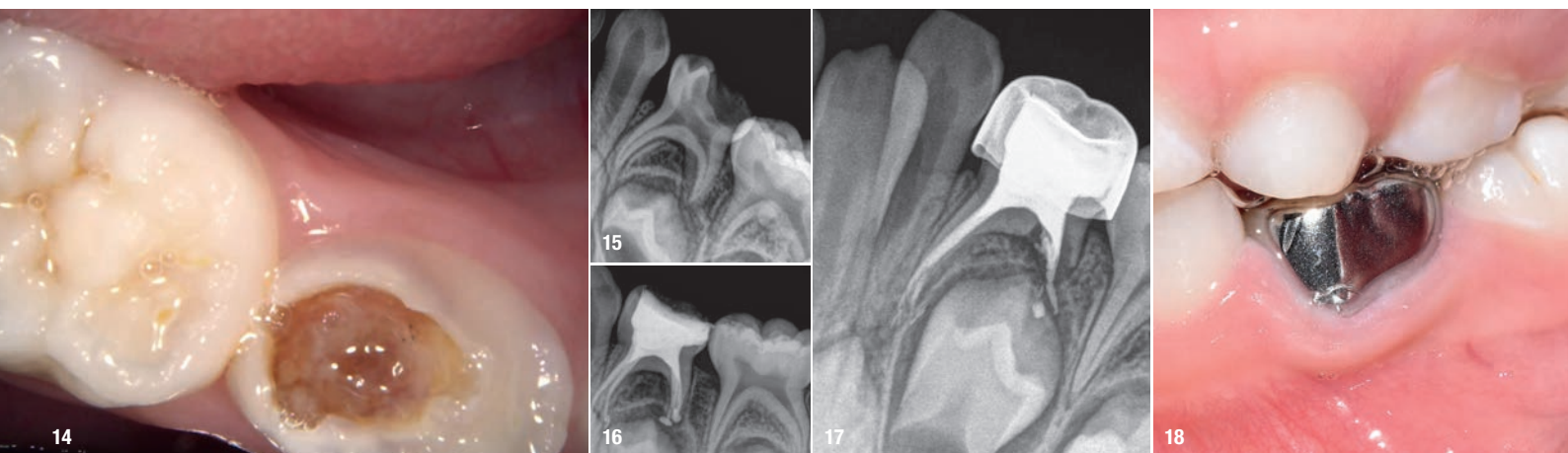
in the mandibular left first primary molar was observed. There was no swelling of the gingiva, but the tooth was painful on percussion. The radiograph showed the severity of the decay but no consistent changes to the surrounding bone. Pulpectomy was the treatment of choice. The diagnosis of pulp necrosis was confirmed once the access cavity had been performed, and three canals were located and fully negotiated. At a second appointment, 15 days later, the tooth was totally asymptomatic and the decision was made to restore with a stainless-steel crown. The 36-month control showed the tooth to be in normal function and completely healthy.

### Case 4 (Figs. 14–18)

This male patient was 4 years and 6 months old and presented with constant and spontaneous pain of the mandibular left first primary molar that had lasted for several days but no facial oedema or buccal gingival swelling. Deep decay was observed but no mobility or deep probing depths. On the radiograph, the carious lesion could be seen to be



**Case 3—Fig. 10:** Initial radiograph. **Fig. 11:** Obturation and final restoration. **Fig. 12:** Control at 36 months showing the normal eruption process despite the slow resorption of the zinc oxide eugenol. **Fig. 13:** Clinical aspect at final evaluation showing healthy gingival tissue.

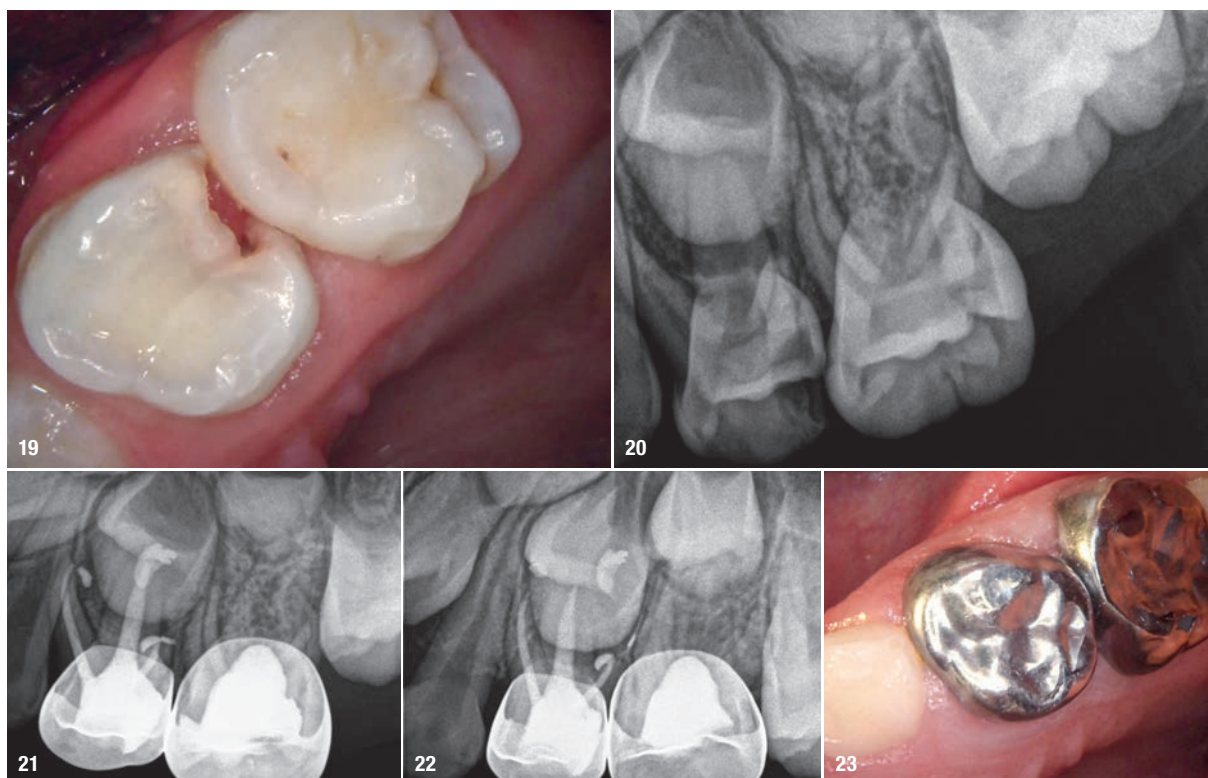


**Case 4—Fig. 14:** Severe decay. **Fig. 15:** Initial radiograph showing compromised pulp chamber. **Fig. 16:** Obturation of four root canals. **Fig. 17:** Thirty-month control. **Fig. 18:** Clinical aspect at final evaluation showing healthy gingival tissue.

compromising the pulp chamber and initial bone damage was observed in the furcal area. Pulpectomy was the treatment of choice. In the removal of the carious lesion, the pulp was exposed and no bleeding was observed. Pulp necrosis was diagnosed. Two mesial and two distal canals were located, and the tooth was obturated. At a second appointment, the tooth was asymptomatic and was restored with a stainless-steel crown. At the 30-month control, the tooth presented no symptoms and a normal eruptive process was observed on the radiograph.

### Case 5 (Figs. 19–23)

This male patient was 5 years and 8 months old and presented with distal deep interproximal caries on a maxillary left first primary molar and an associated buccal sinus tract. The patient was asymptomatic and without a history of pain. Pulp necrosis with suppurative periapical periodontitis was diagnosed. Three canals were located and prepared for obturation. Apical over-extrusion with the ZOE was observed. Fifteen days later, the patient was asymptomatic and the sinus



**Case 5—Fig. 19:** Initial condition. Interproximal decay. **Fig. 20:** Initial radiograph showing apical bone loss. **Fig. 21:** Obturation of three root canals and final restoration. **Fig. 22:** Thirty-month control showing bone healing around the mesial root and distal root tissue. **Fig. 23:** Clinical aspect at final evaluation showing healthy gingival tissue.



tract had resolved, so the decision was made to restore the tooth with a stainless-steel crown. Follow-up after 30 months showed periapical healing of mesial apical area of previous radiolucency and no signs or symptoms of disease or pain.

## Discussion

Dental caries is a pathology of wide prevalence in the world, and it affects the dentition in the early stages of life, being most common in susceptible populations because of a lack of dental education and limited access to quality healthcare services.<sup>18</sup> It is well known that it is essential to avoid space loss during childhood in order to preserve the natural dentition. Loss of proper space can lead to malposition of permanent teeth and compromises nutrition, speech ability and self-confidence, among others.<sup>19</sup> Primary molar pulpectomy is the treatment of choice to preserve primary natural dentition in teeth affected at the pulp-dentine complex and periodontally diseased as a result of bacterial invasion of the root canal system.<sup>20</sup>

Anxiety and stress regarding dental treatment in general are common, but must especially be taken into consideration when it comes to performing paediatric endodontic treatment.<sup>21</sup> The search for and implementation of efficient endodontic techniques requires proper understanding of the root canal system anatomy, root canal instrumentation, disinfection and obturation techniques, and the importance of coronal restoration.<sup>20,22</sup> When it comes to root canal instrumentation, hand file techniques have been widely used in endodontics, but they are time-consuming, uncomfortable at some point and susceptible to procedural errors, especially if performed by clinicians with limited clinical experience.<sup>22,23</sup> Mechanically driven instrumentation came to change the way we shape canals, providing a faster way to enlarge the root canal system in a convenient geometry to allow the appropriate movement of the irrigating solutions inside the root canal system.<sup>23,24</sup> Instrument design, nickel–titanium alloys and the type of movement are factors to take into consideration, because they will directly influence the instrument performance.

In paediatric dentistry, chair time is a factor to consider: the shorter, the better for the patient to manage anxiety and feel comfortable. Single-file reciprocating instrument systems can be beneficial for paediatric endodontic treatment because they properly enlarge the geometry of the root canals, facilitate good shaping to enable proper distribution of irrigating solutions all along the working length and are less time-consuming than rotary and manual instrumentation sequences.<sup>23,25,26</sup> However, to the best of our knowledge, there is a lack of *in vivo* research on the use of reciprocating instruments in primary molar pulpectomy.

Moghaddam et al. in their experimental study compared the cleaning efficacy and instrumentation time of RECIPROC and Mtwo (VDW) in primary molars.<sup>27</sup> They concluded that using systems such as RECIPROC for pulpectomy is beneficial.

Ramazani et al. in their *in vitro* study compared two rotary systems and RECIPROC in mesiobuccal canals of primary molars.<sup>28</sup> They confirmed the RECIPROC system's fast and good cleaning and shaping ability. These were the first studies to advocate the use of the RECIPROC system in the primary dentition.

Moraes et al. conducted an *in vitro* study employing a 3D-printed prototype of a maxillary primary central incisor.<sup>14</sup> They concluded that the R40 file of the RECIPROC system was effective for instrumenting their 3D-printed model.

Tyagi et al. in their *in vivo* study compared the use of a rotary system and the RECIPROC system for primary molar pulpectomy and evaluated the possible influence of the file system on child behaviour, among other factors.<sup>29</sup> Their results regarding clinical performance were in accordance with those of previous research. Nonetheless, they stated that the choice of file system did not significantly alter child behaviour.

Dalzell et al. conducted a micro-CT study in which they evaluated the instrumentation efficacy of manual, Mtwo and RECIPROC blue files (VDW) in non-fused and fused primary molar roots and found significant differences in cleaning and shaping effectiveness in both fused and non-fused teeth.<sup>30</sup> Additionally, they found more procedural errors when the reciprocating instruments were used. This last finding is contrary to those of previous research and our clinical experience so far. Although we have not seen the clinical performance of the RECIPROC blue system, it shares the geometrical design and motion of RECIPROC.

Barasul et al. compared the shaping ability of hand, rotary and reciprocating files in primary teeth in a micro-CT *in vitro* study.<sup>25</sup> Their results showed more canal transportation in the middle third of the root canal with the R25 file. They also found a shorter instrumentation time with the RECIPROC system compared with manual instrumentation.

To the best of our knowledge, ours is the first clinical report of the use of the R25 file in an *in vivo* scenario for primary molar pulpectomy. The long period of follow-up showed good results overall. These five cases were restored with complete stainless-steel crowns, and the time of their cementation was appropriate, avoiding recontamination of the root canal system. Our clinical experience over the years exceeds the cases reported here; however, these cases were presented because of their longer follow-up and proper stainless-steel restoration. The therapeutic success of our unreported cases follows the trend shown in this case series. Stainless-steel crowns are the preferred restoration for children at high risk of caries and teeth that have undergone pulp therapy. This may have contributed to the long-term success of treatment.

The use of the operating microscope, coupled with the experience of the operator in microscopic endodontics, may also have contributed to these results. The dental microscope is underestimated and under-used in paediatric dentistry; however, its

## about



**Dr Benjamín Rodríguez** earned his degree in dentistry from the Universidad Francisco Marroquín and his MSc in endodontics from the Universidad de San Carlos de Guatemala, both in Guatemala City in Guatemala. In 2019, after six years of endodontic clinical practice, he earned a postgraduate degree

in oral and maxillofacial radiology from UIC Barcelona in Spain.



**Dr Jenner Argueta** earned his degree in dentistry and master's degree in endodontics from the Universidad de San Carlos de Guatemala in Guatemala City in Guatemala. He is a certified researcher at the Guatemalan national council for science and technology and teaches endodontics at the Universidad Mariano Gálvez

de Guatemala in Guatemala City. He obtained the Certificate of Proficiency in Endodontics from UB School of Dental Medicine at the University of Buffalo in Buffalo, New York, in United States. Dr Argueta also runs a clinical practice focused on micro-endodontics and micro-restorative dentistry. He was president of the Academia de Endodoncia de Guatemala (endodontic academy of Guatemala) from 2016 to 2020. Dr Argueta can be contacted at [jennerargueta@gmail.com](mailto:jennerargueta@gmail.com).

advantages in locating canals in primary molars are clear, and its use is likely to become the standard of practice in dentistry. The improved ergonomics also allows longer working times without repetitive muscle strain and prevents postural issues." More research is needed with longer follow-up and more cases and future investigations should focus on randomised clinical trials. Newer reciprocating instruments like RECIPROC blue could possess designs and metallurgical characteristics that are beneficial for use in primary molar pulpectomy and should therefore be investigated.

*Editorial note: A list of references is available from the publisher.*

AD

# REGISTER FOR FREE

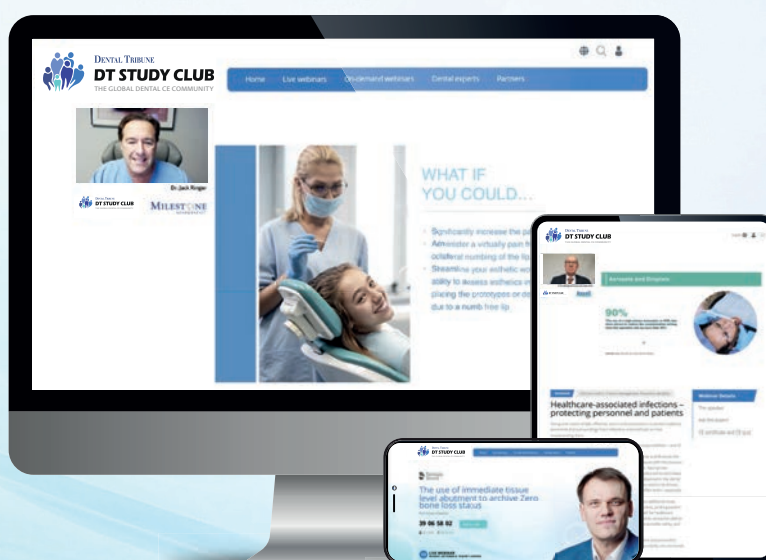DT Study Club – e-learning community



DENTAL TRIBUNE

# DT STUDY CLUB

THE GLOBAL DENTAL CE COMMUNITY



# Dentistry's largest online education community

webinars / live operations / online CE events / CE credits



[www.dtstudyclub.com](http://www.dtstudyclub.com)



@DTStudyClub

ADA CERP® Continuing Education Recognition Program



Tribune Group

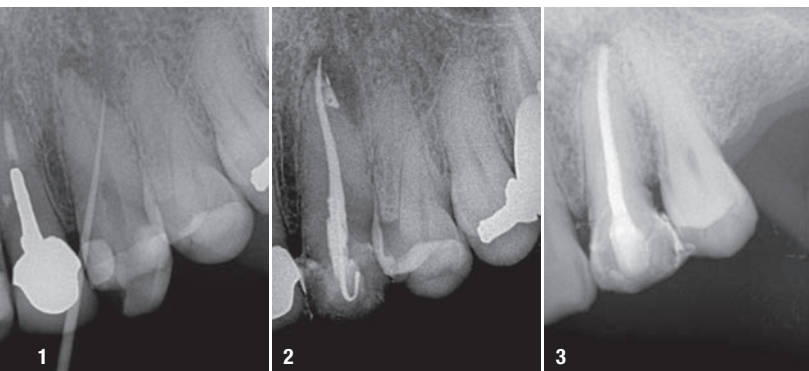
dti Dental Tribune International

Tribune Group is an ADA CERP Recognized Provider. ADA CERP is a service of the American Dental Association to assist dental professionals in identifying quality providers of continuing dental education. ADA CERP does not approve or endorse individual courses or instructors, nor does it imply acceptance of credit hours by boards of dentistry. This continuing education activity has been planned and implemented in accordance with the standards of the ADA Continuing Education Recognition Program (ADA CERP) through joint efforts between Tribune Group and Dental Tribune Int. GmbH.



# High-end technology for simplicity

Adj Prof. Philippe Sleiman, Lebanon



Since nickel-titanium (NiTi) files were introduced into root canal therapy, engineers have been seeking the perfect design and combination for optimal root canal therapy. Heat treatment and twisting of NiTi was a major breakthrough in this field. It opened up the era of heat treatment for rotary files, and now almost all files in the market are heat-treated, creating great flexibility, but putting aside cutting efficiency, cutting being the major task for rotary files in shaping root canals.

The Traverse and now ZenFlex file systems (both Kerr) are produced using a novel heat treatment that combines cutting efficiency and flexibility in one file and in the necessary places. This new technology in heat treatment adds value to our daily work, as ultimately what matters is the treatment that we offer to our patients. Safety and cutting efficiency are apparent when using these files, allowing me to

use a rather simplified approach for treating the complex root canal anatomy. In this article, I will demonstrate this approach with reference to several cases.

The orifice opening is done with the 25/08 Traverse file, which has a maximum flute diameter of 1 mm. This is a file that I use in almost all of my cases. In straight canals, it goes as deep as it can and, in curved canals, is limited to working above the curve.

In straight canals, ZenFlex offers a wide range of sizes, from 20 to 55, in both .04 taper and .06 taper. After using the ZenFlex for some time, the dentist can evaluate the size that he or she likes to use according to his or her experience and preferences and can use one ZenFlex file to finish the shaping.

In this first example, the patient was referred for treatment of a sinus tract of the anterior maxilla (Fig. 1). A gutta-percha cone was placed inside the fistula, showing the way to the infection site. This was a straightforward case, prepared using the 25/08 Traverse file in the upper part of the root canal, followed by a 10 K-File (Kerr) to determine the working length and then a 40/06 Traverse file taken to working length. Naturally, treatment involved complete chemical preparation and 3D sealing of the root canal space (Fig. 2).

The next example was also a straightforward case. This was a maxillary lateral incisor with a necrotic pulp and a slightly resorbed apex. A 55/06 ZenFlex file was used in a single-file technique to treat this canal (Fig. 3).

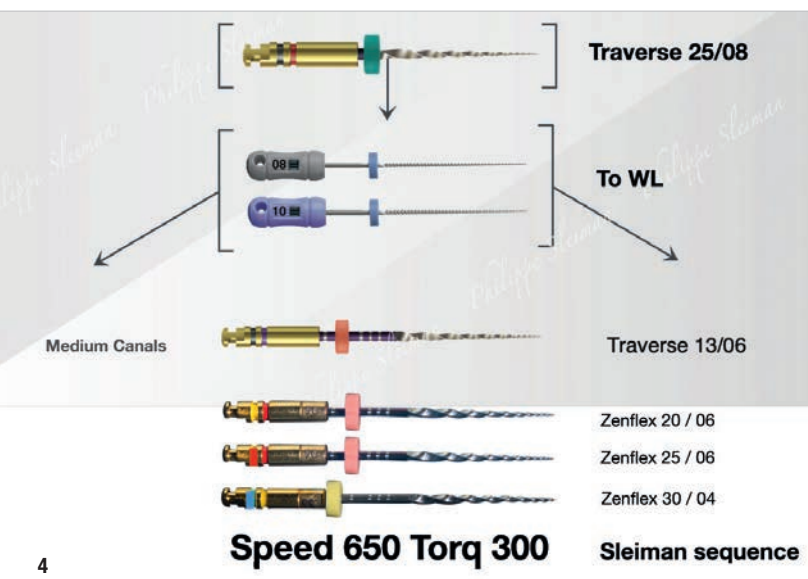
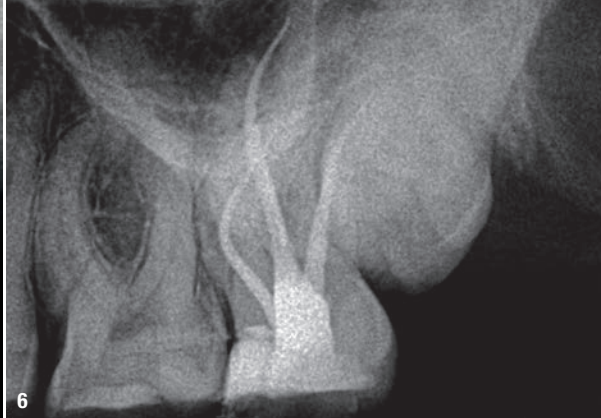
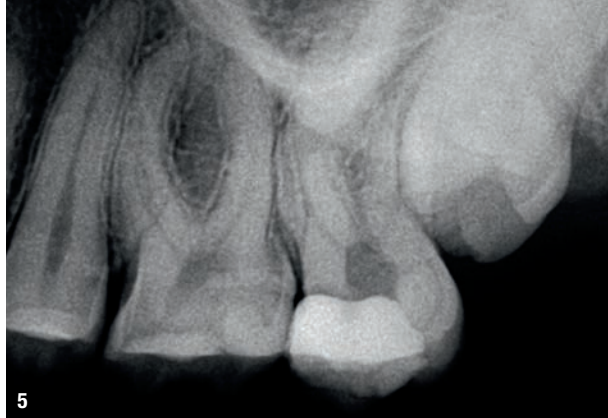

Fig. 4: Technical card for small to medium canals.

In molars and narrow canals, a simple sequence is required in order to perform shaping. It can start with the 25/08 Traverse file, taken to just above the curve, especially in mesial canals. Using a K-File, the dentist can determine the working length using an apex locator and use this length for preparation with rotary files. The K-File is also used to achieve patency. The second rotary file is the 13/06 Traverse file, taken to working length, followed by the 20/06 and 25/06 ZenFlex files, also taken to working length. If the dentist is following an apical enlargement regime, a 30/04 ZenFlex file can be used for the apical area (Fig. 4).

Maxillary second molars are in my opinion one of the most challenging teeth to treat because of their position and unpredictable anatomy. In this example case, the patient was referred for irreversible pulpitis (Fig. 5). Looking at the preoperative radiograph, we can see the curvature of especially the mesial and palatal root canals. The sequence used was as described before, starting with the 25/08 Traverse





orifice opener as deep as it goes and just above the curve, followed by a 8 K-File for working length determination and the 13/06 Traverse file used to working length in all canals. During the use of the 13/06 Traverse file, I did not feel much resistance, so I decided to go ahead with the .06 taper sequence. The next file was the 20/06 ZenFlex, followed by the 25/06 ZenFlex file. Personally, I believe in apical enlargement, and for that reason, I used the 30/04 ZenFlex file as the final enlargement file in this case. I used a medium cone as the master cone and achieved 3D sealing of the system (Fig. 6). Of course, I performed complete chemical preparation, according to my sequence, during the procedure.

In very narrow canals, the .06 taper ZenFlex file will be replaced by the .04 taper one, in order to reduce taper lock, which occurs when a large file is trapped inside a single or a double canal curve. This can create a great deal of torsional stress and bending stress on the same spot, leading to severe damage of the file and even to file separation. The sequence is use of the 25/08 Traverse file in the straight part of the canal, followed by 8 and 10 K-Files, taken to working length. The 13/06 Traverse file opens the way for the 20/04 ZenFlex file, which is followed by the 25/04 ZenFlex file and additionally the 30/04 ZenFlex file for apical enlargement (Fig. 7). A medium or fine-medium cone can be adapted as the master cone.

In this example case, the patient was referred by his treating dentist, who had penetrated deep into the roots in trying to find the canals and was not successful, but fortunately no perforation had occurred (Fig. 8). Under the microscope and using ultrasonic tips, the canals were made accessible. On the radiograph, we can see that the canals, especially the mesial ones, are narrow and have small curves, particularly apically. The real challenge in this case was maintaining the original shape of the canal. For those reasons, the sequence with the .04 taper was chosen. Treatment was initiated with the 25/08 Traverse orifice opener, followed by a 8 K-File for working length determination. The 13/06 Traverse file was used all the way to the end of the working length, followed by the 20/04

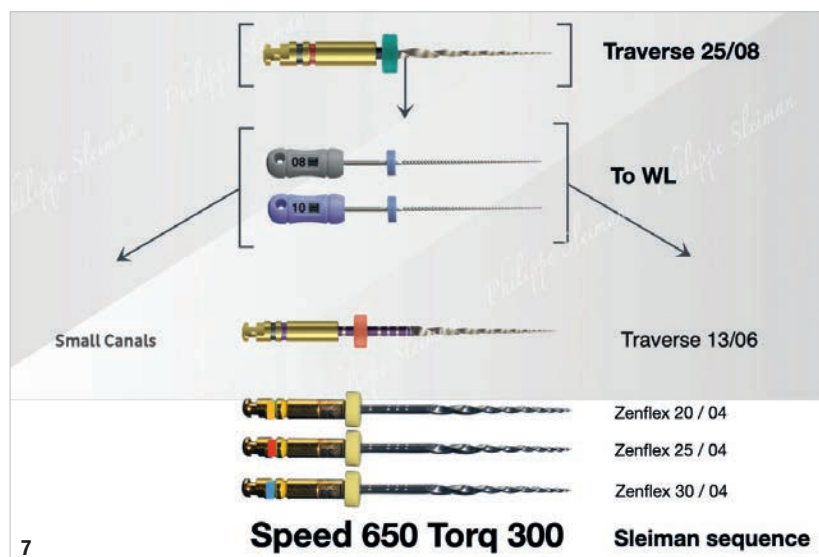


Fig. 7: Technical card for narrow canals.

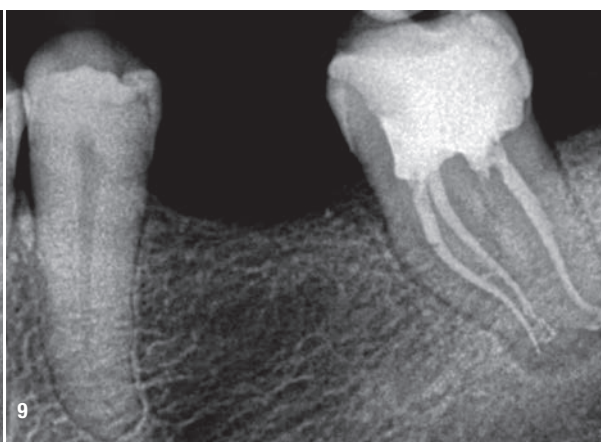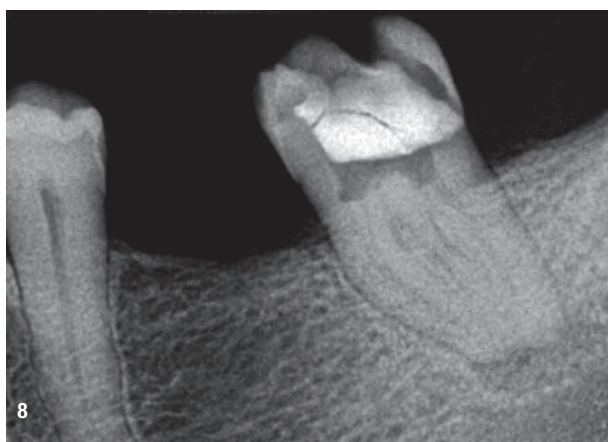and 25/04 ZenFlex files, both taken to working length. For apical enlargement, the 30/04 ZenFlex file was used.

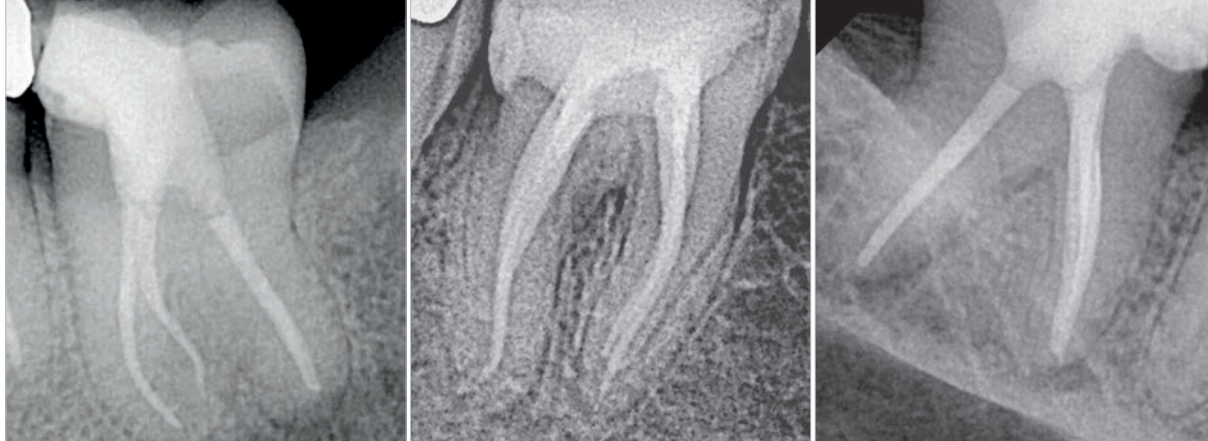A medium cone was used as the master cone in the distal root, and fine-medium cones were used in the mesial root. A full sequence of irrigation was used during the treatment, and the system, which included a deep isthmus between the mesial roots, was filled in multiple levels from the middle to the apex, achieving beautiful 3D obturation (Fig. 9).

## contact



**Adj. Prof. Philippe Sleiman** is an assistant professor at the Faculty of Dental Medicine of the Lebanese University in Beirut in Lebanon and Adj. Prof. at the UNC Adams School of Dentistry at the University of North Carolina in Chapel Hill, North Carolina, in United States. He can be contacted at [profsleiman@gmail.com](mailto:profsleiman@gmail.com).





# The golden era of root canal shaping

Dr Ahmed Shawky, Egypt

**After access preparation** and location of anatomy, the next challenge facing the endodontic clinician is to select the proper file alloy and sequence for the shaping procedure in order to be able to shape the anatomy safely and predictably and without any procedural errors. This article will show the advantages of the MG3 instruments (Shenzhen Perfect Medical Instruments) and how we can customise the sequence of these files according to the anatomy encountered and case difficulty for predictable root canal shaping with a high safety margin.

## Files

First, I will go through the components of the basic assortment of the MG3 Gold file system (Fig. 1). The main advantage of this file system is the presence of different designs and cross sections in the same instrument kit, a smart thing for dealing with different anatomies.

The MG3 Gold files are machined with a variable pitch and helix (Fig. 2), allowing efficient coronal evacuation of debris and preventing a screw-in tendency. This also reduces the torsional load on the instrument that would otherwise occur because of debris accumulation or excessive friction with the root canal walls.

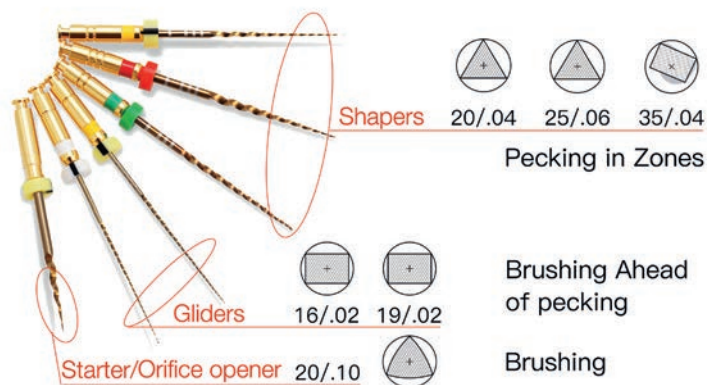
## Starter file (orifice modifier, 20/.10)

This file has a short working segment (9mm) and 19mm length. This improves accessibility in restricted areas (Fig. 3). It is used for mechanical pre-flaring or orifice modification for elimination of coronal dentine resistance. It has a convex triangular cross section, which increases the blade strength, giving the instrument a high cutting efficiency. With this cross section, the instrument is subjected to excessive torsional load; therefore, this instrument must be used in brushing motion towards the outer walls and not pecking motion.

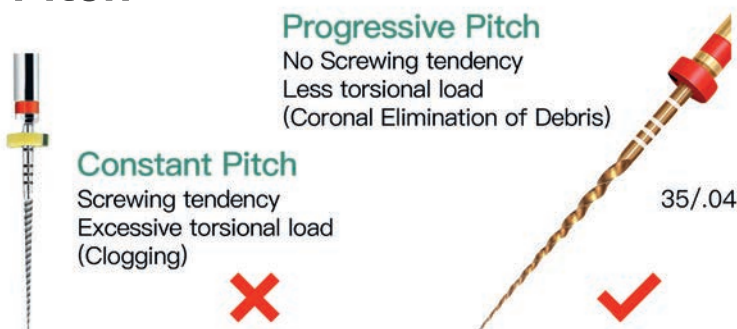
## Gliders (16/.02 and 19/.02)

Another advantage of this system is that it has two glide path files (Fig. 4). They can be used sequentially, depending on case difficulty. Sometimes, only one is used. The rectangular cross section provides four blades for better centring ability, avoiding transportation, and for high cutting efficiency for reproducible glide path preparation.

The small size and taper of these files make them extremely flexible for negotiating mechanically difficult curvatures. Owing to the small size of the gliders, it is recommended to use them with brushing motion ahead of pecking motion to avoid torsional failure.



## Pitch



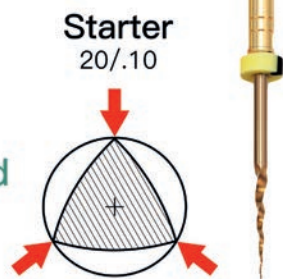


## Cross-Section Designs

Orifice Modifier/opener  
High Cutting efficiency

High Blade Strength  
Excessive torsional load

Should be used in brushing motion

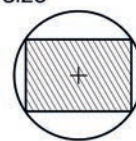


3

## Cross-Section Designs

High Cutting efficiency  
Enhanced flexibility due to small size  
Centering ability

Glide Path Preparation  
Brushing ahead of pecking



16/.02 19/.02

4

“The MG3 Gold with low shape memory and high cutting efficiency allows (...) to manage different cases with an excellent margin of safety and predictability.”

### Shaping files 20/.04 and 25/.06

The cross section of these shaping files is triangular (Fig. 5). This design provides sharp blades for enhanced cutting efficiency and reduces the metal core of the instrument, as the size is increased to maintain flexibility.

The heat treatment imparts a wear-resistant surface with superior cutting behaviour and enhances cyclic fatigue resistance.

The 25/.04 file can be used in body shaping and can be used as a finishing file in cases with anatomical limitations, such as severely curved canals. The 25/.06 file can be used for pressureless pre-flaring and as a shaping or finishing file.

### Shaping file 35/.04

The cross section of this shaping file is off-centre rectangular (Fig. 6). This design provides sharp blades for enhanced cutting efficiency and reduces the contact points of the instrument with the root canal walls.

This reduces the torsional load on this larger size and provides better clearance of debris.

The off-centre design also makes the instrument move in swaggering motion for better canal tracing and for avoiding transportation. The 35/.04 file is an optional file for increasing the preparation size in large root canals. It is used in zone pecking motion.

### Additional information

Non-assorted refills of all sizes are available for the clinician to customise his or her treatment sequence up to ISO tip size 50. All files are available in lengths of 21, 25 and 31 mm (except the starter file, being of 19 mm in length).

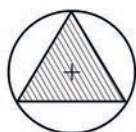The recommended operation speed is 300–350 rpm, and the recommended torque is 2 Ncm for the glide path and shaping files and 3 Ncm for the starter file. Markings indicate taper: one marking for 2%, two for 4% and three for 6%.

Precisely calibrated working length markings are engraved on each instrument shank at 18, 19, 20 and 22 mm for easy reproduction of the recorded working lengths in each canal, especially in multi-rooted teeth of different lengths.

## Cross-Section Designs

High Cutting efficiency  
Enhanced flexibility due to small size  
Centering ability

Middle/Apical Shaping  
Zone Pecking



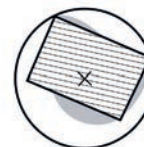
20/.04 25/.06

5

## Cross-Section Designs

Minimal Contact with Dentine  
Less Torsional Load  
Canal Tracing “Swaggering”

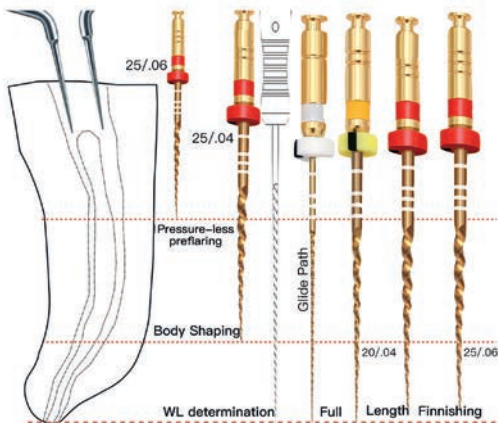
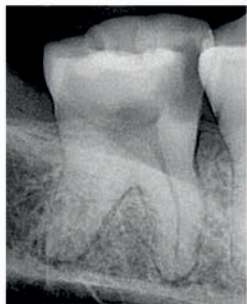Apical Finishing  
Zone Pecking



Off-Center design

35/.04

6



7

## How to use the MG3 Gold instruments

### Case 1 (Fig. 7)

The patient presented to the clinic and was diagnosed with symptomatic irreversible pulpitis and apical periodontitis of a mandibular third molar. After access prepa-

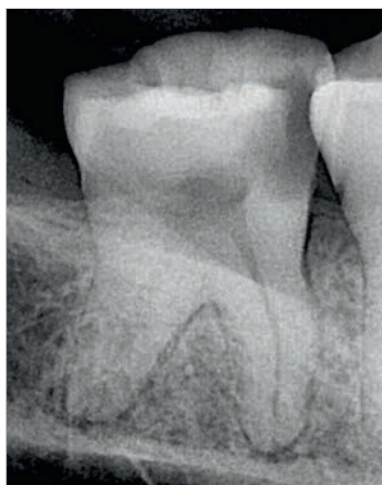ration, only one large mesial orifice was identified. Ultrasonic modification revealed the presence of two mesial canals originating from a single mesial orifice (sub-pulpal bifurcation).

Mechanical pre-flaring with the 25/06 MG3 Gold file, followed by mechanical body shaping with the 25/04 file, created a smooth glide path down the two separate mesial canals despite coronal restriction. Following the reproducible glide path, shaping with the 20/04, 25/04 and 25/06 files was not a difficult task.

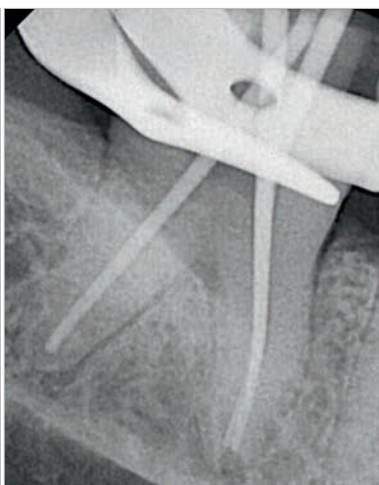
### Case 2 (Figs. 8 & 9)

A patient with a mandibular third molar diagnosed with irreversible pulpitis and symptomatic apical periodontitis was referred to my practice. Under high magnification, the canal entrances were negotiated using medium-

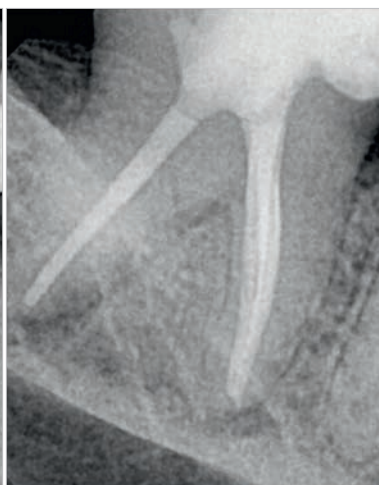
## Single Visit Treatment using MG3 GOLD Files



Pre-treatment



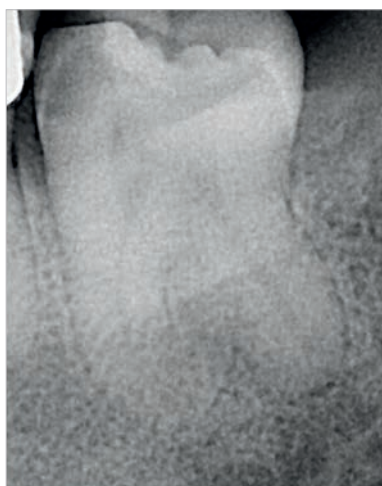Cone Fit



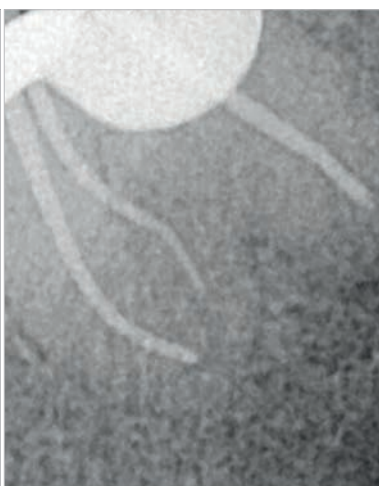Post-obturation

8

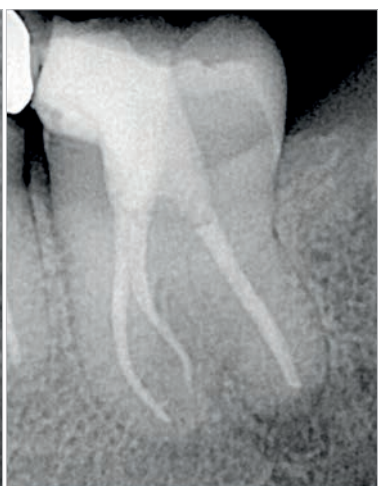## Single Visit Treatment using MG3 GOLD Files



Pre-treatment



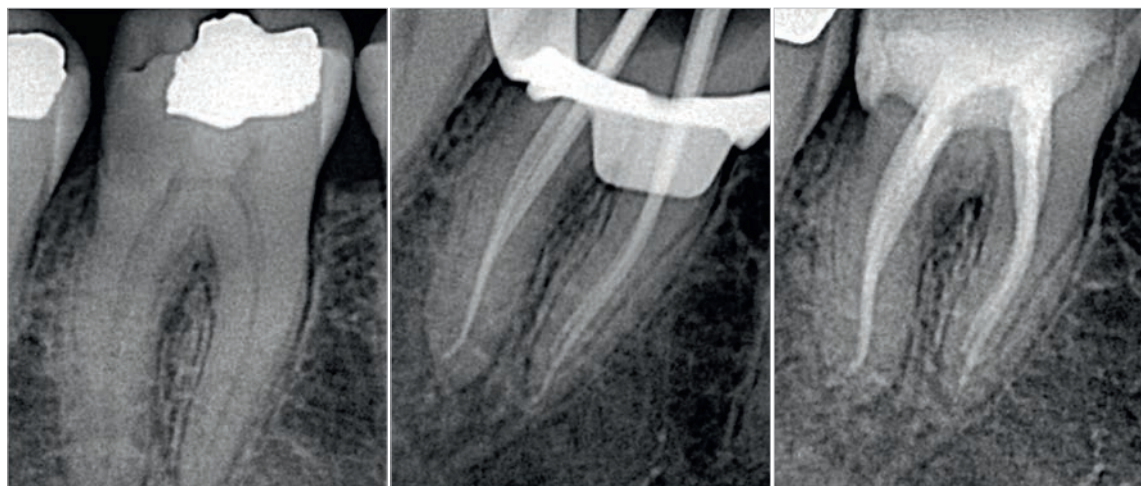
Cone Fit



Post-obturation

9



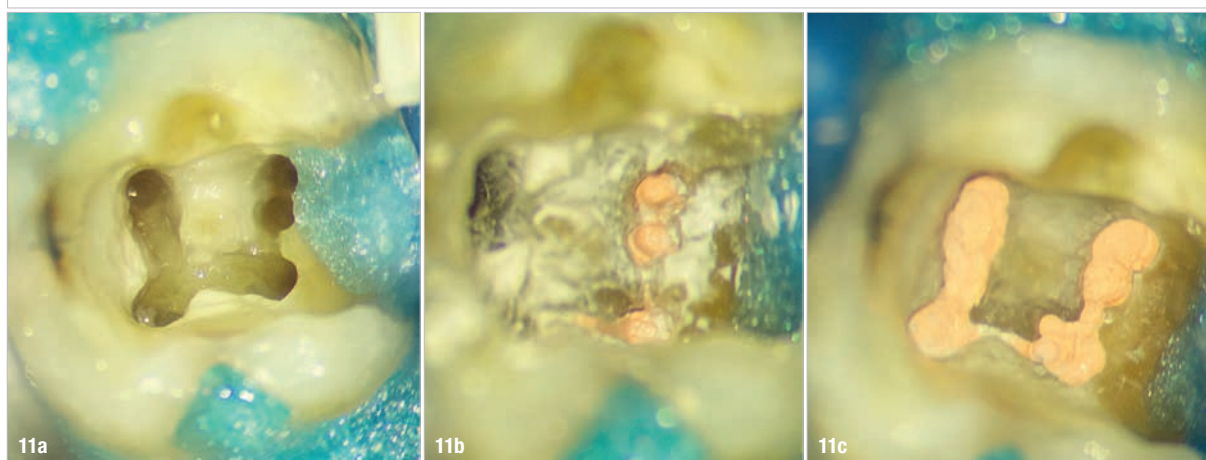


Pre-treatment

Cone Fit

Post-obturation

10



11a

11b

11c

power ultrasonic instruments and D-perfect C Files (Shenzhen Perfect Medical Instruments). Special care was given to the coronal portion of the root canal, especially to the mesiobuccal canal, owing to the scouted double curvatures. Pressureless mechanical pre-flaring was done to reduce the coronal interferences (cervical dentinal triangle—red triangle), which can place huge stress on the shaping files, leading to procedural errors such as instrument separation and transportation, thereby increasing the difficulty of an initially straightforward case.

Mechanical pre-flaring in such a case can be done using either the starter file (20/10) or the apical 3–4 mm of the 25/06 shaping file or even both. The mode of action of these files is brushing motion towards the outer walls.

#### Case 3 (Figs. 10 & 11)

The patient presented with a mandibular first molar with advanced symptomatic pulpitis and apical periodontitis. Taking into consideration the constricted appearance of the root canals on the digital radiograph, MG3 Gold was the best suited for the situation owing to the high cutting efficiency. Mechanical pre-flaring with the 25/06 file was done to facilitate body shaping using the 25/04 file and a secured mechanical glide path to a final size of 30/04 in the five-canaled molar.

## Conclusion

When dealing with anatomy, variability is the rule. This is the reason that the endodontic practitioner must be able to modify the sequence of the instruments and treatment approach according to the anatomy.

The introduction of new file systems like MG3 Gold with low shape memory and high cutting efficiency allows the clinician to manage different cases with an excellent margin of safety and predictability.

## about



**Dr Ahmed Shawky**, BDS, MSc, PhD, is a senior lecturer in endodontics at the Faculty of Dentistry of Cairo University in Egypt, and his field of research is regenerative endodontics. He is a consultant in micro-endodontics and has conducted more than 25 certified continuing education endodontic training courses both

nationally and internationally. He is an opinion leader for Dentsply Sirona Middle East and North Africa.

# Laser protocol for peri-implantitis treatment

An interview with Dr Michał Nawrocki

By Dental Tribune International



Dr Michał Nawrocki

**Laser is becoming essential** for every modern dental practice. Moreover, from an educational standpoint, there are many benefits in terms of the personal and professional development of the practitioner. In this interview, Dr Michał Nawrocki explains how laser dentistry has helped to advance his practice and career and why dental laser, and Fotona's LightWalker in particular, has become an essential part of his daily practice.

**Dr Nawrocki, you have been using laser technology since 2016. Looking back at your journey as a laser dentist, how has LightWalker impacted your everyday practice?**

I started my great adventure with Fotona's LightWalker in 2016. Before that I had used a diode laser, but it was

insufficient for me, and to be honest my knowledge of lasers, physics, indications and procedures was incomplete at the time. Then in January 2016, I invited Dr Ilay Maden to my clinic to conduct a course and teach my colleagues and me about various Er:YAG and Nd:YAG procedures with the LightWalker laser. A few months later, I decided to extend my knowledge about lasers by attending the Master of Science in Lasers in Dentistry presented by Prof. Norbert Gutknecht in Aachen. Now, I cannot imagine continuing my daily practice and treatments without having LightWalker. Sometimes, I use it as an additional tool during certain procedures, but very often it's a crucial and necessary tool for me to use to conduct a particular procedure.

## What procedures do you perform with laser?

Laser can be used in all fields of dentistry; however, I am mainly focused on implantology and surgery, as well as prosthodontics. In prosthodontics, it can be used for sulcus conditioning, preparation for veneers and removal of complete ceramic crowns, as well as during more challenging procedures like crown lengthening before tooth preparation. We can use it in gingivectomy (Nd:YAG laser) and bone recontouring (Er:YAG laser).

All my surgery cases are finished with photo-biomodulation using the Nd:YAG Genova handpiece. I have observed that wound healing is much faster and better in such cases owing to pain reduction, disinfection, reduction of oedema and the laser's analgesic function. Sometimes, I have to conduct an endodontic treatment during the procedure (which is quite rare and normally done by my colleagues), in which case I really appreciate the deep disinfection with Nd:YAG, which offers the highest bacterial reduction in comparison with other wavelengths, and the Er:YAG SWEEPS (shock wave-enhanced emission photoacoustic streaming) procedure, which provides the most effective cleaning and disinfection. With surgical treatments, I use both wavelengths in almost all cases. Even when performing an easy and fast tooth extraction, I can use Er:YAG for granulation tissue removal, followed by Nd:YAG for disinfection, clot stabilisation and finally photo-biomodulation. Of course, I use laser before implant insertion, as well as when complications appear.



**In your opinion, what are the main benefits of choosing a laser system that includes two complementary wavelengths, such as Er:YAG and Nd:YAG, especially in the field of oral surgery?**

Very often, we combine these two wavelengths to conduct treatment in a fast, safe and predictable way. For me, it's crucial to use these two complementary wavelengths—the interaction between the tissue and laser beam is quite different, and owing to these differences in absorption, transmission and scattering, we obtain different actions. For example, during root apicectomy, after flap elevation, I remove granulation soft tissue with the Er:YAG laser using the H14 handpiece with a cylindrical tip (or when I want to be more precise—a Varian tip) and the apicectomy is done with the H02 non-contact handpiece. As the next step, I conduct deep disinfection with the Nd:YAG laser (transmission in hydroxyapatite and absorption in pigmented bacteria) before bone augmentation. Finally, I finish the treatment with photo-biomodulation using the Nd:YAG laser. As you can see from this example, I need both of these two complementary wavelengths to achieve final success with fast healing and proper bone regeneration.

**One of your main fields of specialisation is implantology. Where does the laser fit in this field?**

We can use LightWalker for all implantology cases. Sometimes, it's only needed for better and faster wound healing (photo-biomodulation with the Nd:YAG laser), but very often it is necessary to conduct the treatment. For me, it's the most important device during immediate implantation with immediate loading, especially when the bone must be very precisely cleaned of granulation soft tissue and disinfected. In the meantime, we can also provoke bleeding of the bone using the Er:YAG laser for superficial bone ablation. I also really appreciate the use of laser during bone grafting with the Khoury method. Sometimes, I combine this technique with immediate implantation, especially in the aesthetic zone. Then, after bone shield fixation, I can use the laser for bone recontouring. With the Er:YAG laser, it's done very precisely—I remove sharp edges and create an emergence profile for the crown—and most importantly, everything is safe for the shield (almost no vibration, so we don't lose stability) and the implant (no thermal effect).

Of course, we can also use the Er:YAG laser for more common and “easy” procedures—like implant uncovering (Er:YAG). The healing is faster and we avoid suturing, but of course, even with the thin chisel tip, some amount of soft tissue is vapourised—so it cannot be conducted in all cases.

**In 2018, you defended your master's thesis at RWTH Aachen University titled *Comparison of Two Methods of Periimplantitis Treatment with the Use of Nd:YAG and Er:YAG Laser*. Can you tell us more about that research?**

Owing to the increasing number of implants being placed, the development of peri-implantitis is a growing concern and one of the primary challenges in present-day dentistry.

In cases of inflammation, it is necessary to implement treatment, or risk implant loss. However, until now, no uniform protocol or procedure has been defined which could be considered the best and the most effective solution. Different methods of treatment of tissue inflammation around the implant are used, depending on the extent of inflammation, method availability, type of defect, and skills and experience of the dental surgeon.

We know that laser can be used for the treatment of inflammation in soft and hard tissue around implants, such as mucositis and peri-implantitis. I wanted to investigate what kind of procedure would be the most effective and minimally invasive—so the question was whether we could use a minimally invasive, flapless procedure for proper treatment and solve the problem of inflammation.

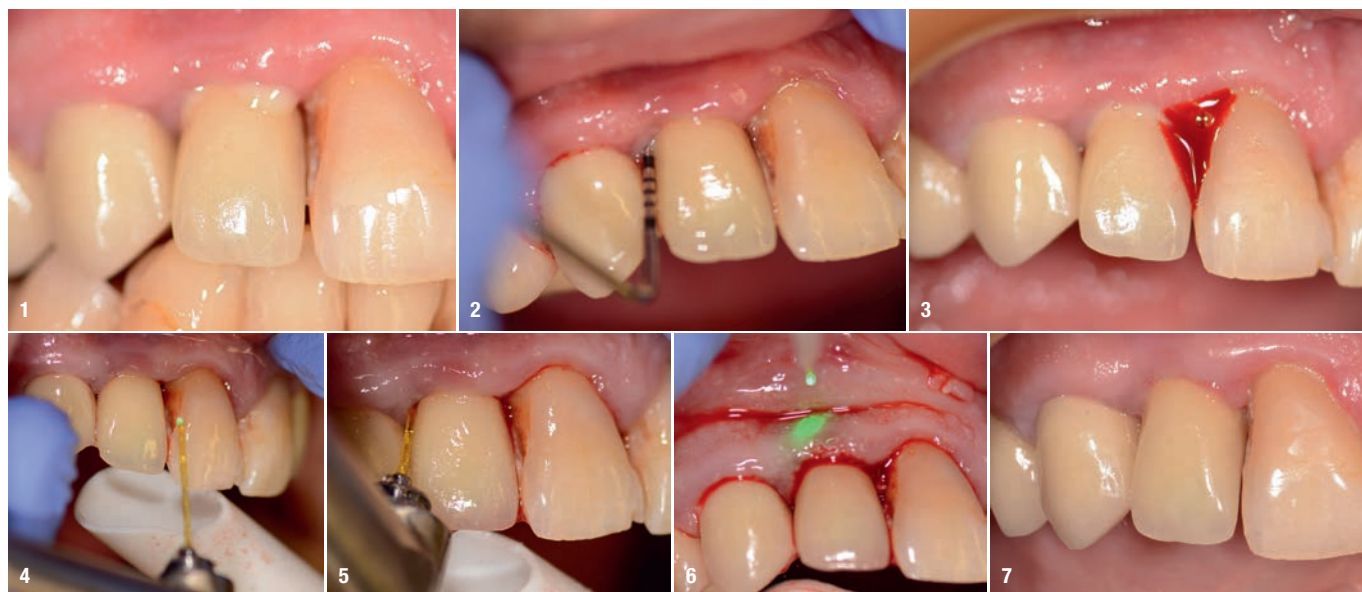**“I really appreciate the deep disinfection with Nd:YAG, which offers the highest bacterial reduction [...]”**

The procedures were conducted with Er:YAG and Nd:YAG lasers. In the first group of patients, a mucoperiosteal flap was elevated in order to gain better access to the operative area, while the second group of patients was treated using a more minimally invasive procedure without the flap method. The assessment of treatment effectiveness involved clinical and radiographic examination before the surgical procedures and three months after the laser procedures. After conducting the intra-oral examination and defining plaque, probing depth and bleeding on probing indices, photographic documentation of a given area was performed, bitewing and occlusal surface radiographs were taken, and professional scaling and root planing were subsequently carried out.

Based on my research, we know that non-surgical treatment of peri-implantitis is effective and very often reduces inflammation. Of course, when we have severe defects, it's impossible to avoid a surgical procedure to elevate a flap to get proper access to the defect. In such cases too, we should use a non-surgical procedure as a first step to decrease the inflammation and, after two to three weeks, perform the flap procedure.

**Can you describe your standard laser protocol for peri-implantitis treatment?**

Firstly, we have to distinguish mucositis from peri-implantitis with a radiovisiograph and with the use of a periodontal probe. If possible, I remove the prosthetic restoration to get better access for the treatment. In our surgical protocol, we have five steps: (1) removal of granulation tissue with the use of the Er:YAG laser (cylindrical tip); (2) decontamination



**Fig. 1:** Initial situation. **Fig. 2:** Pocket depth measurements. **Fig. 3:** Bleeding on probing. **Figs. 4 & 5:** Use of the Er:YAG laser Varian tip for granulation tissue removal, implant surface decontamination and surface ablation of infected bone. **Fig. 6:** Photo-biomodulation with the Nd:YAG laser. **Fig. 7:** Final results after three months. No sign of inflammation.

of the implant surface with Er:YAG; (3) surface ablation of infected bone with Er:YAG; (4) reduction of bacteria in the bone with the Nd:YAG laser; and (5) photo-biomodulation with the Nd:YAG laser (after flap closure).

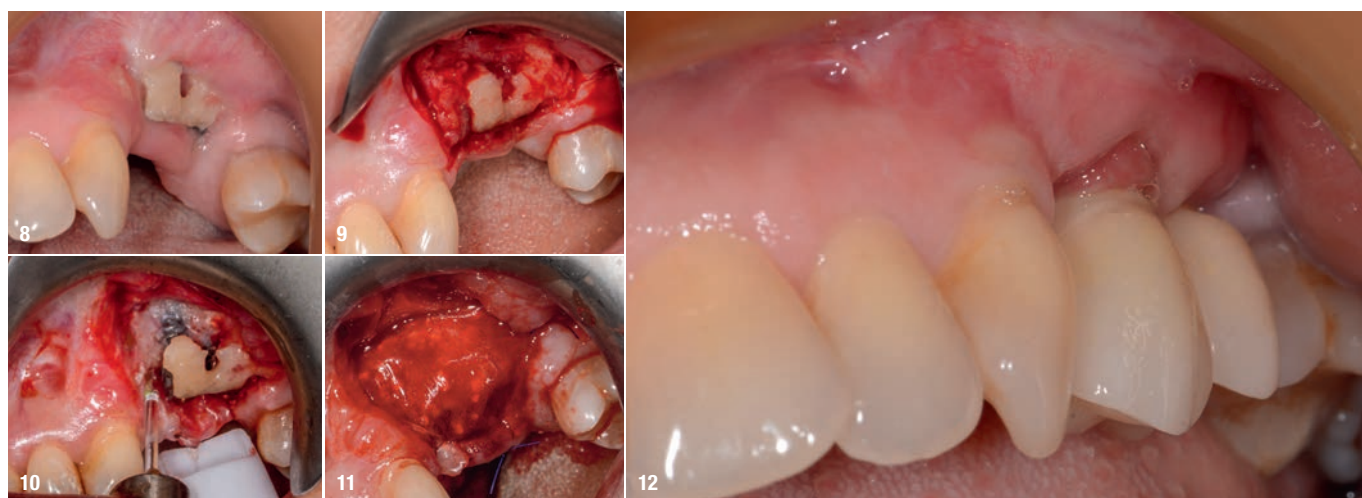In our non-surgical procedure, there are only four steps—I skip deep disinfection with the Nd:YAG laser owing to the 1,064 nm wavelength's high absorption in titanium (it's not possible without elevating a flap to disinfect only the bone and not harm the implant surface). As I mentioned, the flapless procedure is most often my first option, and when the defect is severe, I decide on a surgical procedure as the second stage.

After the procedure, the same restoration is generally placed in the mouth (after corrections if necessary). Some-

times, depending on the type of bone defect, I decide to conduct bone regeneration with the use of bone substitute and collagen membranes. In such cases, I have to remove the restoration and, after peri-implantitis treatment with the use of laser and bone augmentation, close the flap with cover screws, leaving the patient with no restoration (posteriorly), not even a temporary one, for two to three months.

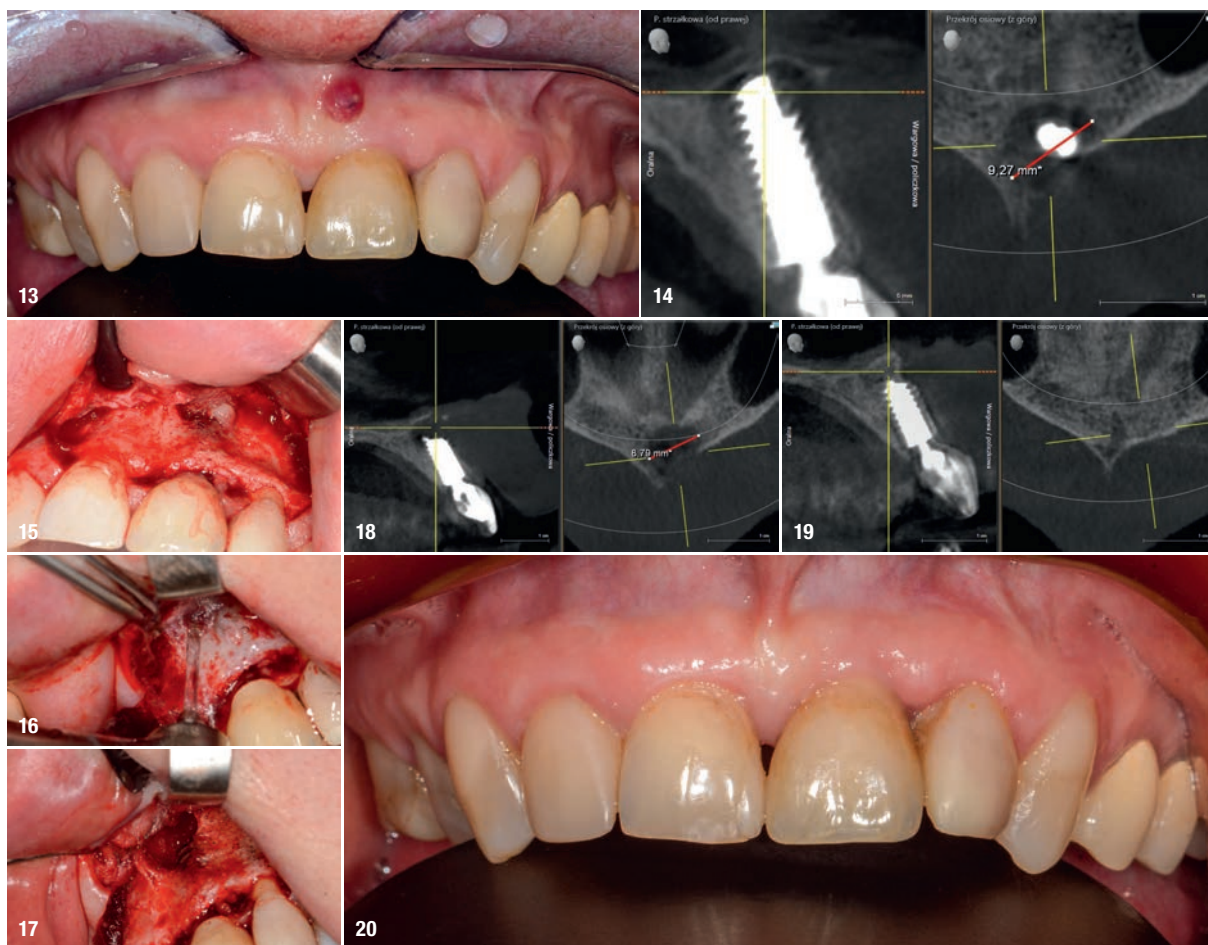
#### What are the benefits of LightWalker for the treatment of peri-implantitis in your everyday practice?

As I mentioned, the treatment of peri-implantitis is a huge challenge nowadays; statistically, in 20% of cases peri-implantitis develops and in 40% of cases mucositis develops around inserted implants. Treatment with the use of Er:YAG and Nd:YAG lasers is very effective, fast and comfortable



**Fig. 8:** Initial situation. **Fig. 9:** Granulation tissue visible after flap elevation. **Fig. 10:** Granulation tissue removal with Er:YAG laser. **Fig. 11:** Bone augmentation. **Fig. 12:** Final results with restoration two years post-op.





**Fig. 13:** Initial situation. Visible fistula one year after loading. **Fig. 14:** Bone defect of 9.27 mm in diameter. **Fig. 15:** Flap elevation. **Fig. 16:** Granulation tissue removal with Er:YAG. **Fig. 17:** Implant resection. **Fig. 18:** CBCT scan on the day of surgery. No bone augmentation. **Fig. 19:** CBCT scan 1.5 years post-op. Visible bone regeneration. **Fig. 20:** Situation 1.5 years post-op. No sign of inflammation.

for both patients and practitioners. We can use a minimally invasive, non-surgical treatment, which very often is highly effective, and thus avoid a surgical procedure. However, it's very important that we use our lasers with proper parameters to protect the soft and hard tissue and not alter the implant surface. We can thoroughly remove bacterial biofilm from the implant surface without altering it, and we have the possibility of re-osseointegration. Of course, we have to be aware of risk factors and aim to avoid them, understand what the reason for the disease was and solve the underlying problem. Sometimes, it's only improper oral hygiene, while other times, we must change or correct the restoration. Each case is individually treated.

**Could you share with us some of your more challenging cases of peri-implantitis and explain how the treatment was performed?**

Case 1 was a patient who presented with deep pockets (9 mm), bleeding on probing and visible purulent effusion (Figs. 1–7) and was treated with a non-surgical protocol. In Case 2, the patient preferred a surgical procedure with bone augmentation, as a consequence of bone graft complication and graft exposure (Figs. 8–12).

The implant apicectomy in Case 3 shows that one year after the immediate implantation with immediate loading there was inflammation around the implant apex. The rest was properly integrated (Figs. 13–20).

**What advice would you give to your dental colleagues who may be considering whether to incorporate laser technology into their practice?**

I can only advise them to use laser; there is no reason to hesitate. Laser technology really changes dental practice. Laser use provides new possibilities, new treatment protocols and many advantages in dental procedures. Our treatments are more comfortable, less painful (sometimes even painless) and very often less invasive and more predictable. We have a great advantage of selective tissue removal based on the chosen laser wavelength and settings. Last but not least, it is better for our marketing, and patients now expect newer technologies.

*Editorial note: A shortened version of this interview was published in implants—international magazine of oral implantology, vol. 23, issue 1/2022.*

# “The correct choice of an animal model is vital”

## An interview with Dr Alexis Gaudin

By Iveta Ramonaite, Dental Tribune International



Dr Alexis Gaudin

Dr Alexis Gaudin believes that novel diagnostic tools, such as the use of biological markers, could be an alternative to studying pulpitis on animal models in the future. (Image: © Alexis Gaudin)

As in other medical fields, both dental research and the pharmaceutical industry aim to identify therapeutic strategies that can decrease pain, that can make dental therapeutics more efficient, faster and more comfortable, and that can make more predictable results possible. The use of animal models can accurately replicate many oral diseases and dental issues. Their use makes it possible for scientists to conduct research into the effect of new drugs and therapeutic proposals.

“The correct choice of an animal model is vital in order to minimise suffering and cost while maximising efficiency and the success of the research.”

**Dr Alexis Gaudin** is an associate professor in the Department of Endodontics at Nantes Université in France. In 2021, together with five other researchers, he published a review article that sought to provide a thorough understanding of the different animal models used in dental research to study pulp inflammation. In this interview with Dental Tribune International, Dr Gaudin discusses the ideal animal model for studying pulpitis, talks about the increasing popularity of non-animal methods in dental research and considers the possibility of studying artificially generated caries-inducing models in the future.

**Dr Gaudin, why is it important to choose the most appropriate animal model in dental research, and how would you describe the ideal animal model for studying pulp inflammation?**

The correct choice of an animal model is vital in order to minimise suffering and cost while maximising efficiency and the success of the research. Scientific and practical decisions govern the selection of the animal model. For example, the animal model used must be as close as possible to humans from an anatomical, biological and physiological point of view. The operating conditions for inducing pulpitis, including accessibility and dental dam installation, must be technically simple, and the inflammatory conditions obtained must be equivalent to those found in humans.

The animal model should give the most precise and scientifically interpretable results while presenting the least serious biological risk for the research team. The results should be reproducible, and the animal model



should be available and have reasonable acquisition and care costs. The choice should also be directed towards the species requiring the fewest animals. Finally, the research should be conducted on the minimum number of animals to provide the maximum amount of information.

#### **What are some of the hurdles in choosing the correct animal model to study dental pulp?**

Among the animal kingdom, rodents, rabbits, ferrets, swine, dogs and non-human primates have been used to model human pulpitis. The diversity of animals found in studies indicates the difficulty of choosing the correct and most efficient model. Each animal model has its own characteristics that may be either advantageous or limiting, depending on the study parameters.

Non-human primate models have certain limitations such as zoonotic risks, supply difficulties and a high cost of purchase and maintenance.

It is generally accepted that the immune systems of rats and mice are comparable; however, much more information is available for the mouse. Moreover, there are differences between the results obtained in mice and rats. For instance, several studies have shown that the immune parameters in mice are more sensitive to the effects of stress (as measured by corticosterone) compared with those in rats. Even if rodents are the mainstay of *in vivo* immunological experimentation, it is important to point out that the immune systems of mice/rats and humans are quite similar but also present some differences, especially when it comes to development, activation and response to aggression. It is, therefore, necessary to consider the possibility that a given murine model response may not occur in exactly the same way in humans.

There are higher costs involved with the use of larger animals such as swine and dogs.

#### **How is pulpitis typically induced in animal models?**

There are three main dental pulp induction techniques found in the literature, varying according to the causal agent. The first technique consists of making cavities with burs under water spray until pulp exposure. The second method involves creating cavities under the same conditions as previously described, with or without pulp exposure. Once the cavity has been made, an exogenous supply of toxins, such as lipopolysaccharide or human carious dentine, is placed either directly in contact with the pulp or at the bottom of the cavity so that the toxins diffuse through the dentinal tubules.

The third induction technique consists of using transgenic animal models.

#### **What are some of the disadvantages of choosing an animal approach to studying pulpitis?**

The use of animal models in research is still debated from an ethical point of view. There is not an ideal animal model since they all have advantages and drawbacks.

#### **How effective are *in vitro* experiments and other experimental alternatives for studying pulpitis, and are they gaining increasing popularity in dental research?**

**“In the future, it might be possible to consider artificially generated caries-inducing models.”**

Alternative methods are gaining popularity since they are becoming increasingly accurate. They involve 3D experiments and can combine new knowledge to implement the experiment. The overall aim is to limit animal suffering and to protect the welfare of animals.

#### **What changes do you see in dental research on animals in terms of legislation, ethicality and the validity of findings?**

The rule of the three Rs was developed by Russel and Burch in 1959 and forms the basis of the regulation and the ethical foundation of the use of animals for scientific purposes. It stands for replacement, refinement and reduction (in the number of animals).

More recently, a fourth R, responsibility, was added in order to focus on the integrity and honesty of scientists regarding the proper and reasonable use of laboratory animals. However, legislation differs from country to country.

#### **In your opinion, how will dental pulp be studied in the future? Will there be novel methods that will help researchers better understand the physiology of dental pulp?**

In the future, it might be possible to consider artificially generated caries-inducing models that would represent a more elegant and closer-to-reality alternative to mechanical injury and lipopolysaccharide stimulation. This would also help to avoid off-target effects of the transgenic models.

Additionally, biological markers and other novel diagnostic tools could help to successfully visualise pulp morphology, vitality and regeneration.

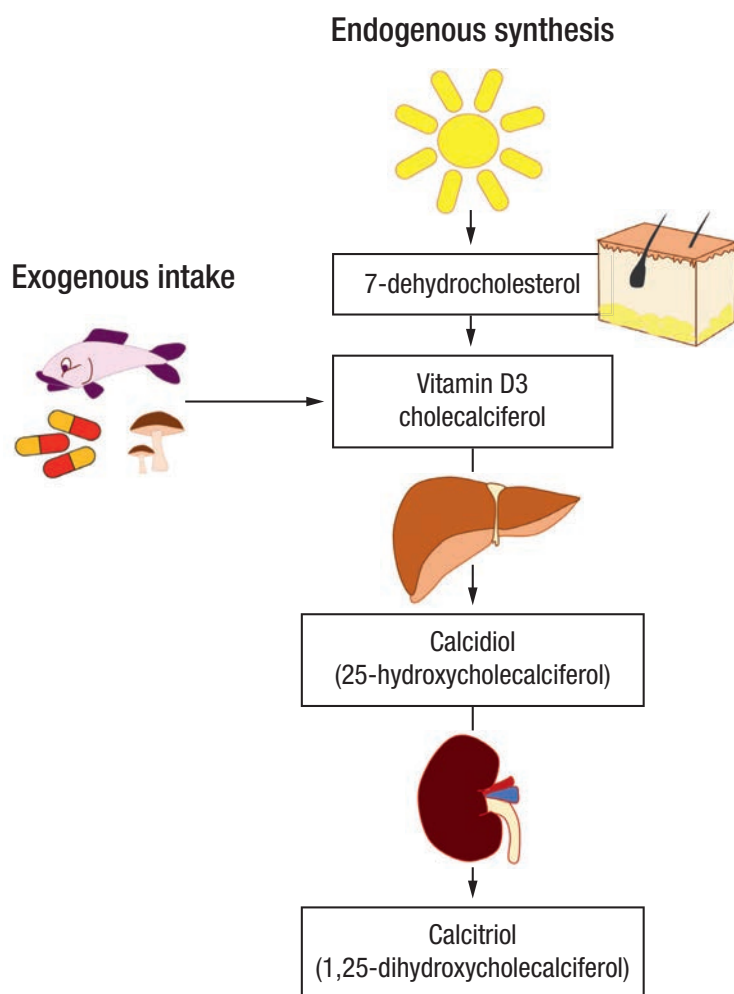
# The key role of vitamin D in immune health and regeneration

## The evidence for supplementation

Prof. Shahram Ghanaati, Dr Karl Ulrich Volz & Dr Sarah Al-Maawi, Germany & Switzerland

**A healthy immune system** is the basis of general good health and a good immune defence. It has been proved that individual habits, nutrition and the environment have an influence on our health.<sup>1</sup> A balanced and healthy diet in particular is the key to a healthy human body. An unbalanced diet can seriously impair the immune system and increase the risk of chronic disease as a result.<sup>1</sup> In the last decade, chronic diseases such as diabetes mellitus,

obesity and cardiovascular disease have surged sharply in various countries. A major reason for this is an increasingly unhealthy living environment and increasingly unhealthy lifestyle choices, especially in industrialised countries.<sup>2</sup> The role of food components and especially vitamins has become increasingly important in various areas. In 1928, the German biochemist Adolf Windaus was awarded the Nobel Prize in Chemistry for his work on the correlation between sterols and vitamins, which sparked further research interest in vitamin D.<sup>3</sup>



Vitamin D can be produced in a physiological way in the human body. Sunlight is essential for this endogenous synthesis, which takes place primarily in the skin, where 7-dehydrocholesterol is converted into cholecalciferol (vitamin D<sub>3</sub>) by UVB rays. In order to reach its biologically active form, cholecalciferol undergoes further conversion steps in the liver (calcidiol) and in the kidney (calcitriol). The latter is the biologically active form of vitamin D and acts as a transcription factor. After binding to the vitamin D receptor, calcitriol regulates the expression of various proteins in the cell. The physiological mode of action of calcitriol therefore resembles that of a hormone and not that of a vitamin. That is why vitamin D, as a precursor of calcitriol, should rather be regarded as a prohormone (Fig. 1).<sup>4,5</sup> The connection between vitamin D and parathyroid hormone was recognised shortly after its discovery. Within this context, the regulatory effect of vitamin D on the mineral balance of the body and in particular the regulation of calcium and phosphate levels was emphasised.<sup>6-8</sup> Furthermore, it was established quite early on that vitamin D plays an important role in mineralisation and bone formation. Consequently, many studies have focused on the influence of vitamin D on skeletal health and the treatment of diseases such as osteoporosis. These findings have contributed to vitamin D being primarily associated with bone health in the public perception.

However, some studies have shown the positive effect of vitamin D on the immune system too and thus on the general health of the body. Several studies have shown that vitamin D has a preventive effect on chronic diseases such as diabetes mellitus, hypertension and cardiovascular dis-





ease.<sup>9</sup> Studies also report its potential anti-inflammatory and antiviral effects.<sup>10</sup> In this context, it has been shown that vitamin D supplementation in pupils could reduce the incidence rate of influenza virus infection.<sup>11</sup> These rather new findings and the immunomodulatory effects of vitamin D demonstrate the importance of maintaining healthy vitamin D levels in the body. Since endogenous vitamin D synthesis is compromised by relatively short exposure to sunlight in most countries, the need for exogenous supply is becoming increasingly important. However, the intake of vitamin D through food seems to be insufficient in the general population, which has contributed to a global vitamin D deficiency pandemic.<sup>12</sup> This pandemic has already been documented and reported in numerous studies in various countries.<sup>13</sup> Nevertheless, its importance is still mostly under-estimated in most countries.

The concept of supplementation with vitamin D preparations was first introduced in the 1940s. Today, 90 years later, there are still no uniform recommendations regarding the dose to be taken. One of the reasons for this is the historical development and the association of vitamin D with bone health and the new knowledge about its further extensive capabilities. Although there is a growing amount of data on the non-skeletal effects of vitamin D

and its preventive role in many chronic diseases, current dose recommendations are still based solely on bone requirements. Another issue is the difficulty in standardising methods for the determination of serum vitamin D levels. This review therefore focuses on the non-skeletal effects of vitamin D and its supplementation dose based on randomised controlled clinical trials. It provides an overview of the new findings and treatment protocols.

### Immune system booster in the case of chronic and infectious disease

There is increasing interest in the study of the immune system-supporting mechanisms of vitamin D. Interestingly, the majority of body cells express vitamin D receptors on their surfaces, which emphasises the multimodal action of vitamin D. Owing to its regulatory effect, the active form of vitamin D as a hormone can intervene in the synthesis of various cytokines and regulate them according to their condition.<sup>14</sup> It has been shown that vitamin D inhibits the production of pro-inflammatory cytokines, whereas it up-regulates the synthesis of anti-inflammatory signal molecules.<sup>5</sup> In this way, it exerts its immunomodulatory effect and supports the differentiation of lymphocytes into Th2 cells and regulatory T cells.<sup>14</sup> This could explain

its potential preventive influence in chronic and infectious diseases. However, these mechanisms of action still remain largely unexplained for the respective indications. The correlation between vitamin D levels and the prevalence of various chronic diseases has been shown in several clinical studies. A meta-analysis of 25 prospective cohort studies has shown that low vitamin D levels increase the risk of developing cardiovascular disease. In about 10,000 patients, the risk of cardiovascular disease was about 44 % higher than in people with healthy vitamin D levels.<sup>15</sup> Another study showed a correlation between vitamin D levels and the development of hypertension. It examined 8,155 patients suffering from hypertension and vitamin D deficiency. After the vitamin D deficiency had been eliminated, 71 % of the patients no longer showed any symptoms or had measurably high blood pressure.<sup>16</sup> A positive influence of vitamin D has also been demonstrated in the development of Type 2 diabetes mellitus. It was shown that the number of patients in a prediabetic stage and with a vitamin D deficiency was significantly lower than in the untreated group, once the vitamin D deficiency had been eliminated.<sup>17</sup>

Furthermore, the potential of an anti-infectious or anti-viral effect of vitamin D has been increasingly investigated in recent years. As a result, vitamin D has gained greater significance as a preventive or adjuvant therapy.<sup>11,18</sup> A systematic review has shown that a vitamin D deficiency is associated with a higher viral load in hepatitis B patients.<sup>19</sup> Furthermore, it was shown that vitamin D can inhibit a herpesvirus infection through its anti-inflammatory and supportive defence effect.<sup>20</sup> In addition, studies have shown that vitamin D supplementation reduces the prevalence of influenza infections during influenza outbreaks.<sup>21</sup> Another meta-analysis showed that the number of certain vitamin D receptor polymorphisms involved in processing of vitamin D correlates with an increased risk of a viral in-

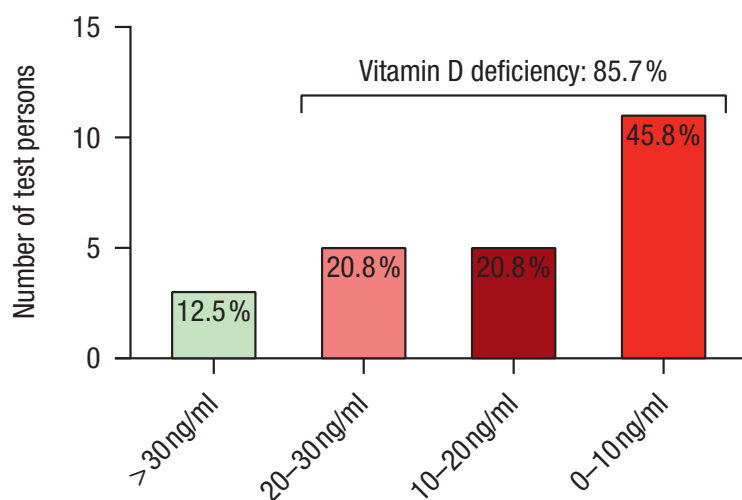
fection. Based on the vitamin D-mediated improved immune defence and its potential role as an antiviral agent, its importance in the prevention of viral diseases is increasingly being investigated. Especially in the COVID-19 pandemic, vitamin D supplementation can play an important role in preventing and defeating infection.<sup>22</sup>

## Determination of vitamin D levels and definition of hypovitaminosis

Vitamin D is a lipophilic molecule that is transported in the blood by carrier proteins. Approximately 80 % of these molecules are bound to the vitamin D binding protein in this manner. A further 10–15 % are bound to albumin and the rest circulates freely in the blood. The determination of the vitamin D level as part of a routine examination involves measuring the total concentration of all these forms. The 25(OH)D serum concentration is widely recognised as a reliable marker of vitamin D levels.<sup>12</sup> Similar to other vitamins and blood components, the vitamin D concentration is usually expressed in nanograms per millilitre (ng/ml) or in nanomoles per litre (nmol/l). Both units are used, depending on the individual testing laboratory. Here, it must be noted that 1 nmol/l equals 0.4 ng/ml. The definition of a healthy vitamin D level and thus hypovitaminosis is a matter of much debate. In the literature, a vitamin D level of less than 30 ng/ml (75 nmol/l) is considered a vitamin D deficiency (hypovitaminosis).<sup>13,19,23,24</sup> In various countries, studies have reported a general vitamin D deficiency. Observational studies have documented that the prevalence of vitamin D levels of below 20 ng/ml (50 nmol/l) is as much as 24 % in the US, 37 % in Canada and 40 % in Europe.<sup>13,24</sup> The German Robert Koch Institute reported that 58 % of 18- to 79-year-olds in Germany have a level of below 20 ng/ml (50 nmol/l).<sup>25</sup> This vitamin D deficiency pandemic was recognised as such several years ago. However, not much has been done in terms of supplementation and defining a sufficient dose. A pilot study examined the vitamin D levels of medical staff in the clinic for oral and maxillofacial plastic surgery at Goethe University in Frankfurt am Main in Germany. Out of 24 participants, 85.7 % had a vitamin D deficiency with a value below 30 ng/ml, whereas 45.8 % even had a value of below 10 ng/ml (Fig. 2). It is important to emphasise that a healthy vitamin D value is considered to be between 40 ng/ml and 60 ng/ml.

## Current guidelines for vitamin D supplementation

Given that, in most cases, endogenous synthesis of vitamin D is insufficient owing to limited exposure to sunlight, the body's vitamin D intake should also come from food or dietary supplements. The amount of vitamin D absorbed can be expressed in two units: micrograms (µg) and international units (IU). One microgram equals 40 international units (1 µg equals 40 IU). These units



**Fig. 2:** Distribution of vitamin D levels according to a pilot study conducted by the Clinic for Oral and Maxillofacial Plastic Surgery at Goethe University Frankfurt am Main.

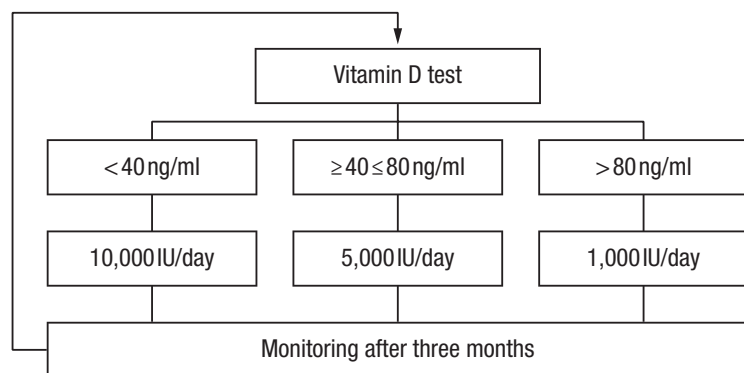


must be considered when administering vitamin D. Since in most cases vitamin D intake via food is insufficient for the body's needs, supplementation with vitamin D preparations is an utmost necessity. In the literature, the current recommendations for doses to be administered are largely inconsistent and are mainly based on the estimated requirements of maintaining optimal bone health. The recommendations range from 400 IU/day to 4,000 IU/day. The European Food Safety Authority recommends

a dose of 600 IU/day for healthy adults.<sup>22</sup> A similar recommendation, a dose of 400 IU/day, has been published by the Scientific Advisory Committee on Nutrition in the UK.<sup>26</sup> The Institute of Medicine Committee in the US recommends a dose of 600 IU/day for adults under 70 years of age and a dose of 800 IU/day for those over that age.<sup>27</sup> The American Association of Clinical Endocrinology recommends a dose of 1,000–4,000 IU/day.<sup>28</sup> The recently updated reference values of 2012 from the German

Category	Dose	Administration duration	Initial concentration	Targeted concentration	Side effects
Prevention in pupils <sup>21</sup>	1,200 IU/day	12 months	Not specified	Not specified	None
Cancer, cardiovascular disease <sup>30</sup>	2,000 IU/day	12 months	29.8 ng/ml	41.8 ng/ml	None
Diabetes mellitus <sup>17</sup>	4,000 IU/day	12 months	28.0 ng/ml	52.3 ng/ml	None
	4,000 IU/day	24 months	28.0 ng/ml	54.3 ng/ml	None
Ventilated patients in intensive care <sup>31</sup>	50,000 IU/day	5 days	23.2 ng/ml	45.0 ± 20.0 ng/ml	None
	100,000 IU/day	5 days	20.0 ng/ml	55.0 ± 14.0 ng/ml	None
Test persons with a vitamin D deficiency <sup>32</sup>	25,000 IU/fortnight	2 months	7.6 ng/ml	19.0 ng/ml	None
	25,000 IU/week	1.5 months	8.0 ng/ml	25.0 ng/ml	None
	25,000 IU/week	2 months	8.4 ng/ml	35.6 ng/ml	None
Test persons with a vitamin D deficiency <sup>33</sup>	1,000 IU/day	5 months	28.8 ng/ml	33.6 ng/ml	None
	5,000 IU/day		27.0 ng/ml	64.0 ng/ml	None
	10,000 IU/day		26.0 ng/ml	89.6 ng/ml	None
Breast cancer patients with bone metastasis <sup>34</sup>	7,000 IU/day	4 months	< 20.0 ng/ml	Not specified	None
Psychiatric clinic <sup>24,35</sup>	5,000 IU/day	12 months	24.0 ng/ml	68.0 ng/ml	None
	10,000 IU/day	12 months	25.0 ng/ml	96.0 ng/ml	None
Test persons with a vitamin D deficiency <sup>36</sup>	100,000 IU/month (3,000 IU/day)	36 months	24.4 ng/ml	54.0 ng/ml	None
Multiple sclerosis <sup>37</sup>	20,000 IU/day	12 months	21.6 ng/ml	44.0 ng/ml	None
Multiple sclerosis <sup>38</sup>	50,000 IU/week (7,142 IU/day)	6 months	15.3 ng/ml	33.7 ng/ml	None
Asthma, rheumatic arthritis, rickets, tuberculosis in the 1930s and 1940s <sup>24,39</sup>	60,000–600,000 IU/day	Not specified	Not specified	Not specified	Hypercalcaemia as a result of over-physiological vitamin D concentrations

**Table 1:** Overview of the vitamin D doses administered in selected randomised clinical studies.



3

**Fig. 3:** Vitamin D3 dose recommendation of the authors for healthy adults.

Nutrition Society estimate the need at 400 IU/day for children and 800 IU/day for adults.<sup>25</sup> The US research institute GrassrootsHealth collected data on the safety of a dose of 10,000 IU/day and found no undesirable side effects.<sup>24,29</sup> The European Food Safety Authority also classifies a dose of 10,000 IU/day as safe, but recommends no more than 4,000 IU/day.<sup>22</sup>

### Clinical supplementation protocols in randomised controlled clinical studies

As opposed to the recommendations of various authorities and institutions, relatively high doses of vitamin D have been administered in randomised controlled clinical trials, and these have in most cases led to the support of therapy. Various clinical supplementation protocols have been used with doses ranging from 1,000 IU/day to 100,000 IU/day. Two different strategies have been pursued: one option is to administer a relatively high dose, such as 100,000 IU, once a month to raise and maintain vitamin D levels; and the other option is to supplement with an adequate daily dose (between 5,000 IU/day and 10,000 IU/day) to cover the body's daily requirements. Most studies have documented an observation period of up to one year and have paid particular attention to the analysis of the dreaded side effect of vitamin D intoxication. However, no vitamin D intoxication was observed in any of these studies. A detailed overview of the respective studies is given in Table 1. Not long after the discovery of vitamin D and the recognition of its role in maintaining mineral balance, many diseases, such as asthma, rickets and tuberculosis, were treated in the 1930s and 1940s with extremely high daily doses of vitamin D (between 60,000 IU/day and 600,000 IU/day). These studies reported hypercalcaemia as a result of over-physiological vitamin D concentrations, which led to growing concern regarding vitamin D supplementation. It is important to note that these studies were carried out with much higher doses than the ones currently administered.

### Authors' dose recommendation for healthy adults

Today, the importance of vitamin D for the general health of the body and the immune system is well documented. A vitamin D value of between 40 ng/ml and 80 ng/ml should be aimed for. In contrast to the doses recommended by various associations, there is increasing evidence in current research that a relatively high daily dose is necessary to reach these values. However, there are no uniform guidelines at this point. Based on the investigated data, we recommend a daily dose that is adapted to the individual needs of the patient. In the case of a vitamin D deficiency (<40 ng/ml), a dose of 10,000 IU/day should be administered for three months to compensate for the deficiency. As a maintenance dose for a vitamin D level in the range of 40–80 ng/ml, a dose of 5,000 IU/day is recommended. If the level is higher than 80 ng/ml, it is advisable to reduce the dose to 1,000 IU/day. The vitamin D level should be checked every three months in order to adjust the dose to the individual needs of the patient (Fig. 3). When supplementing vitamin D, it is equally important to take the patient's medical history into consideration and, in the case of compromised organ function or metabolic disease, to individualise the dose accordingly.

*Editorial note: A list of references is available from the publisher. This article was first published in implants—international magazine of oral implantology, vol. 22, issue 1/2021.*

### about



#### Prof. Shahram Ghanaati

is a specialist in maxillofacial surgery and oncology, based in Frankfurt am Main, Germany. In 2013, he was appointed Director of the University Cancer Center of the Frankfurt University Hospital. He is the Senior Physician and Deputy Director of the Department of Oral and Maxillofacial

Plastic Surgery of the Frankfurt University Hospital. In addition, he is the Director of the research laboratory FORM-Lab (Frankfurt Orofacial Regenerative Medicine).

### contact

#### Prof. Shahram Ghanaati

Universitätsklinikum Frankfurt  
Theodor-Stern-Kai 7  
60590 Frankfurt am Main, Germany  
+49 69 6301-3744  
shahram.ghanaati@kgu.de



NEW  
VENUE



THE HYBRID EDITION

# THE LEADING DENTAL EXHIBITION AND CONFERENCE IN ASIA PACIFIC

NEW DATES:

**7-9**

**OCTOBER 2022**

**MARINA BAY SANDS  
SINGAPORE**

[www.idem-singapore.com](http://www.idem-singapore.com)

Connect with us



Endorsed by



Supported by



Held in



Organised by







Seiler Instrument celebrates its 77<sup>th</sup> anniversary this year

## US-based Seiler Instrument came from humble origins

When Seiler Instrument launched in September 1945, the staff included just its founders: husband and wife duo Eric H. and Dora Seiler. Operations ran out of a small rented manufacturing and office space located in downtown St Louis in Missouri. The company has come a long way since. Today, Seiler Instrument has about 240 employees, does business around the globe and boasts a nearly 13,800 m<sup>2</sup> headquarters in the Kirkwood suburb of St Louis.

Seiler Instrument was founded with a focus on repairing microscopes and surveying equipment. Eric H. Seiler, who was trained in Germany as an instrument maker, came to the US in 1923. "He was not only able to build instruments, but was also able to train people. That was the double benefit from him. He was a master of optics and able to train," said his grandson Tom Seiler, executive vice president of the company's geospatial and medical divisions.

Even during its subsequent expansion, Seiler Instrument's focus on optical instruments has not wavered. The company operates five major divisions: manufacturing, geospatial, medical, planetarium and design solutions. The company serves as a contract manufacturer for precision machining and optical instrument assembly and sells surveying software and instruments, microscopes, ZEISS planetarium equipment and theatre equipment for astrology and related fields.

Key to the company's long tenure has been a "strong family unit", according to Tom. The company is led by its third generation,

which includes Tom, his brother Eric (Rick) Seiler Jr, who is president and CEO, and their sister Louise Schaper, director of compliance and planetarium division manager. Of the second generation, Eric P. Seiler remains chairman of the company and his wife, Hazel Elaine, is a board member. Four members of the family's fourth generation are also involved in the company.

Perhaps the greatest challenge for Seiler Instrument since its founding has been managing its growth and finances without straying from the family-owned and closely held vision of the company, said Tom. "We have benefited greatly from our strong relationships and support from UMB Bank over 40 years," he said.

Seiler Instrument celebrates its 77<sup>th</sup> anniversary this year, but Tom said the family is not slowing down. It is targeting several growth channels, including in its medical division, where executives see opportunity for long-term strategic growth with 3D microscopes. The company hopes to achieve that through existing vendor relationships throughout the world.

According to Dane Carlson, medical division manager, "Dentistry does not lend itself to good posture, causing injury. The dental microscope is a wonderful ergonomic tool, but Seiler's new 3D microscope provides an even better ergonomic opportunity for the dentist. While using the 3D microscope, the dentist is not in a static position, and the 3D microscope allows the end user to manipulate the optical pod in a 360° rotation while the monitor stays directly in front of the dentist. This is the first 3D dental surgical microscope built with this unique design. This distinctive design allows the end user to learn the microscope quicker and be able to provide many direct vision angles not achievable with the traditional microscope."

While Seiler Instrument has grown significantly since its founding in the 1940s, Tom said it has not strayed from its roots. A point of pride for the company, he said, is a high number of first-generation immigrant employees "working to achieve the American dream". "That's exactly what our grandparents were. Our founder was a first-generation immigrant," said Tom.

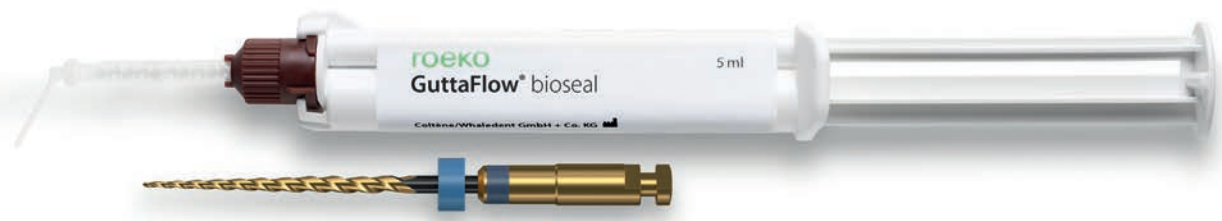[www.seilerinst.com](http://www.seilerinst.com)





## Removers and obturation material leave a lasting impression

# European dentists test Remover files and obturation material—a strong duo for revision work



Practicality in its ongoing product innovations is a top priority for international dental specialist COLTENE. True to its motto “Upgrade Dentistry”, the company has set itself the goal of continuously making the everyday work routines of dentists and their teams easier and more efficient. In addition to the development of new working aids and dental materials in collaboration with experts and research institutions all over the world, extensive testing in dental practices therefore plays a significant role.

Nearly 600 dentists from across Europe took part in a large-scale practice experiment in which special attention was paid to the handling of endodontic revision treatment. The specifically developed Remover revision files manufactured by COLTENE were used in combination with the GuttaFlow bioseal ceramic sealer.

Depending on their personal preferences, participants could choose between the Remover for the HyFlex or MicroMega filing systems. The revision files are available in size 30/07 and in lengths of 19 and 23 mm. In next to no time, they remove insufficient gutta-percha fillings or similar older endodontic restorations. Owing to their intricate shape, they adapt to the natural contour of the canal and efficiently loosen the existing dental material without requiring any additional solvents. At the same time, the Remover files are gentle on the surrounding tooth structure and their non-cutting tip provides additional safety during preparation.

Accordingly, both endodontic experts and beginners alike had good experiences in the practice experiment. The survey results confirm the significant improvement in efficiency when switching from various hand files as well as existing conventional preparation files and revision systems to revision with a single Remover nickel–titanium file: 42% of respondents rated the performance in removing obturation

material as excellent, and another 47% as good. In addition, more than half of the participants reported noticeable time-savings compared with their previous approach. This is all the more remarkable because files from a wide variety of manufacturers and different methods of filing had been stated for previous use. After the test, over 85% indicated that they would continue to use the file in the future.

During subsequent filling and sealing of the root canal with the GuttaFlow bioseal ceramic sealer, the rating of the properties respondents liked the most differed. Among other things, the obturation material supports regeneration by raising the pH level in the root canal. Hydroxyapatite crystals are formed on contact with bodily fluid. These are natural components of bone and tooth tissue and thus support the healing process. The majority of respondents (60%) named ease of handling as the most outstanding feature of the obturation material. Rapid polymerisation in only 12–16 minutes, good radiopaque visibility and flowability were also rated positively. Over 72% of the testers were very satisfied or satisfied with the overall result of treatment, and 75% of the dentists said that they could imagine continuing to use GuttaFlow bioseal in their practice in the future.

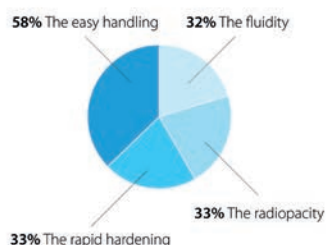
## Quick answers to questions about application

For the optimal integration of the newly developed instruments and dental materials, as well as for other application issues in endodontics, COLTENE regularly offers continuing education, practice workshops and webinars. At [www.coltene.com](http://www.coltene.com) or one of the innovation leader’s social media channels, interested dentists can find out about the latest trends and ideas from the dental world. This way, even endodontic beginners will soon be able to achieve competent and efficient preparation.

[www.coltene.com](http://www.coltene.com)

In a Europe-wide study conducted with about 600 dental professionals, the majority of testers of GuttaFlow bioseal ceramic from COLTENE were very satisfied or satisfied with the overall result of treatment. (All images: © COLTENE)

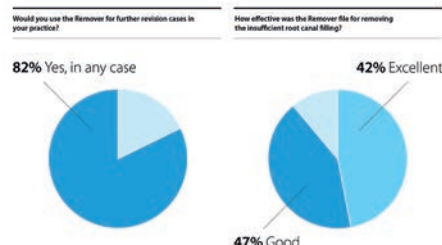
### Product evaluation GuttaFlow bioseal - Most convincing features for the participants\*



63 responses  
\*Result online survey Remover and GuttaFlow bioseal trial promotion January – May 2021

**COLTENE**

### Product evaluation - Remover for HyFlex and MicroMega file systems\*



63 responses  
\*Result online survey Remover and GuttaFlow bioseal trial promotion January – May 2021

**COLTENE**

# International events



## ROOTS SUMMIT 2022

26–29 May 2022  
Prague, Czech Republic  
[www.roots-summit.com](http://www.roots-summit.com)



## AAID Annual Conference 2022

21–24 September 2022  
Dallas, USA  
[www.aid.com](http://www.aid.com)



## 17th IDEX Istanbul 2022

26–29 May 2022  
Istanbul, Turkey  
<https://cnridex.com>



## Dental World Budapest 2022

13–15 October 2022  
Budapest, Hungary  
<https://dentalworld.hu/dental-world-2022-en>



## SIDEX Seoul International Dental Exhibition & Scientific Congress 2022

27–29 May 2022  
Seoul, South Korea  
<https://eng.sidex.or.kr>



## 19th ESCD Annual Meeting

13–15 October 2022  
Rome, Italy  
<https://escdonline.eu>



## DENTAL BERN 2022

9–11 June 2022  
Bern, Switzerland  
<https://dental2022.ch>



## Formnext 2022

15–18 November 2022  
Frankfurt am Main, Germany  
<https://formnext.mesago.com/events/en.html>



## EuroPerio10

15–18 June 2022  
Copenhagen, Denmark  
[www.efp.org/europerio](http://www.efp.org/europerio)

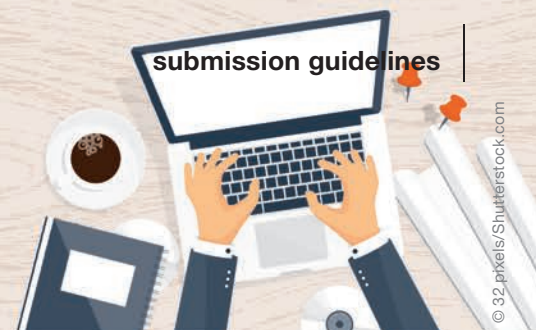


## IDS 2023

14–18 March 2023  
Cologne, Germany  
[www.ids-cologne.de](http://www.ids-cologne.de)



# How to send us your work



Please note that all the textual components of your submission must be combined into one MS Word document. Please do not submit multiple files for each of these items:

- the complete article;
- all the image (tables, charts, photographs, etc.) captions;
- the complete list of sources consulted and
- the author or contact information (biographical sketch, mailing address, e-mail address, etc.).

In addition, images must not be embedded into the MS Word document. All images must be submitted separately, and details about such submission follow below under image requirements.

## Text length

Article lengths can vary greatly—from 1,500 to 5,500 words—depending on the subject matter. Our approach is that if you need more or fewer words to do the topic justice, then please make the article as long or as short as necessary.

We can run an unusually long article in multiple parts, but this usually entails a topic for which each part can stand alone because it contains so much information.

In short, we do not want to limit you in terms of article length, so please use the word count above as a general guideline and if you have specific questions, please do not hesitate to contact us.

## Text formatting

We also ask that you forego any special formatting beyond the use of italics and boldface. If you would like to emphasise certain words within the text, please only use italics (do not use underlining or a larger font size). Boldface is reserved for article headers. Please do not use underlining.

Please use single spacing and make sure that the text is left justified. Please do not centre text on the page. Do not indent paragraphs, rather place a blank line between paragraphs. Please do not add tab stops.

Should you require a special layout, please let the word processing programme you are using help you do this formatting automatically. Similarly, should you need to make a list, or add footnotes or endnotes, please let the word processing programme do it for you automatically. There are menus in every programme that will enable you to do so. The fact is that no matter how carefully done, errors can creep in when you try to number footnotes yourself.

Any formatting contrary to stated above will require us to remove such formatting before layout, which is very time-consuming. Please consider this when formatting your document.

## Image requirements

Please number images consecutively throughout the article by using a new number for each image. If it is imperative that certain images are grouped together, then use lowercase letters to designate these in a group (for example, 2a, 2b, 2c).

Please place image references in your article wherever they are appropriate, whether in the middle or at the end of a sentence. If you do not directly refer to the image, place the reference at the end of the sentence to which it relates enclosed within brackets and before the period.

In addition, please note:

- We require images in TIF or JPEG format.
- These images must be no smaller than 6 x 6 cm in size at 300 DPI.
- These image files must be no smaller than 80 KB in size (or they will print the size of a postage stamp!).

Larger image files are always better, and those approximately the size of 1 MB are best. Thus, do not size large image files down to meet our requirements but send us the largest files available. (The larger the starting image is in terms of bytes, the more leeway the designer has for resizing the image in order to fill up more space should there be room available.)

Also, please remember that images must not be embedded into the body of the article submitted. Images must be submitted separately to the textual submission.

You may submit images via e-mail or share the files in our cloud storage (please contact us for the link).

Please also send us a head shot of yourself that is in accordance with the requirements stated above so that it can be printed with your article.

## Abstracts

An abstract of your article is not required.

## Author or contact information

The author's contact information and a head shot of the author are included at the end of every article. Please note the exact information you would like to appear in this section and format it according to the requirements stated above. A short biographical sketch may precede the contact information if you provide us with the necessary information (60 words or less).

## Questions?

Magda Wojtkiewicz  
(Managing Editor)  
[m.wojtkiewicz@dental-tribune.com](mailto:m.wojtkiewicz@dental-tribune.com)

# roots

international magazine of endodontics

## Imprint

### **Publisher and Chief Executive Officer**

Torsten R. Oemus  
[t.oemus@dental-tribune.com](mailto:t.oemus@dental-tribune.com)

### **Managing Editor**

Magda Wojtkiewicz  
[m.wojtkiewicz@dental-tribune.com](mailto:m.wojtkiewicz@dental-tribune.com)

### **Designers**

Franziska Schmid

### **Copy Editors**

Sabrina Raaff  
Ann-Katrin Paulick

### **Editorial Board**

Fernando Goldberg, Argentina  
Markus Haapasalo, Canada  
Clemens Bargholz, Germany  
Michael Baumann, Germany  
Benjamin Briseno, Germany  
Heike Steffen, Germany  
Gary Cheung, Hong Kong  
Asgeir Sigurdsson, Iceland  
Adam Stabholz, Israel  
Philippe Sleiman, Lebanon  
Jorge Vera, Mexico  
Unni Endal, Norway  
Esterban Brau, Spain  
José Pumarola, Spain  
Kishor Gulabivala, United Kingdom  
William P. Saunders, United Kingdom  
Fred Barnett, USA  
L. Stephan Buchanan, USA  
James Gutmann, USA  
Ben Johnson, USA  
Kenneth Koch, USA  
Sergio Kuttler, USA  
John Nusstein, USA  
Ove Peters, USA

## International Administration

### **Chief Financial Officer**

Dan Wunderlich

### **Chief Content Officer**

Claudia Duschek

### **Clinical Editors**

Nathalie Schüller  
Magda Wojtkiewicz

### **Editors**

Franziska Beier  
Jeremy Booth  
Brendan Day  
Iveta Ramonaite

### **Executive Producer**

Gernot Meyer

### **Advertising Disposition**

Marius Mezger

### **Art Director**

Alexander Jahn

## International Headquarters

### **Dental Tribune International GmbH**

Holbeinstr. 29, 04229 Leipzig, Germany  
Tel.: +49 341 48474-302  
Fax: +49 341 48474-173  
General requests: [info@dental-tribune.com](mailto:info@dental-tribune.com)  
Sales requests: [mediasales@dental-tribune.com](mailto:mediasales@dental-tribune.com)  
[www.dental-tribune.com](http://www.dental-tribune.com)

### **Printed by**

Löhnert Druck  
Handelsstraße 12  
04420 Markranstädt, Germany

## Copyright Regulations

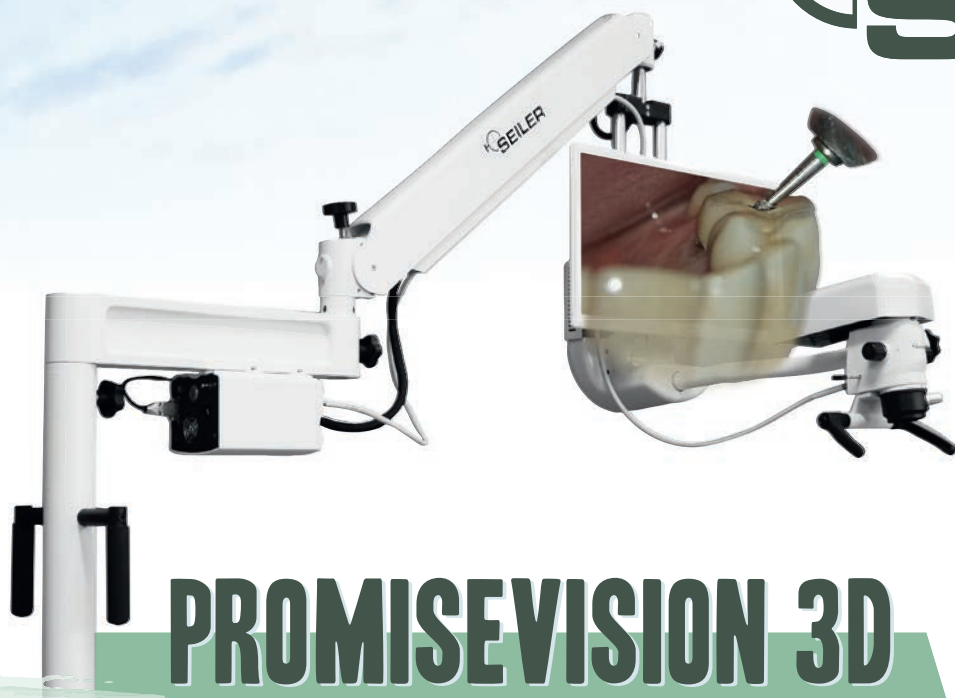All rights reserved. © 2022 Dental Tribune International GmbH. Reproduction in any manner in any language, in whole or in part, without the prior written permission of Dental Tribune International GmbH is expressly prohibited. Dental Tribune International GmbH makes every effort to report clinical information and manufacturers' product news accurately but cannot assume responsibility for the validity of product claims or for typographical errors. The publisher also does not assume responsibility for product names, claims or statements made by advertisers. Opinions expressed by authors are their own and may not reflect those of Dental Tribune International GmbH.

**dti** Dental  
Tribune  
International





# SEILER MEDICAL



## PROMISEVISION 3D

4.5X-28X MAGNIFICATION

SEAMLESS VIEWING AT 60 FPS

UNPRECEDENTED DEPTH OF FIELD

HEAD-UP 3D VIEW

NATURAL 3D IMAGE

NORMAL DEPTH PERCEPTION

NO EYEPIECES

HD VIDEO CAPTURE SYSTEM



**Dr. Jenner Argueta**

*DDS, M.Sc.*

"When you're looking for equipment that can satisfy the current requirements to practice biologically safe Dentistry, it's the perfect choice."



**Dr. Tuong Nguyen Nguyen**

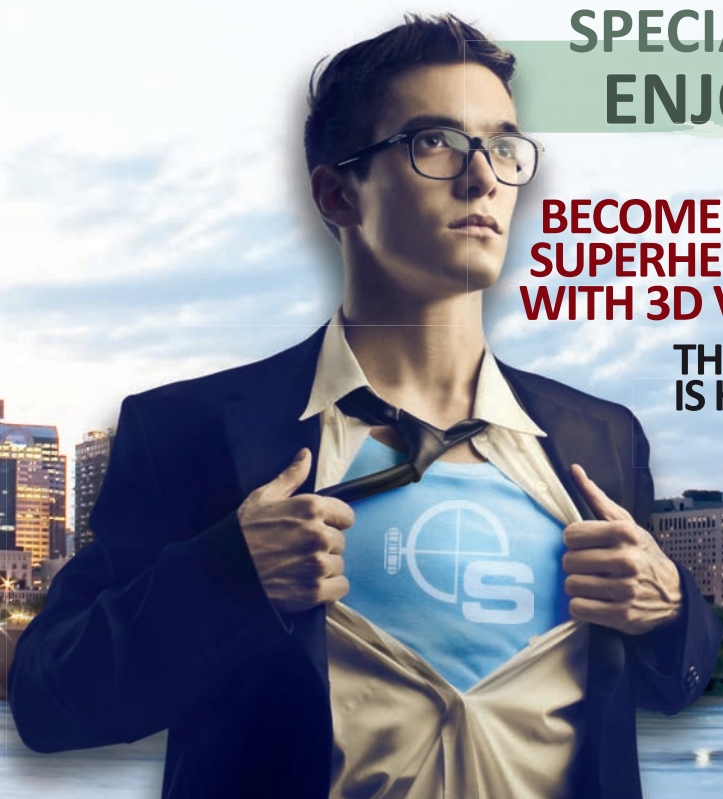*BDS, MSD*

"It's going to project you way forward because of the ability to see and therefore to make very well informed decisions."

## SPECIAL COVID FINANCING OFFER! ENJOY 0% FOR 12 MONTHS

**BECOME A  
SUPERHERO  
WITH 3D VISION.**

**THE FUTURE  
IS HERE**



(800) 489-2282  
[www.seilermedical.com](http://www.seilermedical.com)



# CanalPro™ Jeni

Digital assistance system for canal preparation

**Jeni - ready - go!**



- Digital assistance system for canal preparation controls the file movement at millisecond intervals
- Movement profile of the file continuously adapts to the individual root canal anatomy
- Irrigation recommendation is indicated by an acoustic signal
- Due to the integrated apex locator and fully insulated angled handpiece, continuous measurement of the working length is possible in real time

## Perfectly matched to four file systems

Four NiTi file systems are pre-programmed especially for use in the Jeni-Move. Due to Doctor's Choice function, flexible use with individual file sequences is also possible.

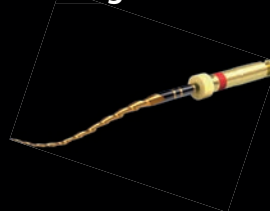**HyFlex™ EDM**



**HyFlex™ CM**



**MicroMega One Curve**



**MicroMega 2Shape**

