

# implants

international magazine of oral implantology



## research


The Implant Protection Plan


## case report

The Stable Tissue Concept

## events

50 plus one years into the future





**Z** for Zirconia, **1** for One-stage surgery.



## Z1<sup>®</sup> Implant

Giving you confidence in implantology.



### Proven clinical outcomes for patient safety

- ✓ Anti-bacterial shield
- ✓ Ideal in fresh extraction sockets
- ✓ Immediate aesthetic result



### Proven economics for a profitable implant practice

- ✓ Reduced chairtime
- ✓ Practice development
- ✓ Patient satisfaction



### Proven surgical protocols for a simplified workflow

- ✓ Only 1 surgery
- ✓ No healing abutment
- ✓ Visibility of the connection



### Proven Technology for a better integration

- ✓ 98.6%\* success rate
- ✓ Pure Titanium and Y-TZP Zirconia
- ✓ Suitable for all prosthetic solutions



Find us online

**www.tbr.dental**



Unique, like your smile

\*Z1 implants are medical devices of class IIb manufactured by SUDIIMPLANT SAS. Information collected from the data of the Smileranquility® Program based on 15.534 patients with Z1 implants from 01/2014 to 01/2016.

Dr Rolf Vollmer

First Vice President and Treasurer of DGZI



## 50 years of DGZI—a strong indicator for European dental implantology

In celebration of the 50-year anniversary of the German Association of Dental Implantology (DGZI), its third Future Congress for Dental Implantology was held in Cologne in Germany in early October. Owing to coronavirus-related travel and other restrictions imposed by governments worldwide, we had to celebrate our anniversary with a delay of one year, but this did not hinder its success in any way. We can proudly look back on a beautiful and worthy celebration of half a century of European implantology and a multifaceted, exciting congress. All in all, this one-of-a-kind event did full justice to the unique occasion.

As the oldest implantological expert society in Europe, celebrating 50 years of our existence was truly a milestone for us. We used the special event in Cologne as an occasion to reflect on the incredible developments that dental implantology has undergone in the past 50 years since our foundation by the visionary group led by Prof. Hans Grafelmann. DGZI has accompanied and helped to shape these developments from their very beginnings until today. Moreover, through our anniversary congress, we have succeeded in providing a visionary outlook of what future implantology might offer in five to ten years from now in terms of new clinical techniques and new approaches to implantology in general.

We can proudly say that our valued guest speakers were indeed the who's who of European implantology and

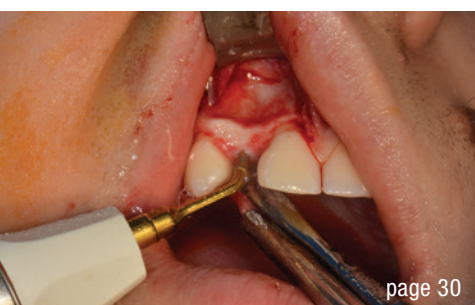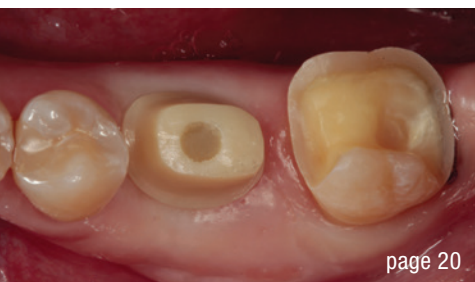
contributed greatly to the scientific programme. Against this background, I would like to express my most sincere gratitude to the presidents and board members of the German Society for Implantology (DGI), the German Society of Oral Implantology (DGOI) and the other specialist societies who accepted our invitation to address our congress participants and delivered truly insightful lectures. Despite the undoubtedly competitive situation between the various professional associations, the 2021 event in Cologne revealed something quite important: on certain topics and in certain situations, those at the forefront of German—and on a broader scale of course European—dental implantology are united in their vision of the future orientation of implantology. This is a strong indicator for us!

In this spirit, I would like to extend warm and friendly greetings to you and wish you enjoyable reading of the last issue of this anniversary year of **implants—international magazine of oral implantology**, as well as a reflective time ahead of the Christmas season!

Sincerely yours,

A handwritten signature in black ink, appearing to read 'R. Vollmer'.

Dr Rolf Vollmer



Cover image courtesy of  
Argon Dental / [www.argon-dental.de](http://www.argon-dental.de)



## editorial

- 50 years** of DGZI—a strong indicator for European dental implantology 03  
Dr Rolf Vollmer

## research

- The Implant **Protection** Plan (I.P.P.) 06  
Drs Tiziano Testori, Giordano Bordini & Matteo Basso
- The role of **metallic** nano- and microparticles in **peri-implantitis** 14  
Dr Ioannis Papadimitriou

## case report

- The **Stable Tissue** Concept 20  
Dr Kai Zwanzig
- Sinus augmentation** and simultaneous implant placement 24  
Drs Fernando Duarte, Carina Ramos, Paulo Veiga & Marco Infante da Câmara
- Alveolar deficiency** management in maxillary lateral incisor agenesis 30  
Dr Federico Berton
- Immediate **functional** implants in the **aesthetic** zone of a heavy smoker 32  
Dr Dr Branislav Fatori & Dr Inge Schmitz

## interview

- Fine dentistry** and creative engineering go hand in hand 34  
An interview with Dr Kai Zwanzig and Ric Donaca

## news

- manufacturer news 38
- news 48

## events

- 50 plus one** years into the future 42  
Dr Georg Bach

## about the publisher

- imprint 50



# NovoMatrix™ Reconstructive Tissue Matrix – the next generation material

NovoMatrix™ Reconstructive Tissue Matrix is an acellular dermal matrix derived from porcine tissue intended for soft tissue applications. The proprietary LifeCell™ tissue processing is designed to maintain the biomechanical integrity of the tissue, which is critical to support tissue regeneration.

### Indications

- Localized gingival augmentation to increase keratinized tissue (KT) around teeth and implants
- Alveolar ridge reconstruction for prosthetic treatment
- Guided tissue regeneration procedures in recession defects for root coverage

### Product features

- Consistent thickness (1 mm)
- Pre-hydrated
- Controlled source

[www.biohorizonscamlog.com](http://www.biohorizonscamlog.com)

Before use, physicians should review all risk information, which can be found in the Instructions for Use attached to the packaging of each NovoMatrix™ Reconstructive Tissue Matrix graft. NovoMatrix™ is a trademark of LifeCell™ Corporation, an Allergan affiliate. ©BioHorizons. All rights reserved. Not all products are available in all countries.



## Bone tissue augmentation

# MinerOss™ A The allograft for outstandingly fast bone remodeling [1]

The scientific evidence shows that allografts are the second best option to patient's own bone compared to other bone substitutes. [2]

### Benefits of MinerOss™ A human bone substitute [1, 3–5]

- Optimal osteoconductivity
- Fast graft incorporation
- Complete remodeling potential

[www.biohorizonscamlog.com](http://www.biohorizonscamlog.com)



- [1] Wen et al. J. Periodont. 2019, 1, 734.  
[2] Schmitt et al. Clin Oral Implants Res. 2013, 24, 576.  
[3] Kloss et al. Clin Oral Implants Res. 2018, 29, 1163.  
[4] Solakoglu et al. Clin Implant Dent Relat Res. 2019, 21, 1002-1016.  
[5] Kloss et al. Clin Case Rep. 2020, 8, 5.  
References available at: [www.biohorizonscamlog.com/references\\_minerossa](http://www.biohorizonscamlog.com/references_minerossa)

MinerOss™ A is a trademark of BioHorizons®. BioHorizons® is a registered trademark of BioHorizons. ©BioHorizons. All rights reserved. Not all products are available in all countries.



# The Implant **Protection** Plan (I.P.P.)

## Innovative implant and periodontal maintenance protocol

Drs Tiziano Testori, Giordano Bordini & Matteo Basso, Italy

### Introduction

The last 30 years of world dentistry have undoubtedly been characterised by the exponential growth of implantology, which has gone from being a discipline in the hands of a few experts “to being a field of treatment at many dental practices. There are several reasons for this increase: firstly, surgical and prosthetic techniques have been simplified over the years, repeatable protocols being certified by decades of literature, reducing costs for the patient and limiting invasiveness and post-operative discomfort. In addition, many patients want an aesthetic and functional restoration by means of fixed implant prostheses as their first choice, rather than resorting to solutions such as removable prostheses or fixed prostheses on natural teeth involving the prosthetic

“... modern implantology  
is trying to address the  
possibility of guaranteeing a  
clinical result that endures  
over time ...”

preparation of healthy teeth. Ultimately, it should not be under-estimated that implantology has also increased because it represents a source of income for the economic balance sheet of many healthcare facilities that have decided to specialise in this field. However, the implementation of an oral implant rehabilitation, be it a single tooth or a complex solution, cannot and must not today represent the end point either for the patient or for the dentist and his or her team. Nowadays, thanks to our knowledge, we have no difficulty in achieving implant-based rehabilitation even in cases of severe bone atrophy using regenerative techniques.

The critical point that modern implantology is trying to address, not always successfully, is the possibility of guaranteeing a clinical result that endures over time.

To achieve this ambitious goal, it is crucial to design an effective and feasible implant and periodontal maintenance protocol. We know that home maintenance around implants can be more difficult than around natural teeth because the techniques and instruments to be used, in many clinical cases, are inevitably different from those used for natural teeth. In addition, we may be confronted with the typical pathologies of implants, represented by mucositis and peri-implantitis, subtle pathologies that are difficult to control and whose differences from gingivitis and periodontitis we have learnt about.<sup>1</sup> According to studies on the prevalence of peri-implant disease,<sup>2</sup> 45% of patients show, after an average of nine years, signs of mild peri-implantitis and 14.5% medium to severe. In recent times, we have gained knowledge about oral biofilm, discovering that the biofilm changes in its characteristics when a pathology is established and that some pathologies, such as mucositis and peri-implantitis, are characterised by a repetitiveness in the type of pathogenic microorganisms present.<sup>3</sup> Implant maintenance protocols, however, have not evolved alongside knowledge, sometimes only introducing new instruments or technologies, such as laser therapy or phototherapy, and some new antiseptic principles.

### The concepts of periodontal and peri-implant eubiosis and dysbiosis

One of the key points for the long-term success of a patient rehabilitated with implants, which is no different from that of a patient treated for periodontal disease, is to establish a correct programme of supportive therapy and periodic follow-up that includes differentiated recalls based on an analysis of risk factors and consequent classification into risk categories. The literature and our decades of clinical experience have shown that patients with treated periodontal disease are at risk of having setbacks and developing a new disease process.<sup>4</sup> Thus, the implant patient or the periodontal therapy patient should not and must not be considered a patient who after treatment, however successful, can return to being normal and be low risk. Based on this scientific and clinical evidence, we can begin to plan the future of our therapies, starting with the biological basis of the problem and the new assump-



**CURASEPT**  
PREVENT

# AN EFFECTIVE PREVENTION against periodontal risk factors



Dental  
implants



Natural teeth  
treated for  
previous  
parodontosis



Diabetics  
Dry mouth



Smokers



Reduced  
immune  
defences


OZONATED OLIVE OIL, PVP/VA, COLOSTRUM AND STEVIA

B. LACTIS HN019 - MARXIANUS FRAGILIS - COLOSTRUM - BIOTIN

Curasept Prevent is an innovative line designed, **for daily use, to maintain a balanced oral microbiota**. It is ideal in the management of **prevention protocols of mucositis and peri-implantitis** when there are dental implants. Moreover it can be useful in the **prevention of gingivitis** in periodontal patients, with natural teeth, and in presence of **particular risk factors** that can facilitate the onset of oral diseases.







### SUPPORTIVE THERAPY CLINICAL CHECKLIST

Name and Surname \_\_\_\_\_ Date \_\_\_\_\_

RISK ASSESSMENT		FOLLOW-UP	
<input type="checkbox"/> STAGE I A	TYPE 0	<input type="checkbox"/> EVERY 2 MONTHS	<input type="checkbox"/> EVERY 4 MONTHS
<input type="checkbox"/> STAGE II B/C	TYPE 1	<input type="checkbox"/> EVERY 3 MONTHS	<input type="checkbox"/> EVERY 6 MONTHS
<input type="checkbox"/> STAGE III A	TYPE 2		
<input type="checkbox"/> STAGE IV B/C	TYPE 3		

CLINICAL CHECKLIST	
Full-mouth plaque score (FMPS) < 25%	<input type="checkbox"/> YES <input type="checkbox"/> NO
Full-mouth bleeding score (FMBS) < 25%	<input type="checkbox"/> YES <input type="checkbox"/> NO
Presence of periodontal pocket depth ≥ 5 mm	<input type="checkbox"/> YES <input type="checkbox"/> NO
Clinical signs of mucositis	<input type="checkbox"/> YES <input type="checkbox"/> NO
Clinical signs of peri-implantitis	<input type="checkbox"/> YES <input type="checkbox"/> NO
Tooth mobility	<input type="checkbox"/> YES <input type="checkbox"/> NO
Significant risk factor modification	<input type="checkbox"/> Better <input type="checkbox"/> Worse
Patient compliance	<input type="checkbox"/> Adequate <input type="checkbox"/> Not adequate
Is this follow-up frequency appropriate for the patient?	<input type="checkbox"/> YES <input type="checkbox"/> NO New follow-up frequency: _____

**Fig. 1:** Operational checklist for maintenance sessions.

tions linked to a more accurate knowledge of the oral microbiota.

The oral microbiota is the set of microorganisms that live and coexist in the oral cavity. It should be distinguished from the concept of oral microbiome, which is the collective genomes of the microorganisms present. The microbiota is made up of more than 700 different bacterial species, as well as numerous other microorganisms, and in a healthy state it is in perfect balance with the host, causing no harm and providing numerous benefits through the predigestion of food, antibacterial action, and the secretion of enzymes. This state of equilibrium is called “eubiosis”. It is important to emphasise that a eubiotic microbiota may also contain species that are considered pathogenic but which as part of a balanced biofilm are not capable of inducing pathology. Thus, the mere presence of periodontopathogenic species or implant pathogens is no longer considered a sign of pathology, as it was in the past; they can at most be considered risk factors to which more attention should be paid.

However, when a pathological process of either periodontitis or peri-implantitis occurs, the oral biofilm changes and a picture of dysbiosis<sup>5</sup> of the oral microbiota emerges, there being a change in the relationships between the present species and that can trigger an immune and inflammatory response. It is precisely the inflammation created by the bacterial trigger that feeds and often maintains the dysbiosis itself, leading to chronicity of the condition. This alteration in the balance leading to the onset of disease is affected by many variables or risk factors which can affect the patient's clinical situation at several levels.<sup>6</sup> There is a solid body of literature on the most important risk factors for periodontal disease, drawn from many clinical trials and a smaller number of longitudinal studies.<sup>7,8</sup> This has made it possible to identify some of these factors as being strongly correlated with periodontal disease and, at least regarding the current state of research, to suggest for others a correlation whose nature has yet to be validated in detail.<sup>9–14</sup>

Risk factors include some that are modifiable and others that are not. Among the most important modifiable factors are smoking, stress and diabetes, which we know cannot yet be eliminated but is treatable and therefore modifiable. Among the non-modifiable factors is genetic predisposition, a generic and imprecise term that refers to a host's ability to modulate the quality of the immune and inflammatory response differently and thus favour the onset of disease. Other risk indicators whose correlation with implant and periodontal disease has yet to be fully clarified include obesity, metabolic syndrome, hypertension, cardiovascular disease, and osteopenia/osteoporosis.

## A cooperative patient–professional plan

Once the biological bases currently considered valid for a more scientific and modern understanding of peri-implant pathologies have been clarified, other much more practical and organisational aspects of maintenance need to be investigated. First of all, not all patients are the same: the selection of a good candidate for periodontal treatment or implant therapy should always be made *a priori*, excluding those patients in whom the risk factors described, or even who display an unsuitable propensity and attitude regarding adhering to the practitioner's requests and prescriptions (patients defined as having a low degree of cooperation or compliance), are not considered satisfactory. Sometimes it is not possible to select only ideal candidates, and even these, in the course of their lives, may suffer a disease setback if not properly motivated and followed up. Although a number of periodontal and peri-implant risk assessment tools have existed for years to assist clinicians in setting up the most suitable maintenance programme possible,<sup>15,16</sup> there is no uniformity even among the most experienced




professionals.<sup>17</sup> Furthermore, the patient undergoing implant and periodontal rehabilitation often requires a guarantee of duration of treatment, a need which goes far beyond what medicine can offer but to which, nowadays, we cannot fail to provide a satisfactory answer.

The aim of this scientific contribution is to suggest a protocol, the implant protection plan (IPP), that establishes a therapeutic alliance between the treating dentist, the dental hygienist and the patient at the end of the active phase of periodontal or implant therapy. The IPP protocol provides for a shared maintenance pathway which starts with the initial assessment of the patient and periodic re-evaluations, which are not an end in themselves or a mere collection of clinical data, but determine actions and changes in the dental professional's attitude or that of the patient in order to optimise the periodontal and implant prognosis. The patient himself or herself should feel involved in the IPP, share its purpose and not play a passive role (Figs. 1 & 2).

The protocol also includes an operational checklist with all the factors that the hygienist has to check during the session. This tool is designed to monitor the clinical situation and alert the dental practitioner to any worsening of the patient's clinical condition compared with the baseline and to make consequent adjustments to the current supportive therapy (e.g. shortening recall times; Fig. 3).

The true innovation is to ensure that the patient does not have to give up compliance because, in return for a personalised maintenance programme set out in a contract signed by both parties, he or she will be guaranteed specific treatments or interventions, such as prosthetic replacement treatments, without any financial cost should any biological problems occur, but only if he or she has complied with the maintenance sessions agreed with him or her beforehand.

The first step in implementing the protocol is to assign a periodontal or peri-implant risk profile. The dentist determines a specific risk class on the basis of systemic and local risk factors, the presence or absence of implants (patient with only natural teeth, patient with natural teeth and implants, or patient with only implants) in order to plan the frequency and manner of individualised maintenance therapy. The assessment of the risk profile is therefore divided into a periodontal profile, if the patient still has natural teeth, and a periodontal framework in order to combine the two classifications into a single patient risk class assignment. Assigning a prognostic risk for a patient who has a partial natural dentition is a process that requires cross-referencing anamnestic information and elements from the objective examination and interpreting this data through prognostic assessment. It is necessary to include in the


  
 implant protection plan

**THERAPEUTIC ALLIANCE**  
**IMPLANT/PERIODONTAL SUPPORTIVE THERAPY PLANNING**

Name and Surname \_\_\_\_\_
Date \_\_\_\_\_

INITIAL ASSESSMENT		
RISK CATEGORY		
<input type="checkbox"/> STAGE I A	II A	TYPE 0
<input type="checkbox"/> STAGE I B/C	II B/C	TYPE 1
<input type="checkbox"/> STAGE III A	IV A	TYPE 2
<input type="checkbox"/> STAGE III B/C	IV B/C	TYPE 3

FOLLOW-UP	PATIENT COMPLIANCE
TYPE 0 <input type="checkbox"/> 6 months <input type="checkbox"/> 4 months	<input type="checkbox"/> Medium/High <input type="checkbox"/> Low
TYPE 1 <input type="checkbox"/> 4 months <input type="checkbox"/> 6 months	<input type="checkbox"/> Low <input type="checkbox"/> Medium <input type="checkbox"/> High
TYPE 2 <input type="checkbox"/> 3 months <input type="checkbox"/> 4 months	<input type="checkbox"/> Low <input type="checkbox"/> Medium <input type="checkbox"/> High
TYPE 3 <input type="checkbox"/> 2 months <input type="checkbox"/> 3 months	<input type="checkbox"/> Low <input type="checkbox"/> Medium <input type="checkbox"/> High

1-YEAR ASSESSMENT		
RISK CATEGORY		
<input type="checkbox"/> STAGE I A	II A	TYPE 0
<input type="checkbox"/> STAGE I B/C	II B/C	TYPE 1
<input type="checkbox"/> STAGE III A	IV A	TYPE 2
<input type="checkbox"/> STAGE III B/C	IV B/C	TYPE 3

FOLLOW-UP	PATIENT COMPLIANCE
TYPE 0 <input type="checkbox"/> 6 months <input type="checkbox"/> 4 months	<input type="checkbox"/> Medium/High <input type="checkbox"/> Low
TYPE 1 <input type="checkbox"/> 4 months <input type="checkbox"/> 6 months	<input type="checkbox"/> Low <input type="checkbox"/> Medium <input type="checkbox"/> High
TYPE 2 <input type="checkbox"/> 3 months <input type="checkbox"/> 4 months	<input type="checkbox"/> Low <input type="checkbox"/> Medium <input type="checkbox"/> High
TYPE 3 <input type="checkbox"/> 2 months <input type="checkbox"/> 3 months	<input type="checkbox"/> Low <input type="checkbox"/> Medium <input type="checkbox"/> High


**2**

**Fig.2:** Programming of periodontal and implant maintenance sessions.

analysis the patient's medical and dental history, oral and extra-oral radiographs and the main periodontal variables (plaque index, bleeding on probing, probing depth, recessions, furcation involvement, pathological tooth mobility, bone profile) and to give the patient the correct periodontal disease diagnosis (in terms of stage and grade).<sup>18</sup>

Today, there are several tools and algorithms that help us to plan the correct timing of maintenance sessions and, indirectly, to predict the patient's prognosis. It should also be pointed out that some of these collected variables, besides having a greater relative weight (odds ratio) than others in influencing prognosis, offer more information as indicators of disease progression. The most important of these are smoking, diabetes and a history of periodontitis.

In a recent review of the scientific evidence supporting periodontal maintenance planning, the following was emphasised:<sup>19</sup>



**THERAPEUTIC ALLIANCE**  
**FIRST VISIT: RISK ASSESSMENT**

Name and Surname \_\_\_\_\_ Date \_\_\_\_\_

### IMPLANT EVALUATION

TYPE 0 PATIENT <input type="checkbox"/>	TYPE 1 PATIENT <input type="checkbox"/>	TYPE 2 PATIENT <input type="checkbox"/>	TYPE 3 PATIENT <input type="checkbox"/>
Implant patient • Absence of tooth loss due to periodontitis • No risk factors	Implant patient • Absence of tooth loss due to periodontitis • Risk factors: <input type="checkbox"/> Smoking <input type="checkbox"/> Stress <input type="checkbox"/> Diabetes <input type="checkbox"/> Other _____	Implant patient • History of tooth loss due to periodontitis • No risk factors	Implant patient • History of tooth loss due to periodontitis • Risk factors: <input type="checkbox"/> Smoking <input type="checkbox"/> Stress <input type="checkbox"/> Diabetes <input type="checkbox"/> Other _____

### PERIODONTAL EVALUATION

NOT TO BE FILLED IN FOR EDENTULOUS PATIENTS

FRAMEWORK FOR STAGING: ☐ I ☐ II ☐ III ☐ IV

	STAGE I	STAGE II	STAGE III	STAGE IV
INTERDENTAL CAL* AT SITE OF GREATEST LOSS	1-2 mm	3-4 mm	≥ 5 mm	≥ 5 mm
RADIOGRAPHIC BONE LOSS	Coronal third (> 15%)	Coronal third (15-33%)	Extending to the middle third of the root or beyond	Extending to the middle third of the root or beyond
PERIODONTITIS ASSOCIATED TOOTH LOSS	No tooth loss from periodontitis	No tooth loss from periodontitis	Tooth loss from periodontitis ≤ 4 teeth	Tooth loss from periodontitis ≥ 5 teeth

\*Clinical Attachment Loss

FRAMEWORK FOR GRADING: ☐ A ☐ B ☐ C

		GRADE A	GRADE B	GRADE C		
PRIMARY CRITERIA	Direct evidence of progression	Evidence of no loss over 5 years	< 2 mm over 5 years	≥ 2 mm over 5 years		
	Indirect evidence of progression	Longitudinal data (radiographic bone loss or attachment loss)	Percent bone loss/age	< 0.25	0.25 - 1.00	> 1.00
		Case phenotype	Heavy biofilm deposits with low level of destruction	Destruction commensurate with biofilm deposits	Destruction disproportionate to biofilm deposits	
GRADE MODIFIERS	Risk Factors	Smoking	Non-smoker	< 10 cigarettes/day	≥ 10 cigarettes/day	
		Diabetes	Normoglycaemic with or without prior diagnosis of diabetes	HbA <sub>1c</sub> < 7.0% in diabetes patient	HbA <sub>1c</sub> ≥ 7.0% in diabetes patient	

**Fig. 3:** Assignment of risk class.

1) In healthy patients or those with mild forms of periodontal disease, stable clinical conditions can be maintained with six-monthly recalls. In patients with medium and severe forms of periodontal disease, the scientific evidence suggests a maintenance protocol with a greater frequency, varying in the literature from two to four months.

2) Data from retrospective studies shows that the proportion of residual affected sites (residual periodontal pockets with bleeding on probing) is an important variable in planning the frequency of visits. The efforts of health professionals should aim precisely at reducing these sites with disease both during the active phase of therapy and during supportive therapy.

Less prolific in the literature are systematic reviews and longitudinal studies on implant patient retention and prevention of peri-implantitis. However, as peri-implantitis shares many risk factors with periodontal disease, it is intuitive that implant patient maintenance planning

will also have many common variables to consider.<sup>20-22</sup> However, the key to the prevention of peri-implantitis lies in the prevention of peri-implant mucositis. As reported by Jepsen et al., control of modifiable risk factors—smoking and bleeding on probing of residual dentition—is crucial in controlling mucositis.<sup>23</sup> Monje et al. in a meta-analysis on the impact of maintenance in the prevention of peri-implantitis emphasise the critical role of a history of periodontal disease as modifying the incidence of mucositis and peri-implantitis.<sup>24</sup> Numerous works identify plaque control, bleeding on probing, smoking and diabetes as the most important biological variables to consider.<sup>25,26</sup>

Having to classify, not a random sample of patients, but a subcategory (patients with previous periodontal disease and patients with implant restorations) with a higher intrinsic risk,<sup>4</sup> we decided to maximise the importance of the above-mentioned variables, set very strict cut-off values and establish rather tight recall intervals. Patients are thus divided into four classes of increasing risk, which are re-evaluated by the treatment team on a yearly basis with total transparency and in dialogue with the patient.

It is much more effective to plan this phase for the duration of one year (12 months from the date of initial planning), as achieving good compliance and correct use of home oral hygiene instruments often requires several months and several professional recall sessions, during which time positive reinforcement by the hygienist and dentist will contribute to progressive improvement. The patient himself or herself is actively involved in this decision-making phase, promptly informed of his or her risk status and encouraged to excel in protecting the investment he or she has made during the active phase of therapy.

The patient is motivated to scrupulously follow the instructions of the hygienist, who has the authority to suggest to the dentist after an observation period of one year a different maintenance protocol according to the degree of compliance demonstrated by the patient and the clinical results obtained. This patient-hygienist synergy has a twofold objective: it raises the status of the hygienist, who, in the eyes of the patient, becomes a professional figure empowered to propose a different treatment plan to the dentist; and it motivates the patient to follow the hygienist's therapeutic indications, which, if put into practice, will save the patient both time, because by spacing out the recalls the patient will come to the practice fewer times, and economic resources, since reducing the maintenance sessions will reduce the costs. The tangible saving of time and money is an important motivating factor for most, if not all, patients and is far more motivating than a generic invitation to follow clinical indications, which are often under-estimated and experienced by the patient as an imposition.

The universe at your fingertips.

# ● LightWalker

## The highest technology dental laser system

### Supreme clinical results:


- TwinLight® Perio Treatments
- TwinLight® Endo Treatments
- No-sutures soft-tissue surgery
- Patient-friendly conservative dentistry
- Pre-sets for over 40 applications

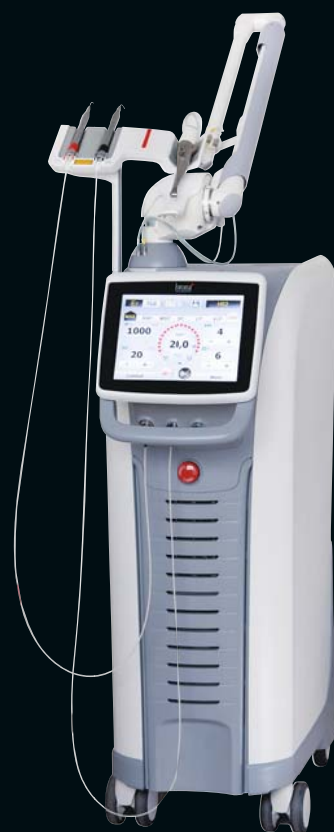### Unmatched simplicity of use:

- Balanced and weightless OPTOflex® arm
- Nd:YAG handpiece detection system
- Quantum Square Pulse technology for fast minimally invasive treatments
- X-Runner™ - the first digitally controlled Er:YAG dental laser handpiece

Visit [www.fotona.com](http://www.fotona.com) to find out more!



 Fotona App



Finally, the IPP protocol is an important instrument of patient loyalty and involvement, similar to other contracts that patients sign every time they buy tangible goods and want to protect an investment. In this specific case, the patient protects his or her own oral health, which, as we know, also has repercussions for systemic health,<sup>27,28</sup> an aspect that is increasingly clear from the literature and becomes a motivational lever

“The therapeutic alliance involving the dentist, the dental hygienist and the patient is the cornerstone of long-term success ...”

for patients to take care of their restorations. As mentioned, patients increasingly demand a form of guarantee for the professional service in which they have invested time and financial resources. It is universally accepted, including by legislation, that in many areas of medicine we cannot offer absolute guarantees similar to the purchase of material goods. The IPP protocol represents, in our opinion and experience, a realistic and professional response to patients' demands for a guarantee that does not increase the risk of free prosthetic remakes because, by reviewing patients according to a tight and individually modulated recall schedule, mucositis can be intercepted and treated effectively before it becomes peri-implantitis.

The protocol also allows the practitioner to have a powerful communication weapon should a clinical problem occur in patients who have refused the IPP. In this regard, it is advisable to write down any refusal in the medical record and have it countersigned by the patient. Clinical experience over the past 40 years has shown us that patients usually lose track of time and think that they have been out of treatment for a few years when in reality many more years have passed and the patient has never shown up for his or her scheduled appointments. Having recorded even the non-acceptance of the PPI protocol allows the practitioner to demonstrate his or her diligence and protects him or her from possible medicolegal proceedings that patient appear increasingly willing to bring in the event of failure. We are convinced that, by protecting the patient from biological problems that may occur, we are fulfilling our professional duty in an ethical manner and protecting ourselves by demonstrating our competence and diligence.

## Conclusion

The aim of establishing the IPP protocol is to help the dental team to assign a future risk profile designed specifically for the periodontal and implant therapy, not neglecting the many variables that contribute to the prognostic assessment but giving maximum emphasis to those that evidence suggests are the most relevant. The therapeutic alliance involving the dentist, the dental hygienist and the patient is the cornerstone of long-term success, there being a continuous flow of communication between the parties and periodic feedback to recalibrate the most appropriate times and methods for continuing to maintain health.

In its essence, the IPP protocol represents a modern and innovative approach to the patient that is aimed at: (1) effectively motivating the patient, who perceives real and tangible benefits; (2) building patient loyalty, because the practitioner offers protection that many other practitioners do not offer, thinking it too risky for the practice; (3) raising the professional profile of the hygienist, who becomes a key player in maintaining the results achieved by the dentist through treatment; and (4) protecting the dental practitioner from possible medicolegal proceedings, especially in those patients with inconsistent compliance.



## about the author



**Dr Tiziano Testori** is head of the implant dentistry and oral rehabilitation section of the IRCCS Galeazzi Institute in Milan in Italy. He is an adjunct professor in the Department of Biomedical, Surgical and Dental Sciences of the University of Milan and an adjunct clinical assistant professor in the Department of Periodontics and Oral Medicine at the University of Michigan School of Dentistry in Ann Arbor in the US. He obtained his MD in 1981, his DDS in 1984 and a specialty qualification in orthodontics from the University of Milan in 1986.

## contact

**Dr Tiziano Testori**  
ttestori@umich.edu



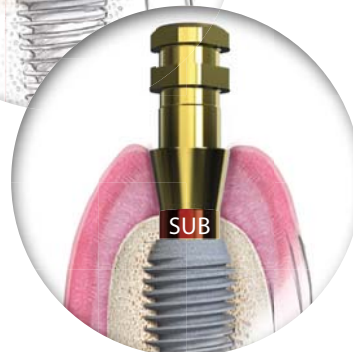
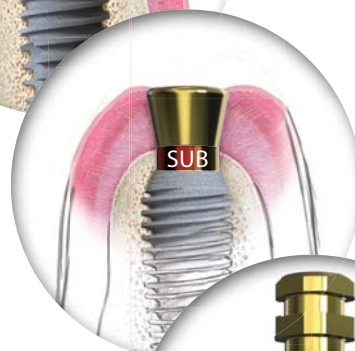
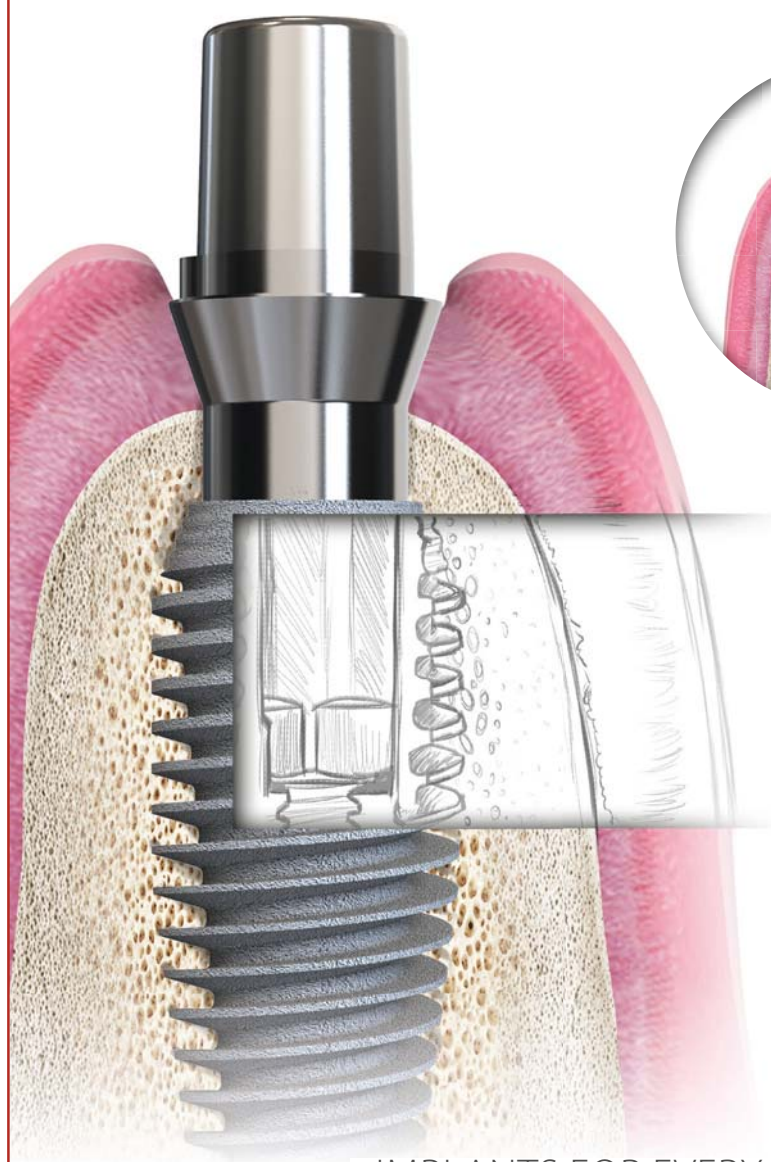
*we are creating*  
**STABLE TISSUE**



## THE SUBCRESTAL IMPLANT SYSTEM FOR BIOLOGICAL LONG-TERM STABILITY



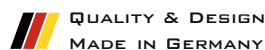Form-fit and force-fit 1.5° long taper for bacterial tightness  
and beveled shoulder for superior esthetics



New and (r)evolutionary -  
2 millimeter subcrestal  
insertion possible



IMPLANTS FOR EVERY INDICATION



**ARGON** Medical  
Tel.: 49+ (0)6721/ 3096-0  
info@argon-medical.com  
www.argon-medical.com



# The role of metallic nano- and microparticles in peri-implantitis

Dr Ioannis Papadimitriou, Germany

**Dental implantology** has become a fundamental component of oral rehabilitation and is closely associated with prosthetic therapy. The aim of both implantology and prosthetics is to replace a lost natural tooth and to achieve *restitutio ad integrum*. To attain this goal, attempts have been made with different materials and techniques for many centuries. In the last few decades, metal implants in particular have established themselves extremely successfully as an alternative to purely prosthetic therapies; however, the extent to which these may have a negative impact on the organism and the reasons for which they can lead to inflammatory reactions must be examined more closely.<sup>1,2</sup>

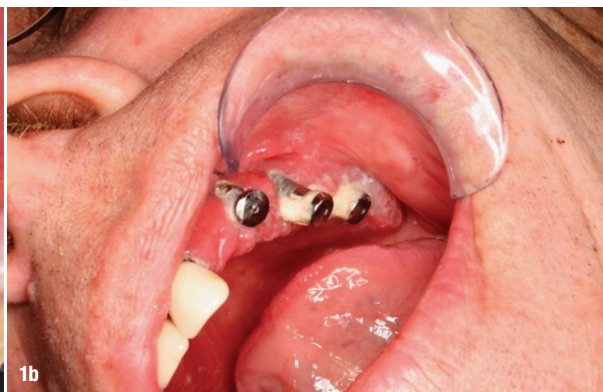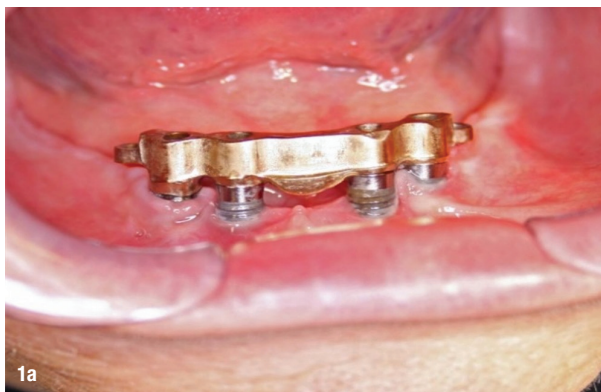In the middle of the twentieth century, Brånemark's Gothenburg research group first researched the biocompatibility of different materials with bone and has since triggered an uninterrupted upswing in dental implantology. It was found that implants made of pure titanium have the ability to heal in the bone without any signs of inflammation or rejection. Brånemark defined this process as osseointegration, which includes all elements of biocompatibility, a bio-inert material and bioactivity.<sup>1,3</sup> The term "biocompatibility" defines materials that have no negative effects on living organisms. This is extremely important with implants, as they remain in the living tissue for a long time. Implant materials must also be bio-inert, which means that no toxic substances may be released from them over time. Bioactivity involves the creation of a chemical bond between the implant and the surrounding tissue.<sup>1,3</sup> Since Brånemark was able to demonstrate these properties of pure titanium, it is now the material of first

choice for implants. An alternative to pure titanium is zirconium dioxide, which also has very good biocompatible properties. In addition, in medicine, other metals, metal alloys, polymers and ceramics are used as biocompatible materials.<sup>1,3</sup> Bone deposition on the titanium implant surface, important for osseointegration, was also confirmed in many studies. Primary stability is achieved through mechanical blocking.

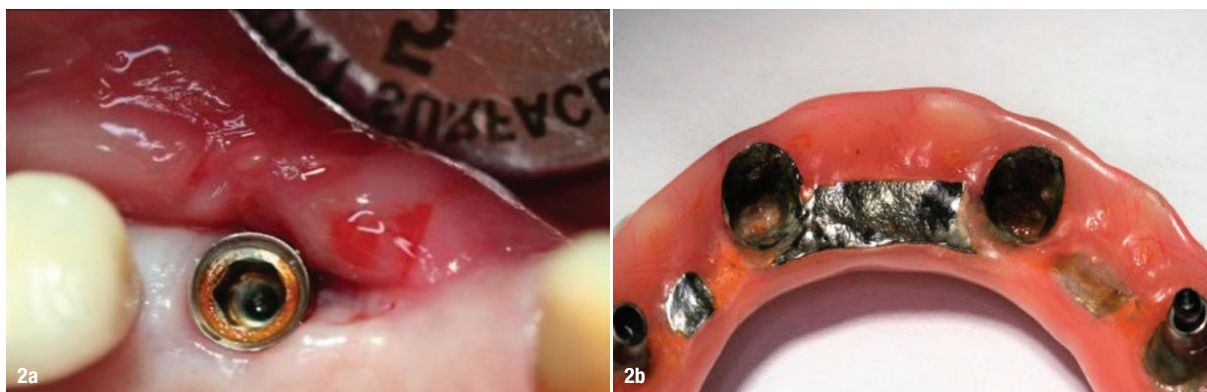
While natural teeth develop simultaneously with periodontal tissue to form a functional unit, endosteal implants, being artificial, are made of inorganic material, for which no artificial periodontium has yet been found. This constitutes a weak point regarding later peri-implant inflammation.<sup>4,5</sup> The morphological differences between a natural tooth and a titanium implant cause implants to be more prone to inflammation.<sup>32</sup> Overall, metals have good mechanical properties, but their susceptibility to corrosion and their possible release of metal ions and consequently the sensitisation of the organism represent disadvantages. Therefore, collar-shaped stable soft tissue around the implant protruding into the oral cavity is essential for long-term success of an implant, including the prosthetic restoration. The healing processes after implantation can only start from a vital bone.<sup>6,7</sup>

## Periodontitis and peri-implantitis

Biofilm is mandatory for the development of periodontitis. The bacteria from this infiltrate the periodontal tissue, resulting in inflammatory reactions and subsequent irreversible tissue damage. Risk factors such as nicotine and



**Figs. 1a & b:** Clinical peri-implantitis.



**Figs. 2a & b:** Corrosion on implants and the superstructure. Corrosion of the implant–abutment connection **(a)**. Corrosion of the overdenture prosthesis **(b)**.<sup>33</sup>

alcohol abuse, as well as systemic disease (e.g. diabetes mellitus) or even stress, amplify the bacteria migration into the tissue.<sup>6</sup> Peri-implantitis is progressive peri-implant bone loss with simultaneously inflammable and inflamed soft tissue. Bacterial infection and biomechanical overload are considered to be its triggers. Clinically and radiographically recognisable destruction is the result, since the bone is more easily exposed to the inflammatory infiltrate without a protective periodontal ligament. Since peri-implantitis is clinically and microbiologically similar to chronic marginal periodontitis, it is concluded that plaque can cause peri-implant disease. However, it still remains to be clarified whether a predisposition to periodontal disease also favours peri-implant inflammation. Nevertheless, it is recommended that alternative therapies to intraosseous implants should be preferred in patients with an increased susceptibility to periodontal disease.<sup>6,8,9–14</sup> At the 2017 World Workshop on the Classification of Periodontal and Peri-Implant Diseases and Conditions, peri-implantitis was defined as “a plaque-associated pathological condition occurring in tissues around dental implants, characterised by inflammation in the peri-implant mucosa and subsequent progressive loss of supporting bone”. This definition does not take factors such as metal particles or the cytotoxicity of metals into consideration.


Clinical cases of pronounced peri-implantitis are documented in Figures 1a & b. The purulent secretion from the peri-implant pockets is noticeable. The soft-tissue cuff is no longer present, and the loss of bone can be guessed. There is scientific consensus that periodontitis or peri-implantitis is caused by excessive bacterial colonisation of the gingiva caused by inadequate dental and oral hygiene. It has been shown that progressive periodontitis occurs more often in families. Although its origin is multifactorial, genetic predisposition is important because some genes have been isolated as risk factors, including the interleukin 1 gene, proteinase 3 and cathepsin.<sup>15,16</sup> Nanoparticles that gain access to the bone compartment during implantation through the surgical instruments themselves and through the implant insertion are increasingly being researched as a cause and a trigger of peri-implantitis.

However, there is still no clearly defined standard or protocol for the treatment of peri-implantitis. Owing to the very high recurrence rate of peri-implantitis after one year despite therapeutic intervention (surgical or non-surgical), the question now arises of whether metal abrasion particles from the implant surfaces maintain peri-implantitis. No studies have compared non-surgical measures with surgical measures.<sup>2,17,18</sup>

## Nanoparticles

In the last 20 years, nanotechnology has experienced a great boom. Particles below 100nm are referred to as nanoparticles. They are produced industrially, but also occur naturally (for example viruses and in volcanic ash and forest fires). They are characterised by their extremely large surface in relation to their low mass. Nanoparticles are mainly made from silicates and various metal oxides, including titanium and aluminium oxides. They can be found, for example, in candies and in many skin care products, especially sunscreens. Titanium dioxide particles and zinc oxide are used as stabilisers. It was found that orally ingested titanium dioxide particles are deposited in the intestine and in other tissue (peritoneal tissue, liver, spleen, kidney and heart) without being excreted, causing epithelial disorders, and chronic damage of the intestinal cells can be triggered. In the case of intact skin, evidence of titanium dioxide can only be detected in the top layer of the epidermal layer.<sup>19</sup> Nanoparticles are also used in medicine. Owing to its higher efficiency and accuracy, nanoparticle-based fluorescent marking is indispensable in diagnostics and imaging. The use of nanoparticles in pharmaceuticals has shown that they have better bioavailability and effectiveness, fewer side effects and, above all, reduced organ toxicity.<sup>20</sup> Because of these positive and negative aspects, the question arises as to whether nano- or microparticles from implants or metallic instruments lead to an increased risk of peri-implantitis during implantation. Very little is known about the risks and translocation of titanium dioxide nanoparticles from implants or metallic instruments. The existing literature from 2010 onwards should be examined for references





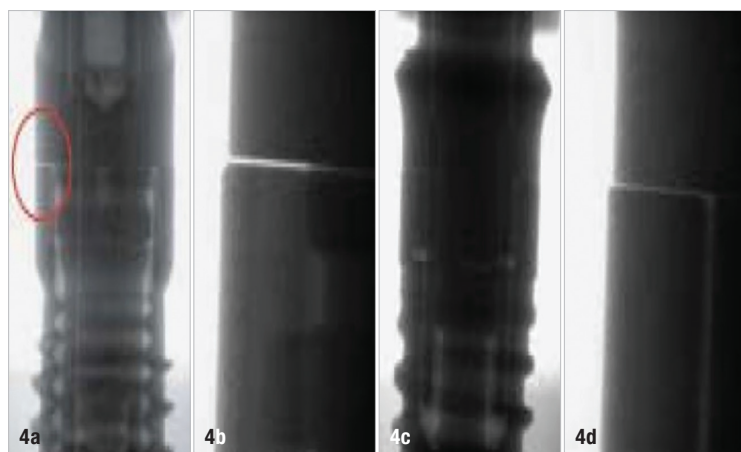
**Figs. 3a–d:** SEM images of the effect of *Streptococcus sanguinis* on the titanium surface. Titanium surface in artificial saliva enriched with *S. sanguinis*. Scale: 100  $\mu\text{m}$  (a) and without *S. sanguinis*. Scale: 100  $\mu\text{m}$  (b). Enlarged view of Figure 3a (the arrows show *S. sanguinis*). Scale: 10  $\mu\text{m}$  (c). Enlarged view of Figure 3c. Scale: 5  $\mu\text{m}$ .<sup>24</sup> (d).

to this, because the aspects of particle formation during implantation have been investigated in more detail only in the recent last few years.

### Titanium properties

The grey colour of titanium is caused by the oxide layer that forms on the surface immediately after the metal comes into contact with oxygen and is 2–5 nm thick. This normally very dense and chemically stable oxide layer gives titanium its biocompatibility and mediates osseointegration

by allowing cellular adhesion molecules to accumulate. In some cases, however, different types of corrosion can be observed clinically: pitting, crevice and stress corrosion, and erosion (Figs. 2a & b).<sup>7,21,22</sup> Pitting corrosion occurs primarily and predominantly at the connection point between the implant and the abutment, which can cause crevice corrosion. As a result, a concentration of chloride ions is created, which lowers the pH in the immediate vicinity of the implant. Thus, the oxide layer on the titanium implant dissolves irreparably and cannot renew itself due to *Streptococcus sanguinis*. These bacteria form a barrier to oxygen through a biofilm formed around the implant; owing to the lack of oxygen, titanium ions and particles are released from the complex titanium structure. On the one hand, this inflames the tissue, and on the other hand, the titanium implant continues to corrode. The saliva, which can act as an electrolyte, also contributes to the permanent damage to the oxide layer because the corrosion is supported by electrochemical processes in the mouth.<sup>23,24</sup> The extent of damage to the implant surface, which is significant, is shown in Figures 3a–d.<sup>24</sup> In addition, Nakagawa et al. found in a further study that pure titanium and titanium alloys corrode faster owing to the influence of fluorides at a low oxygen content, whereas without fluoride they showed a higher corrosion resistance at the same oxygen concentration.<sup>25</sup> For this, the fluoride concentration in commercially available toothpastes was considered, which turned out to be too high and does not protect the metals from corrosion damage.<sup>25</sup>



**Figs. 4a–d:** Detailed images of two implant–abutment connections under masticatory load.<sup>31</sup>





# ALL-IN-ONE WEEK Curriculum 2021

*The fast way to successful implantology –  
Immediate loading **WITHOUT** bone augmentation!*



## BELGRADE

During the one-week crash course with **Prof. Dr. Stefan Ihde** in BELGRADE (Serbia) you will gain **extensive theoretical knowledge about the technology of the Strategic Implant®** and you will also have the opportunity to watch and assist in live operations (approx. 1.5 days), as well as to get to know the subsequent prosthetic procedures.

All lectures are given in English. With a minimum of eight participants, the course is also held in other languages.



Learn the essentials about implant restoration with the Strategic Implant® in immediate loading in **ONLY ONE WEEK**

- Implantation overview up to the final prosthetic restoration
- Organizational, medical and technical information
- Care of many cases with minimal bone supply
- Treatments directly to patients, live surgery
- **Immediate loading without bone augmentation**

Find out now about the next course dates in Belgrade

**contact@implantfoundation.org**  
**www.implantfoundation.org**



The Foundation of Knowledge

## Metal abrasion during insertion and its consequences


The original implant surface and shape can be modified by the insertion procedure. A very deep insertion causes greater damage to the bone and implant than a less forced insertion. By torsion and friction of the implant on the bone, titanium particles are released from the surface structure of the implant into the already damaged bone tissue. The size of the released titanium particles varies between 10 nm and 20 µm. At the sharp edges of the implant, the entire oxide layer is partially lost as a result of the insertion. The loss of the oxide layer also depends on the type of implant.<sup>26–28</sup> Martini et al. showed that implants coated with fluoro-hydroxyapatite were less susceptible to abrasion during insertion than plasma-coated implants. Titanium particles released by plasma-coated implants were found at a distance of 200–250 µm from the implant surface and prevented neo-osteogenesis. A deformation of the implant thread can be seen in the area of the bone, especially in the form of microfractures. Titanium abrasion can be found both in the peri-implant mucosa and in the newly formed bone. Titanium particles have even been detected in organs further away: the liver, kidneys, lungs and heart.<sup>29,30</sup> In addition to the implant insertion, the high mechanical loads on the connection between the implant and the abutment are another factor that contributes to the release of metallic particles. Complete implant failure can also occur as a result. In addition, micro-gaps can form at the implant–abutment connection, where titanium and metal particles can also loosen. Microleakage, material wear, material fatigue and screw loosening are other possible consequences that can result from the micro-gaps. Microleakage is particularly evident in hexagonal connections with a loose fit (Figs. 4a–d) through which—in addition to metal abrasion and material damage—liquids and bacteria gain entry to the interior of the implant and cause internal corrosion of the implant. The microgap movements can be reduced by a conical connection between the implant and the abutment.<sup>31</sup>

## Conclusion

At the beginning of the implantology era, the focus was on the euphoria about solving the problem of osseointegration, but in recent years, the question of the reasons for a shortened lifetime of implants has moved increasingly into focus. Peri-implantitis, which sometimes turns out to be therapy-resistant, was seen as a further indication that, in addition to a *lege artis* insertion, factors that lay the foundation for peri-implantitis during insertion can be responsible for achieving osseointegration. Nano- and microscale titanium and zirconium dioxide particles detach themselves from both the instruments and the implants during insertion and the surgical, prosthetic and aftercare phases. They can be detected in bone and

other tissue and have only recently been shown to be cytotoxic. According to the current research, the release of these particles cannot yet be prevented regardless of the implant surface. The metal and titanium ions and particles dispersed into the peri-implant hard and soft tissue trigger cellular reactions that can be compared to aseptic chronic inflammation. This can lead to therapy-resistant peri-implantitis and thus to failed osseointegration.

Although these clinically and radiographically visible peri-implant changes are very similar to periodontitis, peri-implantitis is not always bacterial. For this reason, the classic treatment concept for periodontitis cannot generally be transferred to peri-implantitis. A concept for the treatment of peri-implantitis that is not caused by bacteria is not yet available. Particle-induced peri-implantitis is often accompanied by osteolysis, which is clearly not considered to be bacterial. In such cases, explantation with thorough lavage of the bone cavity is necessary. Further investigations are required to determine whether and to what extent bone regeneration measures need to be taken. Overall, however, the prevailing opinion is that metallic nano- and microparticles are of no importance in dental implantology. For this reason, the 2017 World Workshop on the Classification of Periodontal and Peri-Implant Diseases and Conditions defined peri-implantitis without including factors such as metal particles and their cytotoxicity. However, it is expressly advised that further research regarding metallic nanoparticles is absolutely necessary owing to their potential danger.



## about the author



**Dr Ioannis Papadimitriou** specialised in oral surgery and holds an MSc in oral implantology and periodontics from the German Association of Oral Implantology and the Steinbeis University in Berlin in Germany. He is a senior physician at the department of oral and maxillofacial surgery at the St Lukas hospital in Solingen in Germany.

## contact

**Dr Ioannis Papadimitriou**

giannis.papadimitriou\_4@hotmail.com

Our dental implants have  
an outstanding survival rate

98%

With maintained marginal  
bone after 5 years

0.3 mm



Stronger  
than ever.  
Thanks to  
science.

After 30 years of research and more than 1,000 scientific publications, we can confidently say that Astra Tech Implant System® EV delivers life-long function and natural esthetics.

Thanks to science, our implants have an outstanding survival rate and a marginal bone maintenance far better than the industry standard.

If you are looking for endless possibilities and superior outcomes, this is the only system you need. Today and tomorrow.

Follow Dentsply Sirona Implants  
for the latest in implant dentistry



[dentsplysirona.com/implants](https://dentsplysirona.com/implants)





# The Stable Tissue Concept

Dr Kai Zwanzig, Germany

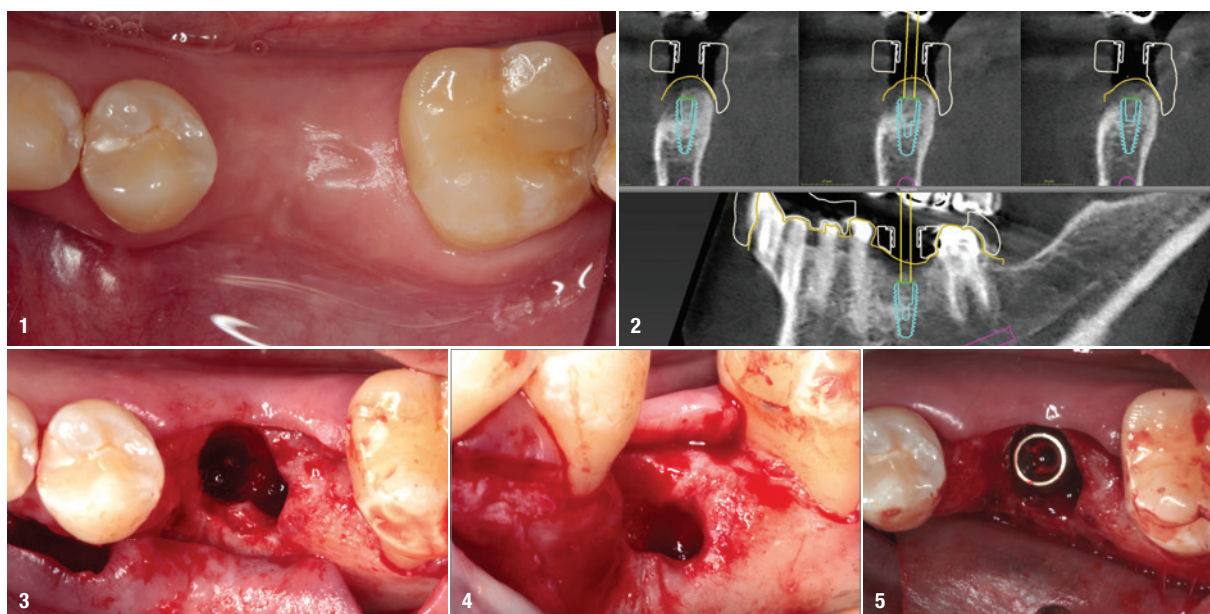
**In order to achieve long-term stable results**, it is important not to disregard biological principles. Bone and soft-tissue management should be an integral part of the portfolio of implantologists, since stable tissue is the basic prerequisite for implantological success. To this end, hard- and soft-tissue augmentation must be performed with materials adapted to the situation and indication. Another important factor is the choice of the implant system, because this can also be decisive for whether the bone level is maintained. Conical internal connections are therefore recommended, as they ensure the necessary stability of the abutment. Many reasons for bone resorption around implants are described in the literature. Firstly, implants are often screwed into bone that is too thin; a circumferential bony layer of at least 2 mm is required to keep an implant stable.<sup>1</sup> In addition, two-piece implant systems usually have the disadvantage that the abutment has some mobility. Twenty years ago, Hermann et al. were able to prove that it is not the gap between the implant components that induces bone resorption, but that this process is caused by micro-movements between the implant and abutment.<sup>2</sup> It is therefore important to select an implant system that completely eliminates these micro-movements. Numerous studies show that implant systems with tapered internal connections can avoid such movements.<sup>3</sup> However, there are also major differences between

these implant systems. Systems with self-locking tapered connections show the least movement between implant and abutment, and that is particularly the case for the Morse taper connection.<sup>4</sup> The Morse taper was developed to secure tool components in the spindle of a tool. It is characterised by a taper angle of a maximum of 1.5°, transmitting the torque from the hollow cone of the operating tool spindle to the shaft of the tool, which is clamped in it, in a friction-fit manner by static friction as a result of self-locking.

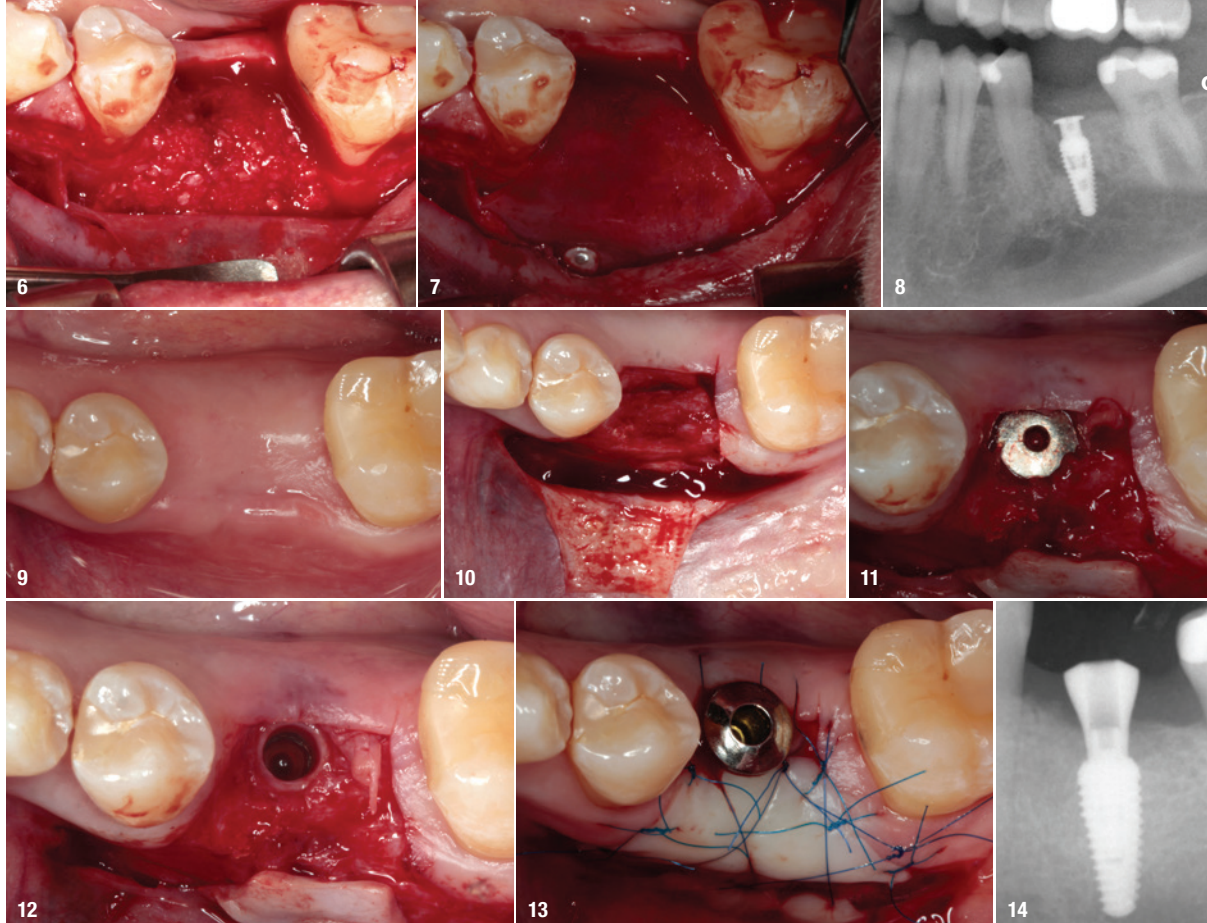
The implant system (K3Pro, Argon Dental) used in the following case has such an internal connection. These implants do not show any gap formation in radiographic analysis, even at the maximum load of 200N, and do not exhibit any micro-movements. In this case report, a clinical procedure according to the Stable Tissue Concept is described.

## Clinical case

The patient visited the practice in 2016 after the removal of tooth #36 elsewhere to have the gap restored with a dental implant (Fig. 1). A bone defect was visible on the preoperative radiographic image (Fig. 2). After elevation of a mucoperiosteal flap and careful curettage of the surgical site, it became obvious that augmentation was required

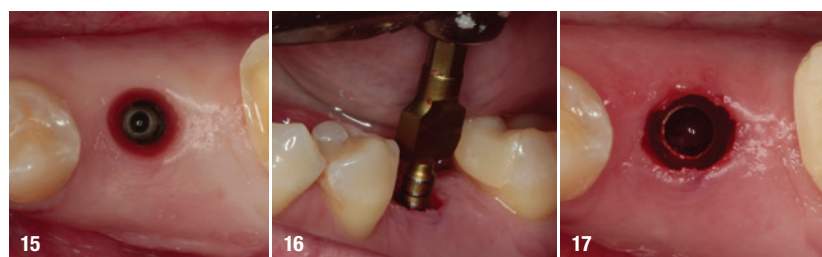

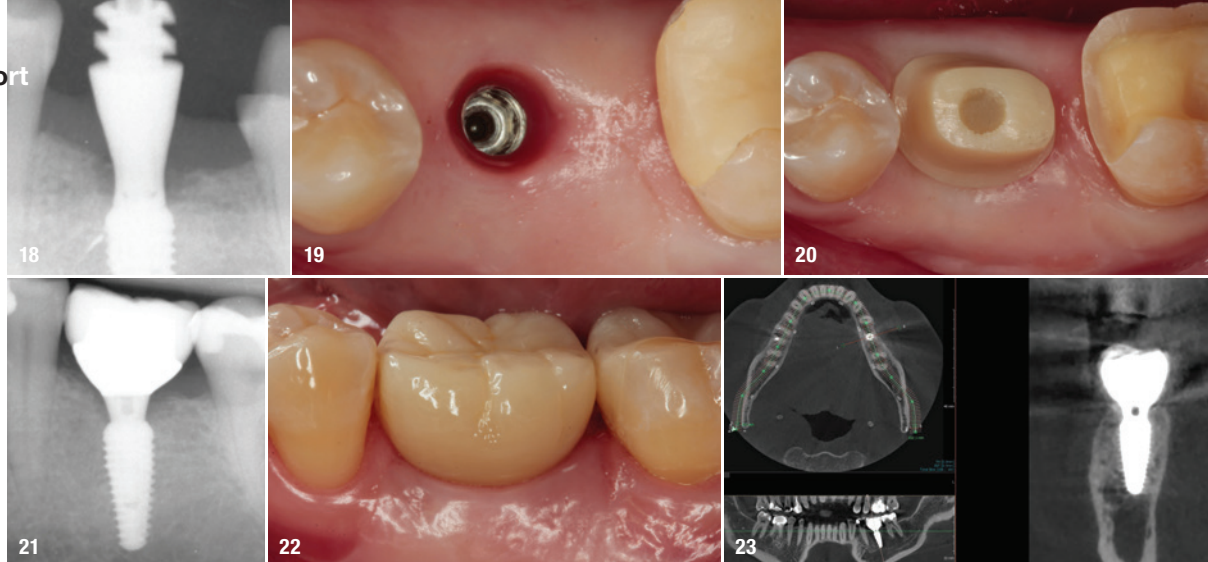




(Figs. 3 & 4). Despite the spectacular-looking defect, it was quite easy to augment. It was a multi-walled defect confined mesially and distally by two teeth that maintained the bone volume. The regeneration potential was therefore very high and favoured a prognosis of success. An implant was placed with high primary stability (Fig. 5). The author prefers bone grafting materials that resorb entirely and are converted into natural bone. Allogeneic bone has precisely these desired properties. The grafting material used here (Osteograft, Argon Dental) was human donor bone prepared by the German Institute for Cell and Tissue Replacement. The grafting material was prepared in PRGF (plasma rich in growth factors) matrix (BTI) to obtain so-called sticky bone.<sup>5</sup> Embedded in this clot, the particulate material adapts well to the defect (Fig. 6). Every grafting material needs stabilisation to prevent mechanical irritation, that is, it must heal in a completely stable position. Movement hinders the process of mineralisation, leading either to healing via the connective tissue or to resorption.<sup>6</sup> In this case, stabilisation was ensured by two things. First, a very rigid membrane was used. This membrane was a deproteinised thin cortical plate that becomes very flexible after rehydration. Second, membranes must always be fixated by pins, screws or sutures in such a way that movement of the barrier membrane is avoided. In this case, resorbable pins were used to protect the membrane both buccally and lingually from dislocating (Fig. 7). When employing an implant with a fixed tapered connection, like the one used here, it should be placed sub-crestally.<sup>7</sup> In order to facilitate the exposure, no cover screw was used for closure. However, a membrane support screw with a height of 2 mm was used to ensure more comfortable handling (Fig. 8).

Five months after insertion, it was found that the band of keratinised gingiva was too narrow and that movements from the cheek were transmitted to the alveolar ridge (Fig. 9). This underpins the importance of the presence of sufficiently keratinised gingiva.<sup>8</sup> Implant exposure was carried out by means of elevation of an apical flap (Fig. 10). If locating the membrane support screw is easy, as it was in this case, in almost all cases no further removal of bone is necessary (Fig. 11). Upon removal of the screw, the effect produced by this procedure became visible. Figure 12 clearly shows the cylindrical chimney that extended the entire length of the membrane support screw to the transition into the inner cone. This tissue was quite stiff and immobile. The histological composition would be interesting to know, since macroscopic evaluation is rather difficult. The author suspects that this was a complex connective tissue structure with slight mineralisation. For this treatment case, the author had a customised anatomical healing abutment milled, which was to accommodate the slim design in the apical part so that the augmented bone did not have to be removed again (Fig. 13). Owing to the still insufficient amount of keratinised tissue and lack of soft-tissue thickness, an





autologous soft-tissue graft was taken from the palate and fixated vestibularly to ensure that there was no movement whatsoever (Fig. 14). The thickness of the tissue above the implant shoulder also plays an important role; it should not be less than 3 mm, otherwise bone resorption will occur.<sup>9</sup>

### Prosthetic restoration

Two months after exposure, the prosthetic restoration was carried out. Since an individual anatomical healing abutment was used in this case, the implant shoulder was completely covered by the connective tissue chimney described (Fig. 15). In order to expose the shoulder, the entire chimney was removed again with the aid of a sulcus former so that the impression post could be placed on the implant shoulder without a gap (Figs. 16 & 17). However, the entire biologically built structure was destroyed as a consequence (Fig. 18). At the time of crown installation, the situation was macroscopically completely free of irritation and healed (Fig. 19). An individually tailored hybrid abutment made from zirconia was attached to a titanium adhesive base and placed in the patient, and a lithium disilicate crown was cemented intra-orally (Fig. 20). The postoperative radiograph shows the gap-free fit and the removed bone in the apical region of the abutment (Fig. 21). Clinically, a perfectly integrated restoration without tissue loss was seen four years after placement (Fig. 22). The CBCT scan showed that complete remineralisation of the bone in the interface appeared to have occurred (Fig. 23).<sup>10,11</sup>

### Discussion

This procedure, which was very experimental at the time, has since become the standard procedure in the author's practice and is the basis of the Stable Tissue Concept. The parts required for the Stable Tissue Concept are now available preassembled. This means that all the parts, from the anatomical healing abutment to the abutment, have been modified to the required geometry and matched to each other in such a way that no tissue needs to be removed in the interface. The impression post no longer rests on the implant shoulder for reference, but

is attached deep in the index of the implant to enable precise impression taking without being inhibited by the taper. The implant used here serves as the basis of this concept. The internal connection with the Morse taper cone fulfils creates the prerequisite that any movement in the abutment is eliminated and no bone resorption occurs. The standard insertion depth of the implant is 2 mm sub-crestally. Such a procedure is only possible with this internal connection; it is possible to insert the implant even deeper without causing any biological complications. Of course, hard- and soft-tissue augmentation must be performed in such a way that the biological conditions for long-term success are created. The augmentative procedure must be adapted to the specific clinical situation. No matter the case, sufficiently thick soft tissue ensures that there is little bone resorption. In the author's practice, the aim is always to generate 4–5 mm of keratinised gingiva above the implant shoulder.

### about the author



Germany-based **Dr Kai Zwanzig** studied dentistry at the University of Münster in Germany and received his PhD from the same university. He completed a four-year specialisation in oral surgery. Since 2007, he has been in private practice together with Dr Bodo Zwanzig in Bielefeld in Germany, which he established as a referral practice for

oral surgery specialising in complex implant cases, plastic periodontal surgery, anterior aesthetics and ceramic restorations. He has authored specialist articles in numerous dental journals.

### contact

**Dr Kai Zwanzig**  
info@praxis-zwanzig.de  
www.praxis-zwanzig.de







# Guided Tissue & Bone Regeneration



**CERASORB® M**  
Resorbable, pure-phase  
β-tricalcium phosphate



**CERASORB® Paste**  
Resorbable β-Tricalcium  
phosphate paste +  
Hyaluronic acid matrix



**CERASORB® Foam**  
Resorbable β-Tricalcium  
phosphate + collagen  
matrix



**Inion®**  
Resorbable pin fixation  
system for films and  
membranes

**curasan**  
Regenerative Medicine



**Osgide®**  
Resorbable collagen  
membrane



**Epi-Guide®**  
Resorbable polylactic  
acid (PLA) membrane



**Ti-System**  
System for fixation of  
foils and membranes



**Osbone®**  
Synthetic spongy  
bone substitute



**Stypro®**  
Resorbable  
hemostyptic



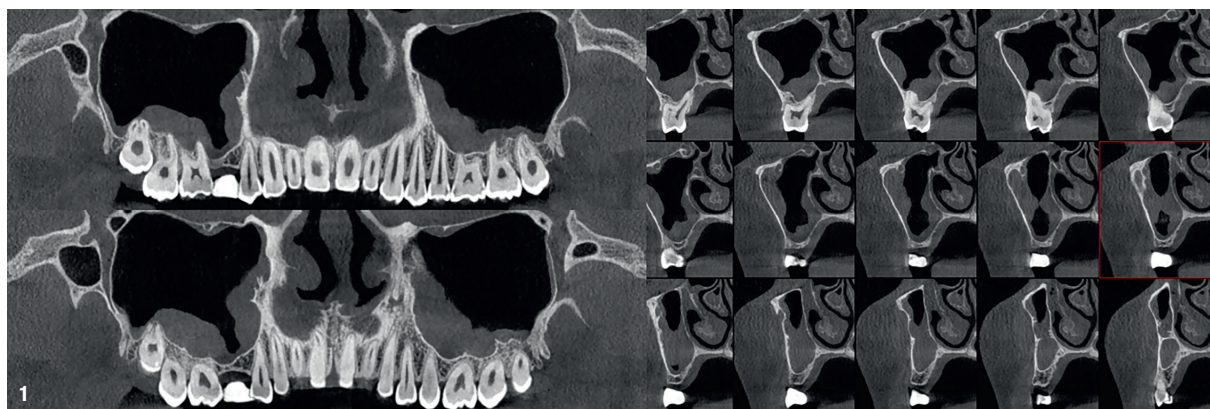
Phone: +49 6027/40 900-0  
info@curasan.de

More information  
on [www.curasan.de](http://www.curasan.de)



# Sinus augmentation and simultaneous implant placement using one-stage Sandwich Technique

Drs Fernando Duarte, Carina Ramos, Paulo Veiga & Marco Infante da Câmara, Portugal



**Fig. 1:** Initial CT scan with coronal and sagittal sections.

## Introduction

The posterior sector of the maxilla consists of an extremely thin facial lamina, with the underlying trabecular bone having a low mineral content. The loss of maxillary posterior teeth is a typical bone resorption pattern that implies a decrease in the bone width available at the expense of the labial plate.<sup>1</sup> This is the explanation why the width in the posterior sector of the maxilla decreases at a faster rate compared to other regions.<sup>2</sup> It should also be noted that the lack of vascularisation accelerates the phenomenon of bone resorption and initial Class D3 or D4 trabecular bone. Even if it decreases by 60%, however, the residual ridge is wide enough in the posterior maxilla for root-form implants. Progressive resorption shifts the alveolar crest towards the palate at the expense of bone width.<sup>3</sup> The posterior maxilla continues to atrophy until the entire alveolus is ablated to basal bone. The vestibular cusp of definitive prosthetic rehabilitation must result from a balance between aesthetic requirements, biomechanical conditions, and bone availability in moderate to severe atrophic crests.<sup>4</sup>

## Maxillary sinus resorption

The inner anatomy of the maxillary sinus maintains its full size while the teeth remain in arch and function, but

expands when the posterior teeth are lost.<sup>1</sup> There is an expansion of the antrum in the inferior and lateral directions, potentially invading the canine region and even the lateral piriform sinus. After the loss of teeth, sometimes related to periapical infectious processes, the amount of bone available in the posterior region of the maxilla for implant placement is greatly reduced. This phenomenon is likely the result of atrophy caused by reduced bone tension due to lack of occlusal function. Implants placed under the ungrafted sinus floor are known to stimulate increased bone formation in the sinus floor. Among the main criteria for the success of treatment with implants, bone quality and quantity stand out. In a limited literature review, it can be seen that, statistically, implants with a height of 10mm or less have a 16% lower survival rate than implants with more than 10mm in height.<sup>5</sup> It is therefore important to emphasise that, bone height is a factor to consider in predictability and longevity of implant-supported rehabilitation. In periodontal compromised patients, a phenomenon known as pneumatic trifurcation is frequently observed, whereby the maxillary sinus extends between the roots almost to the furca in the area of the first molar. Tooth extraction leaves 4–5mm of bone available as a result of this anatomical peculiarity of the sinus. The limited vertical dimension further aggravates the problem of the position of the medialised crest and the already compromised alveolar width. As a general rule, bone quality in



PATENTED



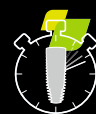[GTB]  
system

## Reinventing implantology

WE WERE THE FIRST,

WE ARE THE ORIGINAL

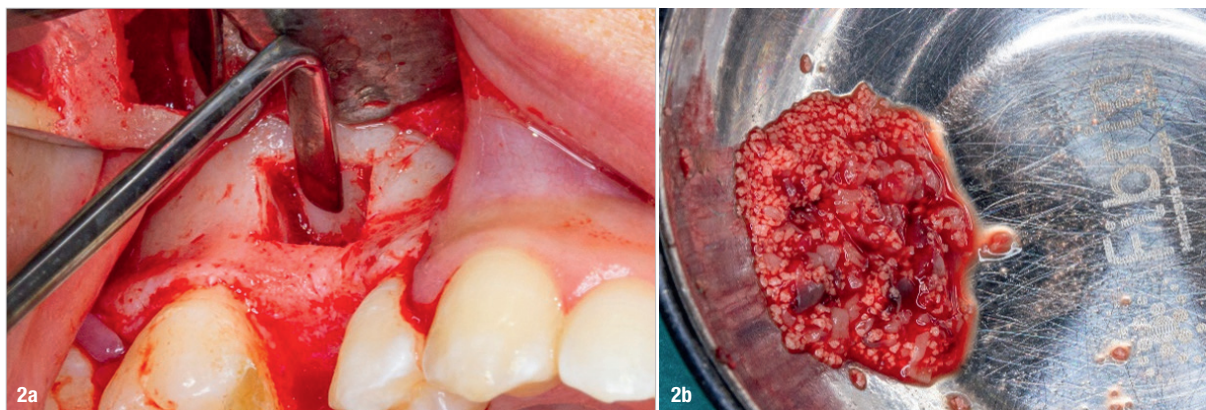
- **ZERO-BONE-LOSS** protocol: to maintain marginal bone
  - **REAL ONE-TIME-ABUTMENT** protocol: for healthy and stable soft tissues
  - **BIOLOGICAL SEAL:** to avoid bacterial infiltration and peri-implantitis
  - Suitable from single tooth to full arch implant rehabilitation
- 
- **PATENTED** implant fixture specifically designed for Immediate Loading
  - **PATENTED** implant system suitable for sub-crestal positioning
  - **PATENTED** abutments designed for One Time Abutment prosthodontics



GTB *plus* GFA

THE FIRST MODULAR  
IMPLANT SYSTEM





**Figs. 2a & b:** Osteotomy by piezoelectric surgery and sticky bone for reconstruction.

the posterior maxilla is worse than in any other intra-oral anatomical region.<sup>6</sup> The bone density of the maxilla is often five to ten times lower than that of the anterior mandible, namely the symphysis and para-symphysis regions.<sup>7</sup> Bone mineral density directly influences the amount of contact between the implant and the bone surface, which in turn transmits the load to the bone.<sup>8</sup> The tension pattern spreads more towards the apex of the implant in low-density bone than in dense bone.<sup>9</sup> When tension is excessive, bone loss occurs in the trabecular bone, which begins in the cervical and may travel throughout the entire body of the implant. Strategies to increase bone-implant contact, both surgically and by modification of implant topography, are being developed.

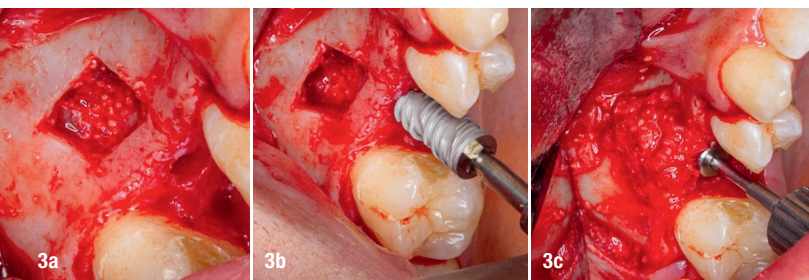
Bone mineral density is extremely important for the survival of the implant in function.<sup>6</sup> Implants have an increased risk of failure in conditions of poor mineralisation. Deficient bone structure compromises not only the primary stability of the implant, but also the ability to support occlusal forces. The absence of cortex on the ridge crest compromises the primary stability of the implant and, since the buccal cortical plate is generally very thin and the crest is relatively wide, it does little to increase stability. The occlusal forces in the posterior region are greater than in the anterior region of the oral cavity by up to five times.<sup>10</sup> The maximum occlusal force in the anterior region varies from 241 to 345 Pa, compared to the maximum occlusal force in the molar region which varies from 1,378 to 1,723 Pa.<sup>11</sup> Natural maxillary molars

have 200% more surface area as well as a significantly larger diameter than premolars,<sup>1</sup> and clearly the combination of the two factors contributes to the reduction in bone tension. In accordance with the clinically observed morphology, in the oral cavity, the support of the implant should be greater in the molar region, thus allowing a more functional and aesthetic prosthetic rehabilitation.<sup>1</sup> It should be noted that the decrease in bone quantity and quality, as well as the increase in occlusal strength, should be highly considered aspects in the treatment of the posterior maxillary region.

### Sinus floor approach

Tatum was the first clinician to suggest a crestal approach to sinus floor elevation and placement of submerged implants.<sup>12</sup> The technique, used in thin residual crestal bone, involved an upfracture into the sinus using a socket-forming instrument. A bone graft was placed beneath the tented sinus membrane. Later, a modified Caldwell-Luc procedure was developed in which the lateral sinus wall was infractured and the wall was used to help elevate the sinus membrane. Autogenous bone was then placed into the area.<sup>13</sup> Since then, a variety of techniques have been described for augmenting the maxillary sinus floor. Two general procedures for sinus elevation for dental implant placement are currently in use: a two-stage technique using a lateral window approach and a one-stage technique using a lateral or a lateral from the crest approach.<sup>14–17</sup> The decision to use a one- or two-stage technique is made based on the amount of bone present at the alveolar crest. Piezoelectric surgery has certain fundamental characteristics that make it safer and more precise than the instruments (manual and motorised) traditionally used in this type of surgery. Morphological and histo-morphometric studies have found that the tissue responds better to piezo-surgery than to the drill.<sup>18,19</sup> The extreme precision and safety of the method are assured by the following:

- a) Micrometric cutting action allows effective cutting of mineralised structures but is inactive on soft tissue;
- b) Absence of macro-vibrations permits better handle



**Figs. 3a–c:** Intra-op images of bone reconstruction and implant placement.

# WEBINAR OF THE MONTH

[www.zwpstudyclub.de/webinar/we-love-biology-the-stable-tissues-concept-in-daily-practice](http://www.zwpstudyclub.de/webinar/we-love-biology-the-stable-tissues-concept-in-daily-practice)

ZWP STUDY CLUB



ZWP STUDY CLUB

## We love biology— The Stable Tissue Concept in daily practice

with Dr Kai Zwanzig

25 March 2022, 3 p.m.



1  
CME-Point

Presented by



Our readers get the opportunity to collect a valuable training point here. Participation is free of charge. To receive the CME point, only registration is required.

### TOPIC

## We love biology—The Stable Tissue Concept in daily practice

Long-term stable results are what every dentist should strive for with his work. Patients trust us and pay a lot of money when it comes to implantological rehabilitation. Many problems in implantology are home-made because biological principles are disregarded. Bone and soft tissue management should be firmly anchored in the implantological dentist's portfolio, as stable tissues are the basic prerequisite for implantological success. For this purpose, hard and soft tissue augmentation must be carried out with materials that are adapted to the situation and indication. Dr Kai Zwanzig has been using allogeneic materials, which are completely ab-

sorbed by the body and thus integrated into the organism, with great success for more than 10 years. Another important factor is the choice of the right implant system. The hardware is also a decisive factor in whether the bone level is maintained. Conical internal connections are best suited for this purpose, as they ensure the necessary stability of the abutment. But even here there are decisive differences, because not all cones are the same! With the Stable Tissue Concept by Dr Zwanzig it is possible to preserve all structures to the maximum, in which the implant system in particular plays a predominant role. The self-locking conical inner connection

prevents any movement of the abutment and is absolutely bacteria-proof. This prevents any micro-movements that could lead to bone loss and biological complications. In addition, there is no titanium abrasion, which can subsequently lead to incompatibilities. The Stable Tissue Concept combines state-of-the-art treatment methods with innovative materials to generate the best possible treatment results.

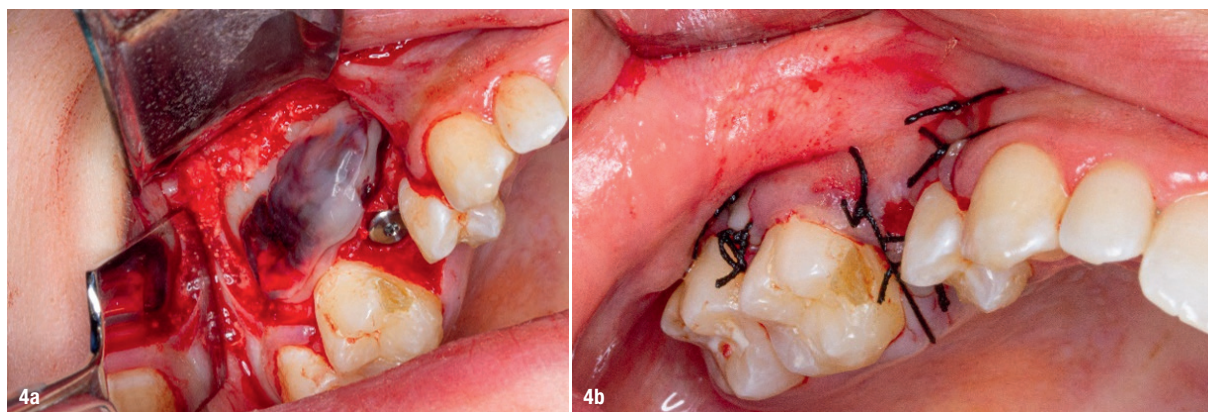


**Dr Kai Zwanzig**  
About the speaker

### Registration/ZWP Study Club

In order to actively participate, a free membership in the ZWP Study Club is required. After registering free of charge at [www.zwpstudyclub.de](http://www.zwpstudyclub.de), users will receive a confirmation e-mail and can immediately make full use of the continuing education offer.





**Figs. 4a & b:** Autologous fibrin membranes and sutures.

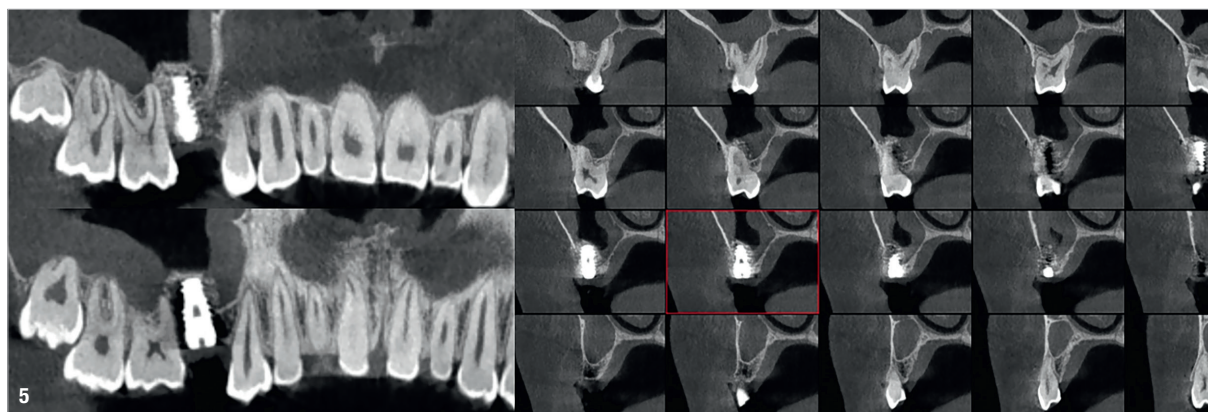
control, thus assuring completely safe access to the most difficult anatomical zones and high cutting precision; c) Cavitation with the cooling saline solution that is generated from the characteristic ultrasonic vibrations produces tiny sprayed particles of water that keep the area cool and free of blood, thus avoiding overheating of the tissue and allowing optimal intra-operative visibility.

### Sandwich Technique

This technique recommends 3D bone reconstruction around the entire body of the implant in cases of elevation of the sinus floor by 4–5 mm and implant placement in the same stage. The technique recommends that two vertical osteotomies be performed on the lateral wall of the maxillary sinus to delimit the bone area to be grafted. A third inferior horizontal osteotomy is performed according to the bone availability shown on a CT scan and a fourth superior horizontal osteotomy to delimit the height of the graft. The bone window produced is reflected into the maxillary sinus with the intention of functioning as a ceiling for the grafted area. Whenever possible, it is advisable to maintain the integrity of the Schneiderian membrane. If it is eventually perforated during the osteotomy or is already perforated, it is necessary to place an

additional membrane. Sticky bone (CERASORB M, curasan; and platelet-rich fibrin) is placed and compressed in the posterior (palatal) portion of the bone window. It is easy to manipulate and accelerates tissue healing and minimises bone loss during the healing period. Subsequently, the implant is placed, the existing cervical bone acting as the primary stability source. Finally, new sticky bone is placed in the anterior portion (vestibular) and membranes of autologous fibrin are applied as a cover of the bone graft.

CERASORB M is a resorbable beta-tricalcium phosphate, pure phase, biomimetic and totally resorbable to fill, join and rebuild bone defects of small, medium and large dimensions; as well as to promote bone fusion throughout the skeletal system. CERASORB M is made of biocompatible synthetic ceramic material with a phase purity of approximately  $\geq 99\%$ .<sup>20</sup> CERASORB M granules have a polygonal shape which allows for better structural adaptation between them, they have an open interconnected micro, meso and multiporous structure macropores (about 65%), radiopacity is lower and absorption and remodeling in autologous human bone are achieved more quickly than with conventional biomaterials. Over the course of months in contact with vital bone, the CERASORB M material is resorbed and simultaneously replaced by autol-



**Fig. 5:** Final CT scan with coronal and sagittal sections.

ogenous bone tissue. As a synthetic and bioactive ceramic material, CERASORB M has excellent histocompatibility and absence of local or systemic toxicity. Unlike materials of biological origin, CERASORB M does not present a risk of infection or allergic reaction, which should be considered an important advantage.<sup>20</sup> Platelet-rich fibrin is composed of therapeutic blood matrices obtained by selective centrifugation and acts as an adjuvant in bone and tissue repair. To obtain the fibrin matrices, autologous blood samples are collected in dry 10ml pure glass tubes (Montserrat) and blood samples in dry polystyrene tubes (Greiner Bio-One), in a tube ratio of 6:2. They should be centrifuged in a centrifuge (Ortoalresa), according to the protocol described by Duarte de Almeida and Alves de Oliveira,<sup>21</sup> which uses a relative centrifugal force of  $200 \times g$  for 10 minutes to obtain two physical forms of fibrin, the polymeric form or solid gel, and the monomeric or temporary liquid form only in one centrifugation step.

## Clinical case

A 21-year-old female patient attended the oral-maxillofacial surgery consultation at Clitrofa medical centre in Trofa in Portugal for placement of an implant in anatomical position #15. In the anamnesis, no allergies or use of medications was reported. On extra-oral clinical examination, no abnormalities were observed. On intra-oral physical examination, a slight bone depression was noted in position #15 as a result of dental agenesis. In the CT scan, a sinus floor of 4mm in height was detected in position #15, making the case suitable for a one-stage implant technique—the Sandwich Technique (Fig. 1). Two vertical osteotomies were performed on the lateral wall of the maxillary sinus to delimit the bone area to be grafted. A third inferior horizontal osteotomy was performed according to the bone availability shown on the CT scan and a fourth superior horizontal osteotomy was performed to delimit the height of the graft 10mm. The bone window produced was reflected into the maxillary sinus, and the Schneiderian membrane was kept intact. The use of platelet-rich fibrin in the grafting process offers the benefits of modelling of the inflammatory response, immune response and tissue repair, tissue reorganisation and angiogenesis. The association with mineral biomaterials facilitates handling and application and allows immediate adhesion to the receiving bed (Fig. 2).

The sticky bone was inserted with maximal light compression into the posterior (palatal) portion of the bone window. Subsequently, the implant (Epikut HE,  $4.5 \times 10.0$ mm; S.I.N. Implant System) was placed, the existing cervical bone acting as the primary stability source. More sticky bone was inserted into the anterior portion (vestibular; Fig. 3). The autologous fibrin membranes create a protected environment for bone regeneration in the defect area and support osteogenesis by presenting a barrier to the infiltration (migration) of soft tissue and thus promote growth of osteogenic cells in the bone defect.

Suturing was performed with simple sutures using non-resorbable thread (#4/0 silk; Fig. 4). The patient underwent systemic antibiotic, analgesic and anti-inflammatory therapy for eight days. Regarding postoperative care, the patient was instructed to maintain strict oral hygiene. After a postoperative period of six months, evaluated by a postoperative CT scan, there was evidence of new bone formation of 12mm in height around the entire implant body and apex (Fig. 5).

## Conclusion

Diffuse maxillary sinus remodeling and posterior maxillary morphology after tooth loss suggest several treatment options. Maxillary sinus graft is an increasingly common procedure in implantology, and the use of resorbable and biomimetic bone regeneration materials, such as CERASORB M, in combination with platelet-rich fibrin (sticky bone), should be considered. This technique has a safety, predictability and longevity character for the rehabilitation of the posterior maxillary sector, and it can be performed alone or in conjunction with other reconstructive procedures. When approached and managed properly, the sandwich technique leads not only to bone reconstruction of the posterior maxilla, but simultaneously to the placement of the dental implant, with consequent restoration of the orthoalveolar shape and function between the arches.

*Conflict of interest: The authors declare that there is no conflict of interest regarding the publication of this article.*

## about the authors




Dr Fernando Duarte  
Author details



Dr Carina Ramos  
Author details



Dr Paulo Veiga  
Author details




Dr Marco Infante da Câmara  
Author details



## contact

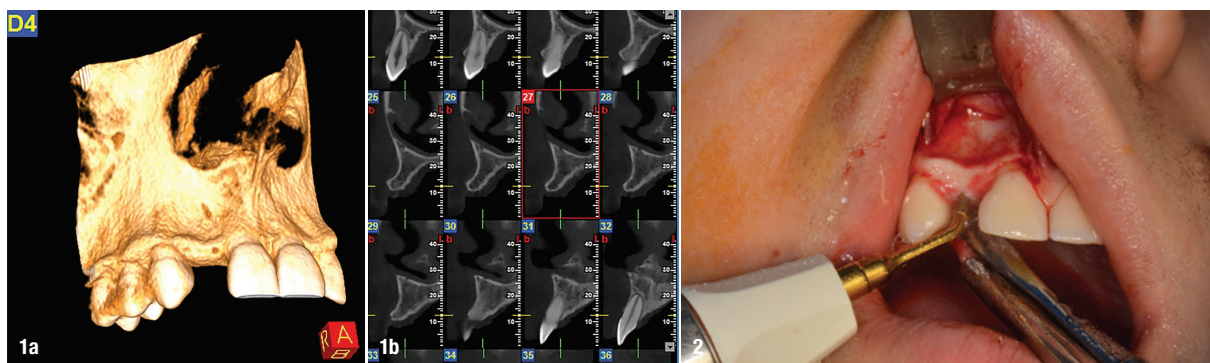
**Dr Fernando Duarte**  
Clitrofa—Centro Médico,  
Dentário e Cirúrgico  
Trofa, Portugal  
+351 252 428960  
fduarte@clitrofa.com





# Alveolar deficiency management in maxillary lateral incisor agenesis

Dr Federico Berton, Italy



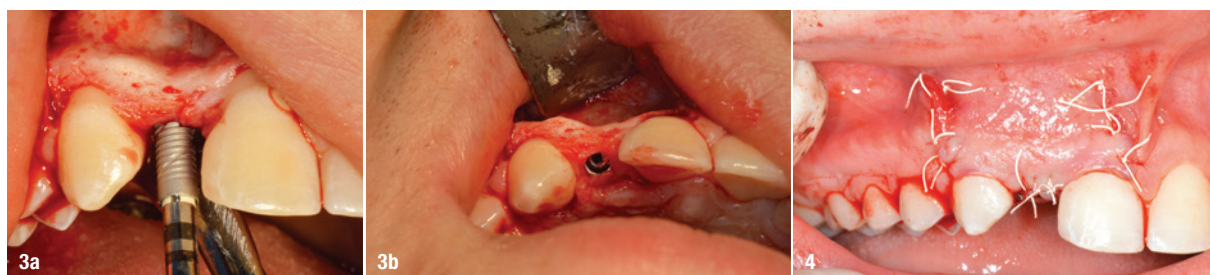## Background

The second most common dental agenesis is that of the maxillary lateral incisors, after agenesis of the mandibular third molars.<sup>1</sup> This common agenesis has important functional and aesthetic impacts for the patient and is challenging to manage for the dental professional. Several approaches to address this condition, both for unilateral and bilateral, have been reported. From least to most invasive, these are (1) the conservative or prosthetic adaptation of the canine to replace the incisor and of the first premolar for canine function (with or without orthodontic assistance); (2) the orthodontically assisted creation of space for the incisor and prosthetic replacement with a fixed prosthesis (employing several approaches); and (3) the orthodontically assisted creation of space for the incisor and implant-supported fixed rehabilitation; removable prosthetic rehabilitation can also be used, but only for provisional necessity when a fixed provisional prosthesis cannot be used.<sup>2</sup> Although implant-supported rehabilitation has many advantages, it also has several disadvantages, such as age constraints, surgical invasiveness, and high hard- and soft-tissue aesthetic demands, given the location of the incisor in the aesthetic zone. Moreover, early

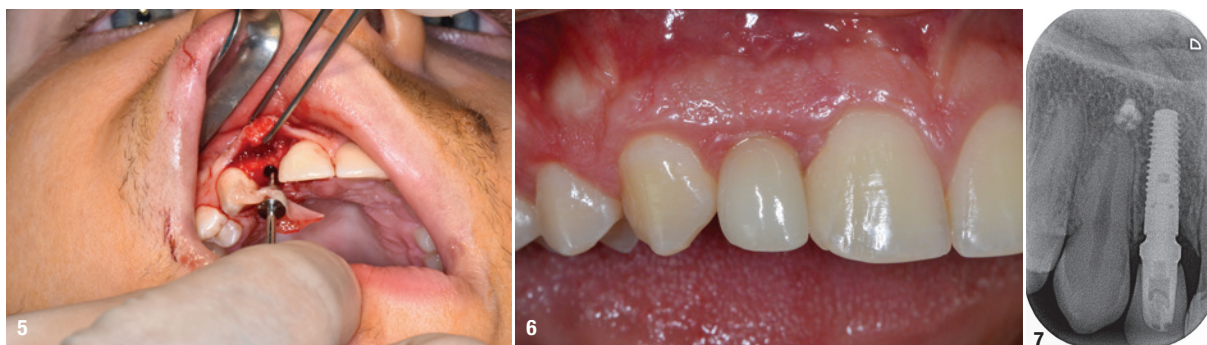
implant insertion should anticipate the long-term prognosis of the rehabilitation according to the age of the patient. Finally, incisor agenesis results in a soft- and hard-tissue deficiency that has to be managed to guarantee an opportune aesthetic result and a long-term prognosis for the implant rehabilitation. Therefore, implant replacement of a missing lateral incisor is challenging for the oral surgeon and the prosthodontist.

## Case presentation

An otherwise healthy 21-year-old patient was evaluated for implant insertion after a careful evaluation of treatment alternatives. The patient underwent 12 months of fixed orthodontic therapy for space creation and tooth alignment. Afterwards, the patient wore a removable retainer until musculoskeletal growth was reasonably complete. The CBCT scans showed sufficient mesiodistal space but a width deficiency (Figs. 1a & b). Clinical examination highlighted a generous band of attached gingiva. Therefore, the treatment plan involved an initial surgery for implant insertion and bone regeneration, then the positioning of a healing abutment and soft-tissue augmentation after six months, and finally the definitive prosthetic rehabilitation.







Amoxicillin (2g) was given as antibiotic prophylaxis before the surgical intervention. A trapezoidal full-thickness flap was elevated from tooth #11 to tooth #13. After bone exposure, the implant site was prepared with a combined approach (piezoelectric and twist drill; Fig. 2). A tapered implant with a conical connection (3.6×12.0mm; GTB, Advan) was inserted 1.5mm below the crest in a palatal position (Figs. 3a & b). Afterwards, bone-promoting holes were made in the buccal bone and a cross-linked collagen membrane (Geistlich Bio-Gide, Geistlich Pharma) was secured with a single palatal pin and two buccal pins positioned between the roots of teeth #11 and 13. The gap was filled with deproteinised bovine bone mineral and autologous bone. After accurate periosteal releasing incisions, primary intention closure of the flaps was gained (Fig. 4). The patient was prescribed antibiotic and anti-inflammatory therapy (ibuprofen, every 8 hours; amoxicillin, every 12 hours), together with a 0.2% chlorhexidine mouthwash, and given instructions on postoperative care. Postoperative healing was uneventful, and the sutures were removed after 14 days.

After 6 months, during the uncovering phase, a roll flap technique was employed to augment the soft tissue and a leucocyte- and platelet-rich fibrin (L-PRF) membrane was placed (Fig. 5). After a healing phase of 1 month, impressions were taken and a cemented fixed lithium disilicate crown was delivered (Fig. 6). After one year of healing, besides a physiological remodelling of the peri-implant bone, the soft and hard tissue remained stable and the aesthetic and functional results were good (Fig. 7).

## Discussion and conclusion

Prosthetic implant rehabilitation is an effective approach to the treatment of dental agenesis. However, the correct management of tissue deficiencies is a fundamental factor for short- and long-term tissue stability and thus final implant success. L-PRF was chosen in this case to promote soft-tissue healing and for soft-tissue augmentation given the presence of a wide band of attached gingiva.<sup>3,4</sup> Therefore, the more invasive option of a connective tissue graft was not considered. The easy withdrawal of blood and the reduced costs of the procedure make L-PRF the procedure of choice for select cases. The choice of hard-tissue augmentation, within the context of implant insertion, was made owing to

the sufficient bone height and width for primary implant stability and to provide the requisite bone width to reduce the risk of facial dehiscence and possible aesthetic impairment and to allow prosthetically driven implant positioning.<sup>5</sup> Also the choice of implant was made according to the state of the art. A position below bone level allows more space for hard and soft tissues, together with prosthetic management of the crown. Therefore, a conical implant connection was chosen. The conical connection is reported to have the least micro-gap with the prosthetic abutment. This seems to protect the peri-implant bone from resorption.<sup>6</sup> Finally, the minimal roughness of the implant surface (OsseoGRIP) was chosen according to the expected prognosis of the implant and its position: a good long-term prognosis may be a benefit of this choice, given the low correlation to peri-implant pathology and the ease of cleaning<sup>7</sup> if exposed to the oral cavity. In conclusion, an accurate treatment plan, together with the most updated scientific findings brought to the clinical setting, facilitates a successful treatment result, for both the patient and the clinician.

## about the author



**Federico Berton, DDS, MSc, PhD**, is a dental consultant at the clinic of maxillofacial surgery and dentistry of the University of Trieste in Italy and an oral surgeon at his family's dental office. He is a lecturer and tutor at the University of Trieste and a national councillor on the board of the Società Polispecialistica Italiana dei Giovani Chirurghi. He is an

active member of the International Piezoelectric Surgery Academy. He engages in research in regenerative surgery, implantology and periodontics and has authored more than 30 scientific articles in international journals.

## contact

### Dr Federico Berton

Adjunct Professor, Department of Medicine, Surgery and Health Sciences, University of Trieste, Clinica di Chirurgia Maxillofacciale e Odontostomatologia, Trieste, Italy  
+39 040 3992020  
fberton@units.it

Author details

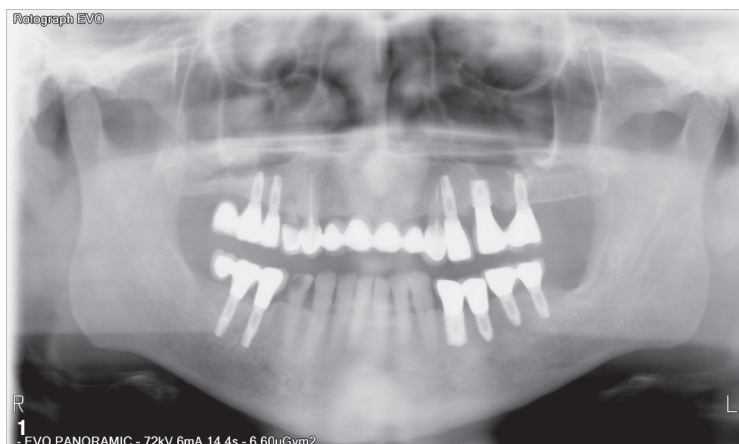


Literature



# Immediate **functional** implants in the **aesthetic** zone of a heavy smoker

Dr Dr Branislav Fatori & Dr Inge Schmitz, Germany

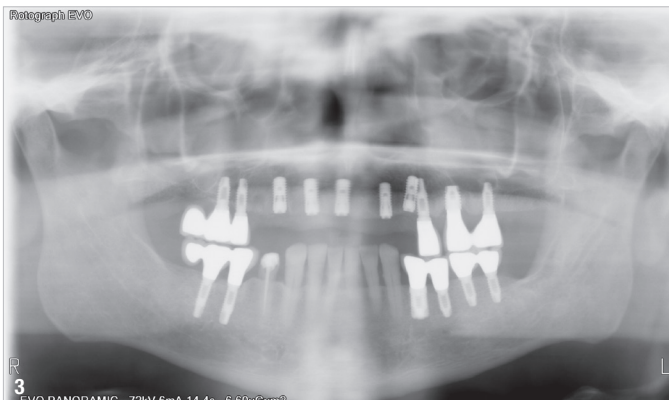
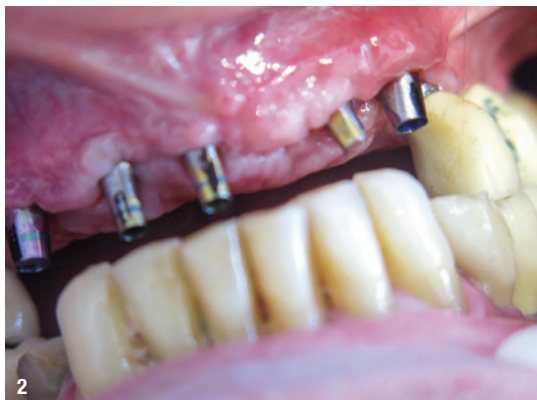

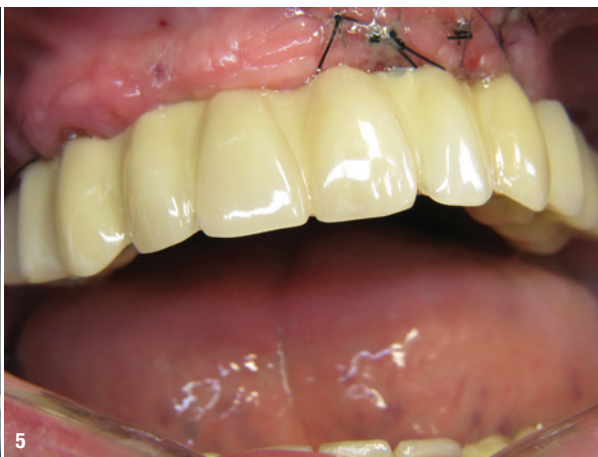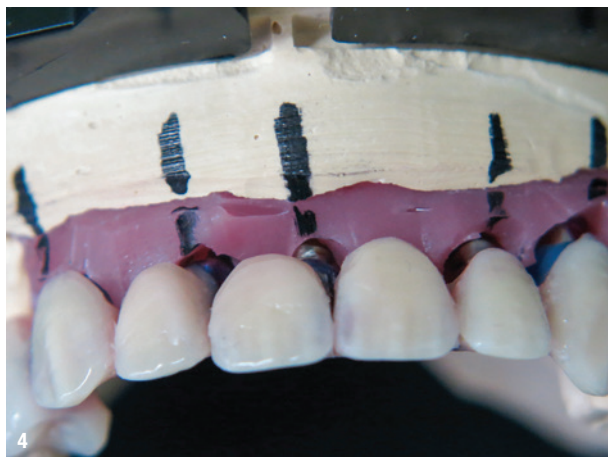**Dental implant placement** represents the most cost-effective and long-term solution for the replacement of missing teeth and it can be argued that dental implants have a high average life expectancy. Immediate or early implant loading procedures are well documented in cases of edentulous sites in the mandible and the maxilla. It is often difficult to obtain good results in the anterior region and it is essential for practitioners to understand the anatomical basis for and the limitations of implant dentistry in the aesthetic zone. To achieve satisfactory implant survival rates, it is vital to have reproducible treatment protocols that reinforce individual expertise and help to achieve high treatment quality. To this end, the following factors should be taken into consideration: Prior to tooth extraction, immediate loading requires the careful selection of patients and a high level of patient

compliance. Immediate loading protocols increase the complexity of treatment planning and the surgical procedure itself. Immediate implant loading should be planned ahead of tooth extraction and should be limited to clinical situations that allow for primary stability ( $>30\text{Ncm}$ ) and correct prosthetic positioning. Additionally, the procedure can help to reduce bone resorption. However, there can be complications when carrying out immediate implant loading in the anterior region. When immediate loading is performed there should be no indication of inflammation, periodontitis or gingivitis. Furthermore, a good concept for Antibiosis is necessary and tooth extraction should be carried out in minimally invasive fashion. In the anterior region the vestibular lamella should not be incriminated. Immediate implant placement in combination with immediate loading can lead to a better clinical and aesthetic treatment outcome. Fixed prostheses on implants show significantly better results than removable prostheses.

## Materials and methods

The 75-year-old male patient was a heavy smoker who smoked approximately 40 cigarettes per day (Fig. 1). Heavy smoking can be a contraindication for implant insertion. There is evidence in the literature pointing to a lower survivability of dental implants in smokers. One possible mechanism by which smoking may affect osseointegration is the reduced blood flow rate due to increased peripheral resistance and platelet aggregation. Smoking directly affects osteoblast function. In general smoking is a major risk factor for implant failure. When smokers are treated with implants good bone quality is required.





## Treatment protocol

Augmentin was administered as premedication for a period of one week. After microbiological examination, an antibiotic was prescribed (Clindamycin Aristo 600, Aristo Pharma). In addition, the patient was instructed to rinse with Chlorhexamed (GlaxoSmithKline). Local anaesthesia was administered with Ultracain D-S forte (Sanofi-Aventis Deutschland), and 40mg Dexamethasone (Dexamethasone) was administered intramuscularly at the same time. The implants used were OKTAGON DENTAL RATIO implants (DRS International) with a diameter of 4.1 mm and a length of 12 mm (Figs. 2 & 3).

## Postoperative care


The criteria of Albrektsson and Buser et al. were applied in the follow-up examinations. These criteria for implant success are frequently cited and generally accepted. According to them, implant success is defined by the absence of persistent subjective complaints, including pain, foreign body sensation and/or dysaesthesia, the absence of recurrent peri-implant infection with suppuration, the absence of mobility, continuous radiopacity around the implant and the possibility of a prosthetic restoration. The healing process of the implants was good in the case described.

## Discussion

The literature frequently reports high survival rates for the immediate loading of fixed full-arch maxillary prostheses supported on three or four implants or on multiple basal implants (Figs. 4 & 5).

There is evidence that immediate loading protocols demonstrate high implant survival rates and could be recommended with caution in certain clinical situations. The use of implants in smokers may influence failure rates in the form of postoperative infections and marginal bone loss. Therefore, our results should be interpreted with caution.

*Editorial note: During the production of this article Dr Inge Schmitz unfortunately passed away.*



## about the authors



**Dr Dr Branislav Fatori** has more than four decades of experience in implantology. In addition to his German doctoral degree, he holds a second doctoral degree from the University of Belgrade in Serbia. He was trained at prominent clinics around the globe and has worked as a consultant for expert societies and implant manufacturers.



**Dr Inge Schmitz** has worked at the Institute of Pathology of the Ruhr University Bochum in Germany since 1990. Her main interests were implantology, stents, electron microscopy and osteology. She studied biology at the Ruhr University Bochum and completed her PhD at the then University of Essen in Germany in 1989.

## contact

### Dr Dr Branislav Fatori

Essen, Germany  
+49 201 82188890  
info@fatori.de  
www.fatori.de



# Fine dentistry and creative engineering go hand in hand

An interview with Dr Kai Zwanzig and Ric Donaca

**Many problems in implantology** are self-made because biological principles are disregarded. Bone and soft-tissue management should be firmly anchored in the implantologist's portfolio, as stable tissues are the basic prerequisite for implantological success. With the new Stable Tissue Concept from Dr Kai Zwanzig, it is possible to preserve all structures to the maximum, in which the implant system in particular plays a paramount role. The new K3Pro product line from Argon Dental offers the best prerequisites for this. In this interview, Dr Kai Zwanzig and Ric Donaca, Managing Director of Argon Dental, discuss the advantages of this system.

**Dr Zwanzig, please describe your motivation to personally commit to the new implantology concept "Stable Tissue".**

**Dr Kai Zwanzig:** I love teeth. My patients love their teeth. If a tooth cannot be preserved, I am not satisfied with "tooth replacement". And no colleague, no dental technician and no patient should be satisfied with "replacements". The focus of my medical practice is

to take into account the entire biology surrounding a healthy tooth, set in healthy soft tissue and stable bone. Nothing else should apply to lasting implantological success. Why do the majority of implant manufacturers pay so little attention to these scientifically quantifiable biological factors of the healthy tooth, forcing me to work around the considerable design-related problems of their systems—which I locate in a professionally driven "faster, simpler, more productive"—with all my skills? It is time to commit to a new value orientation in implantology and to pave the way for it. This can only be done hand in hand with an industry partner who ticks similar boxes and is prepared to continue to substantially improve a good product. I have known and appreciated Argon for ten years now.

**Mr Donaca, your K3Pro implant system is considered by insiders to be particularly innovative and proven at the same time. Why is that?**


**Ric Donaca:** The principle of our conical implant-abutment connection—a particularly long cone of 3.1 mm with such strong friction that micromovements are excluded, no bacterial colonisation of the implant interior can take place and a loaded retaining screw is basically obsolete thanks to the friction lock—comes from mechanical engineering and was adapted for implantology in my early days in the 1980s.

It is not a pseudo-cone with a flat angle, which actually only corresponds to a phase for sealing between the implant and abutment, but does not prevent movement and continues to load the screw. As a result, the force fit equals the solidity of a monolithic implant, with all the dental advantages of a two-piece system. The innovation lies in the development of a practical prosthetic handling of this special connection, which allows easy try-in, precise height of the crowns even without butt joint and defined forces. But this, too, is now proven.



Fig. 1: Dr Kai Zwanzig (left) and Ric Donaca, Managing Director of Argon Dental.

“It is time to commit to and pave the way for a new value orientation in implant dentistry.”



**Fig. 2:** The K3Pro+ Implant System from Argon Dental.

**Your system grew into an extended family over the years with numerous prosthetic options, different thread designs, many lengths and diameters, and last but not least, complete digitisation. How did the further evolution with Dr Zwanzig come about?**

**Ric Donaca:** As an innovation advocate in the context of allogeneic transplants and a strong voice of the young guard of German implantologists, Kai's word has always carried a lot of weight in our company. The sustainable bone and gingiva preservation thanks to K3Pro and the special aesthetics due to subcrestal positioning are a well-known and scientifically proven strength. But in addition to these qualities, Kai immediately recognised the optimisation potential of the system in the aspect of the biology of mucosal and bone regeneration, which we had previously paid little attention to. This is grumbling at a very high level, but the end result shows that it was worth the effort. With K3Pro, we are talking about what is undoubtedly the most minimally invasive, anatomically optimised and tissue-friendly titanium implant on the market.

**Dr Zwanzig, please describe the Stable Tissue Concept to our readers.**

**Dr Kai Zwanzig:** It is not a product alone that is in the foreground, but a philosophy. An implantological overall view that brings all aspects—surgical and prosthetic challenges and procedures, indication and anatomy, implant system used and specific patient wishes—into harmony. The ultimate goal is patient satisfaction. This takes into account aesthetics—beautiful teeth and not “dentures”—and sustainability. A beautiful, reliably healthy implant for a lifetime! Colleagues who adopt this philosophy will also be on the winning side economically. Of course, this also requires questioning outdated, partly industry-driven methods and habits, as well as the willingness to change paradigms. Even for the complicated case, it is always true that you have to have the

perfect end result in front of your mind's eye. I always create bone if it is required for this, but I always think of the soft tissue first. I have to question what will harm the soft tissue and consistently sort this out: Any implant design with cortical pressure is likely to irritate the bone, which can lead to recession. It does not matter whether the emergence profile is wide or narrow, with or without a platform switch, polished or surface-treated margin. It should be noted that implants with a short taper must have thickenings to cope with peak loads (often at the shoulder) due to the unfavourable load distribution, which is surgically disadvantageous.

Good results are possible with bone level implants without a cortical anchorage thread, but only with strict adherence to the so-called three-millimetre rule, which states that one must have at least 3mm of stable gingiva over the bone and implant shoulder to seal the implant. This requires a high effort in soft tissue surgery. And even then, a predictably good long-term result is only possible if the load distribution of the prosthetics is perfectly balanced. Tissue-level implants and a perfect final result, on the other hand, are ruled out from the outset because of the unsatisfactory aesthetics and have long been out of date.

**Mr Donaca, what is the solution?**

**Ric Donaca:** A subcrestally placed implant is the solution, with a shoulder that slopes down toward the abutment exit and is completely surface-treated according to the OsteoActive principle, inviting the bone to seal it permanently during regeneration. This is because, thanks to the stable long cone, the implant not only remains tight, but the abutment also remains absolutely motion-free. And thus bone and soft tissue remain permanently stable, there is no longer any bacterial point of attack. The long-term results prove us right, but I would like to emphasise that this is only possible if an implant such as the K3Pro is optimised for subcrestal use in

every respect. This principle opens up every conceivable option for prosthodontists thanks to the subcrestal implant position. Narrow, particularly tissue-friendly emergence profiles are clearly the trend.

**Dr Kai Zwanzig:** From a scientific point of view, it should be added that studies have shown the following: It is not so much the microgap with the bacterial pumping effect in the implant–abutment connection that is problematic, but rather the constant movement between abutment and implant, however minimal. The objective for bone and gingiva preservation is to completely eliminate this movement. This has been achieved with K3Pro—hence my personal commitment to this philosophy with full conviction. As a friend of biological dentistry, I must not forget that thanks to this principle, no titanium oxide abrasions are released and the organism is not gradually contaminated with them.

“The practical handling with complete preservation of the biology of bone and soft tissue is in the foreground.”

#### So what is the innovation that came out of the collaboration?


**Dr Kai Zwanzig:** By exploiting the entire as yet undiscovered biological potential of K3Pro. We proceeded step-by-step. I let my first cases heal in the classic closed subcrestal way and regretted having to “search” for the cover screw in the tissue when uncovering it. With the use of the high cover and membrane fixation screw of 2mm height, everything changed. I was thrilled with the stable bone and tissue channel that formed completely over the implant shoulder, and so this became my personal standard protocol. The goal was not only to take the impression and gingival design directly through this tissue channel of unique biology, but also to have the abutments precisely pick up this geometry, thus providing the maximum stable support of the bone over the entire length of at least 2mm. This was unique among all implant systems known to me and also takes into account recent scientific findings that lengths of 8 to 9mm are completely sufficient and only in immediate implantations more bone should be grasped apically due to the alveolar anatomy.

**Ric Donaca:** For this we had to extend all the impression posts, gingiva formers, scanposts and, above all, the abutments to an emergence length of 2mm.

In addition, with regard to the transfer aids, we switched from a butt-joint principle on the implant shoulder to impression-taking purely via indexing by means of a hexagon and depth stop in the implant, because at this stage the cone fit is not yet desirable; practicable handling with complete preservation of the biology of bone and soft tissue is paramount. This is how the new prosthetic line of the K3Pro was developed within the framework of the Stable Tissue Concept—it stands for one millimeter more. Quite a challenge for the engineer.

#### Dr Zwanzig, is it difficult for implanting people who are changing over to this new system to adjust to it?

**Dr Kai Zwanzig:** It always takes conviction to decide to fundamentally change learned techniques. With regard to the 2mm subcrestal positioning, experience in implantology is of course an advantage. But thanks to Argon's optimised instrumentation and optional digital planning in the full-guided procedure, the changeover is easy. As soon as you have gotten rid of old habits of placing the implant supra- or equicrestally and instead place it deep and leave it to biology with the high healing screw, you immediately recognise the superiority of this concept. Such reliable and rapid osseointegration is unparalleled! Especially with immediate implant placement. Uncovering, gingiva shaping, transferring or scanning is extremely simple, since the dimensions of this healing screw already specify the appropriate components. Only the gingival height needs to be determined. My technicians are delighted with the innovative model analog, which completely eliminates the handling disadvantages of a friction-fit tapered connection and makes prosthetic work as easy as with a butt fit. And last but not least, there are our courses under the sign of the Stable Tissue Concept: At Argon in Bingen or at my place in Bielefeld.



#### contact

**Argon Dental**  
Bingen, Germany  
info@argon-dental.de  
www.argon-dental.de



# BECOME AN AUTHOR

for implants—international magazine of oral implantology

Interdisciplinary, transparent & market orientated



www.oemus.com



Become part of a successful network and benefit from a wide reach and high level of awareness

Please send back your fax form or contact Mrs **Janine Konzato**:  
j.konzato@oemus-media.de  
Phone: +49 341 48474-147



Fax: +49 341 48474-290

☐ Yes, I want to become an **author** for implants—international magazine of oral implantology. I would like to submit an article on the following topic:

\_\_\_\_\_

☐ Yes, I want to become an **author** for ceramic implants—international magazine of ceramic implant technology. I would like to submit an article on the following topic:

\_\_\_\_\_

\_\_\_\_\_  
Last Name, First Name

\_\_\_\_\_  
Street, ZIP, City

\_\_\_\_\_  
Phone, E-mail

Stamp

implants 3/20

Argon Medical

## Perfect and aesthetic mucosal stability

The preservation of tissue is essential for long-term implantological success in terms of aesthetics and function alike. Our K3Pro and the new K4Pro have always been optimised for subcrestal insertion, so the optimum biological width can always be maintained.

The implant with its anatomically designed shoulder is reliably sealed by vital bone. Science and practice determined that strict adherence to a 3 mm minimum rule is a basic prerequisite for the application of the zero bone loss concept and thus the sustainability of implantological success. Users of crestally placed implants face the problem that a minimum

3 mm thick gingiva must be present for this protective mucosal sleeve to remain stable. Users of the subcrestal K3Pro and K4Pro are always on the safe side here. Argon Dental is again significantly increasing the range of indications. New components with identical emergence profiles for healing, impression taking, laboratory and prosthetics allow for the first time 2 mm subcrestal insertion with gingival heights of 1, 2 or 3 mm.

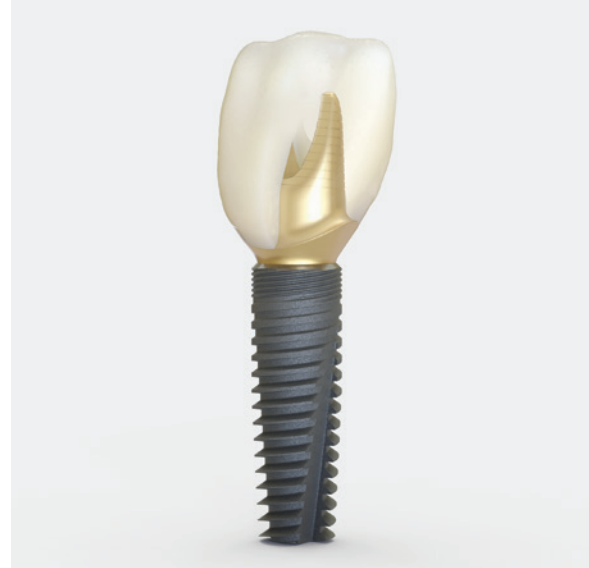The unique biology created by this subcrestal philosophy of healing remains untouched after surgery. Healing screws and abutments, impression posts and abutments precisely matched to the respective insertion depth and gingival height function in unison like a first-class orchestra. The results are unparalleled, and the unique systematic approach to application makes it easy for new users.

**Argon Medical, Germany**  
+49 6721 30960  
[www.argon-medical.com](http://www.argon-medical.com)

curasan

## Maximum flexibility with CERASORB® Foam

CERASORB® Foam is a multiporous composite material for bone augmentation consisting of collagen and resorbable bioceramics. The use of phase-pure  $\beta$ -tricalcium phosphate with regular interconnecting porosity and primary particle size results in the degradation of the biomaterial simultaneous to bone formation. The shapeable variant of the CERASORB® Foam with low density allows plastic deformation and can be individually adapted to the defect. CERASORB® Foam is miscible with blood and I/A-PRF at a ratio of 1:1, producing an ideal kneadable mass for filling bone defects. The multiporosity of the granules embedded in the collagen helps bone to grow in faster. Blood components and body fluids can permeate



Dentsply Sirona

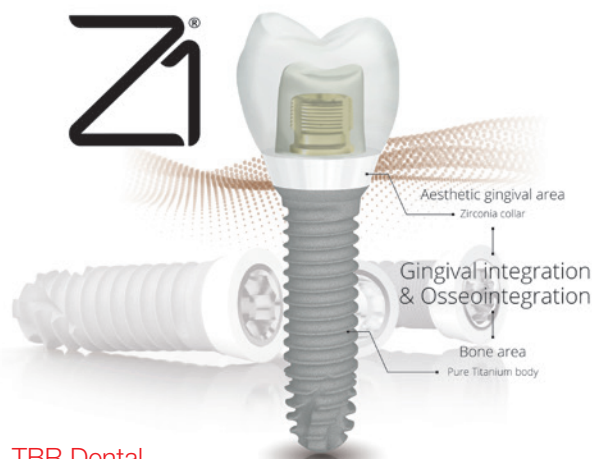## The perfect union of form and function

The new DS PrimeTaper is a demonstration of science and art in harmony. Its innovative design enables predictable, secure placement across the widest range of bone densities. DS PrimeTaper is a self-tapping implant with a tapered design and progressive self-cutting threads that have been crafted to cut quickly and engage without excess torque, the result is immediate installation stability. A simple drilling protocol ensures excellent control and supports the workflow. Lasting performance is further enhanced by the unique MicroThread design that provides long-term biomechanical bone stimulation, improved aesthetics and lasting satisfaction for both patient and clinician. Building on Astra Tech Implant System's proven reputation for fast, predictable osseointegration, the DS PrimeTaper OsseoSpeed surface bonds with more bone, more rapidly. The outcome is long-term bone care and stability that outperforms the competition at both 1- and 5-year intervals (Norton MR, Astrom M. Int J Oral Maxillofac Implants 2020; 35:1099–111).

**Dentsply Sirona, Sweden**  
+46 31 376-3000  
[www.dentsplysirona.com/en/explore/implantology/ds-primetaper.html](http://www.dentsplysirona.com/en/explore/implantology/ds-primetaper.html)



**curasan AG, Germany**  
+49 6027 40900-57  
[www.curasan.de](http://www.curasan.de)



TBR Dental

## Giving you confidence in implantology

The Z1 implant, combining a titanium body and a zirconia collar, offers the advantage of being a tissue-level implant as well as using materials optimised for the tissues with which they are in contact. Tissue-level implants require only one surgery, which saves time for the practitioner and is also more comfortable for the patient. Moreover, it allows a healing of the soft tissues of first intention as well as a simultaneous healing of the hard and soft tissues, thus saving treatment time and improving final aesthetic. Its titanium body, combined with its sandblasted and etched surface, allows a good integration of the implant into the bone and also provides it good mechanical properties. The transgingival zirconia collar reduces bacterial colonisation compared to titanium thus protecting the bone from bacterial infiltration.<sup>1</sup> In addition, the adhesion and proliferation of fibroblasts is improved, leading to a strong attachment between the soft tissues and the zirconia collar, ultimately leading to an optimal aesthetic result. This last item is accentuated by the zirconia colour that is similar to the one of natural teeth, which will avoid the greyish colouring of the gingiva.<sup>2</sup> Discover the Z1 implant to combine the advantages of a tissue-level implant and a transgingival zirconia collar!

**TBR Dental Group**  
24, impasse René Couzinet  
31500 Toulouse, France  
[www.tbr.dental](http://www.tbr.dental)



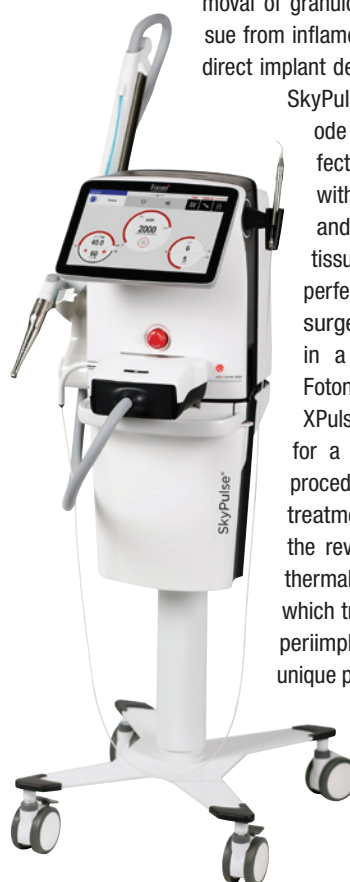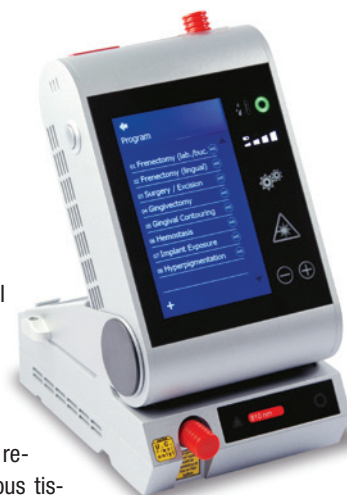Fotona

## Ultimate mobility, style & performance

Fotona's award-winning SkyPulse dental laser is widely recognised as a uniquely versatile tool in dentistry, and implantology is no exception. SkyPulse's high-precision Er:YAG laser is perfect for the treatment of peri-implantitis, including the re-

removal of granulomatous tissue from inflamed surfaces and direct implant decontamination. In addition,

SkyPulse's high-performance diode laser allows for highly effective soft-tissue procedures with simultaneous coagulation and disinfection, as well as tissue regeneration, making it perfect for applications in oral surgery. For those interested in a more compact solution, Fotona also offers the hand-held XPulse diode laser that is ideal for a wide range of soft-tissue procedures, plus innovative new treatment possibilities such as the revolutionary EmunDo Photo-thermal & Photodynamic Therapy, which treats both periodontitis and periimplantitis with the aid of a unique photosensitive activator.



**Fotona d.o.o., Slovenia**  
+386 1 5009100  
[www.fotona.com](http://www.fotona.com)

MIS

## Single-use, procedure-ready drills

MIS presented its latest innovation at the DS World event in Las Vegas. MIS XD are single-use, sharp, sterile, procedure-ready drills, delivering a complete procedure in every implant package. These single-use drills are designed for optimal implant-drill compatibility and high initial stability, while ensuring safe and simplified procedures. Using sharp drills in every drilling procedure prevents drill wear and deformation. Their sterility eliminates the need for post-surgery sterilisation and reduces the risk of cross-contamination and infection. MIS XD are always compatible with the implant shape and dimensions. The drills are designed for depth control, providing more visibility and confidence in the drilling procedure. Single-use drills allow for a simple and quick procedure while eliminating cleaning, re-sterilisation, and the management of drill replacement. MIS XD will be available with the MIS C1 and MIS SEVEN implants from December 2021 in the US Market.

**MIS Implants Technologies, Israel**  
[info@mis-implants.com](mailto:info@mis-implants.com)  
[www.mis-implants.com](http://www.mis-implants.com)





BioHorizons Camlog

## The next generation soft-tissue augmentation material



When choosing a biomaterial, there is a strong demand in clinical practice for predictable outcomes. For over 20 years, LifeCell, a leading global medical technology company, has developed innovative products for use in a wide range of applications. BioHorizons Camlog expands its soft-tissue portfolio to bring NovoMatrix, an innovative soft-tissue augmentation material. NovoMatrix is an acellular extracellular dermal matrix consisting of tissue-engineered porcine material. It is a breakthrough in xenogeneic processing ensuring a structurally intact, undamaged scaffold that supports cell and microvascular ingrowth. The proprietary tissue processing allows for rapid revascularisation, cell repopulation and minimal

inflammation. NovoMatrix comes pre-hydrated and ready to use and offers a true alternative to autogenous soft-tissue grafts and current products on the market. The NovoMatrix indications include guided tissue regeneration procedures in recession defects for root coverage, localised gingival augmentation to increase keratinised tissue (KT) around implants and natural teeth, and alveolar ridge reconstruction for prosthetic treatment.

**Camlog Biotechnologies GmbH, Switzerland**  
**+41 61 5654100**  
**www.biohorizonscamlog.com**

AD

## SUBSCRIBE NOW!

implants—international magazine  
of oral implantology

Interdisciplinary, transparent & market orientated



ONLINE  
SUBSCRIPTION HERE



www.oemus-shop.de

**Fax: +49 341 48474-290**

I would like to subscribe for the following journals:

- ☐ **ceramic implants—international magazine of ceramic implant technology** 2 issues p.a. € 30<sup>,-</sup>
- ☐ **implants—international magazine of oral implantology** 4 issues p.a. € 44<sup>,-</sup>

**Terms & Conditions:** The subscription may be cancelled within four weeks after the justification within 14 days of entering marketing (OEMUS MEDIA AG, Industriestraße 25, 04229 Leipzig, Germany). Shipping and handling expenses will follow. The subscription automatically renews unless notice is sent at least 30 days before the end of the subscription period.

\* Airplane includes VAT, shipping and handling

**OEMUS MEDIA AG**

Last Name, First Name

Company

Street, ZIP, City, Country

E-mail

Credit-Card Number

Expiration Date

Security Code

Signature

Industriestraße 25 • 04229 Leipzig • Germany • Phone: +49 341 48474-301 • [subscriptions@oemus.de](mailto:subscriptions@oemus.de)

# ceramic implants

goes **ONLINE!**

ePaper · news · articles · community · newsletter



Check out the  
new website!

[ceramic-implants.info](http://ceramic-implants.info)



Subscribe to  
the newsletter!

[ceramic-implants.info/subscribe](http://ceramic-implants.info/subscribe)



# 50 plus one years into the future

## An anniversary congress for German implantology

Dr Georg Bach, Germany

**“Everything had been perfectly prepared, but the little matter of a virus got in the way”**—with this opening statement, the congress president of the German Association of Dental Implantology (DGZI) opened the third Future Congress for Dental Implantology, which took place on 1 and 2 October in Cologne in Germany. Indeed, last year’s 50<sup>th</sup> anniversary congress, which was planned to be held in the founding German city of Bremen, fell victim to the coronavirus. However, DGZI made a virtue of necessity and celebrated its 50<sup>th</sup> birthday in the 51<sup>st</sup> year of its existence—with 50 speakers and about 250 participants (the coronavirus-related regulations did not allow for more). The focus on the first congress day on the Friday was on 75 table clinics, the livestreaming of two surgeries into the conference hall and a highly regarded digital poster presentation. The Saturday was all about science: renowned speakers—the who’s who in German implantology—presented outstanding scientific lectures, rounded off with courses for practice staff and a huge dental exhibition with 25 hand-picked industry partners.

### Future-oriented congress structure

In terms of content, the course of events and the structure of the congress, Europe’s oldest professional society deliberately and unquestionably succeeded in breaking new ground, even in its 51<sup>st</sup> year of existence. The organisers aimed at realising a congress that was future-oriented, even in its organisation, featured attractive content and allowed the presentation of new points of view. Undoubtedly as a consequence of the coronavirus-related restrictions, the congress was somewhat smaller than in previous years. “We are pleased that so many participants came despite the pandemic, but we naturally would have appreciated even greater participation numbers,” said DGZI vice president Dr Rolf Vollmer. “Our overriding focus is on a structural reorientation and, above all, quality.” Dr Arzu Tuna, the DGZI vice president who represents the younger generation of implantologists, added: “The reactions of our colleagues and their feedback show that we have taken the right path!”



**Fig. 1:** The DGZI board members: Dr Rainer Valentin, Prof. Gyula Takacs, Oliver Beckmann, Dr Navid Salehi, Dr Rolf Vollmer, Dr Elisabeth Jacobi-Gresser, Dr Georg Bach and Dr Arzu Tuna (from left).





**Fig. 2:** Dr Georg Bach leads the participants in his opening lecture through half a century of dental implantology. **Fig. 3:** Prof. Ralf Smeets, Prof. Knut A. Grötz, Dr Georg Bach, Prof. Daniel Grubeanu and Prof. Bilal Al-Nawas (from left). **Fig. 4:** Dr Armin Nedjat (right) receives from Dr Georg Bach the honour for his father Dr Manutschehr Nedjat as a long-standing member of the DGZI. **Fig. 5:** Dr Georg Bach in conversation with Prof. Knut A. Grötz (left) and Prof. Bilal Al-Nawas (right).

## Future Podium

The congress set off with a bang: three lectures with (at least on paper) completely different orientations painted a clear picture of the future options for our special field as well as for dentistry as a whole. The DGZI president, Dr Georg Bach, spoke about triumphs and tragedies in implantology, reflecting first on the founding of DGZI 51 years ago in Bremen. At that time, the new professional association collectively identified providing knowledge transfer in the field of implantology and promoting this then still young discipline as its core mission, and it focused on cooperation with other professional societies and collaboration with dental laboratories. By means of two patient cases, Dr Bach, who is an oral surgeon from Freiburg in Germany, demonstrated that it is undoubtedly possible to achieve successful results with implants that last for decades, based on the incredible progress that has been made over the past five decades.

The ideals and goals of DGZI today are still the same as in 1970. In order to be prepared for the next years of DGZI, the society is consistently focusing on continuing education and knowledge transfer, specifically aimed at the younger generation of dentists and dental technicians. Collegial and constructive cooperation with other implantological societies is another goal of DGZI for the coming years.

Prof. Shahram Ghanaati, a true expert in the field of biological dentistry, spoke next. His lecture on the use of autologous blood concentrates kicked off with a surprising statement: "Forget all classifications of biological materials in terms of their origin etc. What matters is the individual immune response." Prof. Ghanaati presented six studies and evaluated them with regard to their relevance to daily implantology practice. By means of excellently documented case studies, the Frankfurt-based oral surgeon, who leads a surgical oncology department at Goethe University, demonstrated how valuable the use of platelet-rich fibrin (PRF) membranes can be, particularly in socket preservation, and how this can achieve faster and more biological wound closure and, consequently, significantly improved healing. Prof. Ghanaati recommends thorough filling of the socket with PRF. Moreover, he sees hybrid materials as a promising future treatment option. He concluded by giving dental professionals one task: "You need to learn how to draw blood quickly and gently!"

At the Center for Dental Medicine of the University Hospital Freiburg, Prof. Katja Nelson has been working in translational implantology for quite some time and has acquired in-depth knowledge in this field over the past two decades, particularly in terms of digital approaches. Against this background, the first take-home message of her lecture surprised some participants: "When patients demand implant treatment, it's not enough to send them





**Fig. 6:** The winners of the Implant Dentistry Award 2021 around Dr Arzu Tuna. **Fig. 7:** The speakers at the MUNDHYGIENETAG 2021: Prof. Thorsten M. Auschill, Prof. Nicole B. Arweiler, Prof. Mozghan Bizhang and Prof. Stefan Zimmer (from left). **Fig. 8:** Prof. Daniel Grubeanu (left) and Dr Wolfgang Jakobs. **Fig. 9:** The table clinics on Friday afternoon: a wide variety of implantology topics were discussed at 25 tables. **Fig. 10:** Impression of the well-attended table clinics on Friday afternoon. **Fig. 11:** From left: Katrin Wolters (DGZI secretariat), Dr Torsten Hartmann (DGZI managing director and member of the company management of OEMUS MEDIA AG) and Katrin Mielke (DGZI secretariat).

directly for a CBCT scan. A thorough clinical examination remains irreplaceable.” For Prof. Nelson, defining clear rules and adhering to them is a basic prerequisite for successful implant surgery. She then moved on to digital dentistry, paying special attention to data collection as the basis for creating dental restorations with the highest accuracy of fit. “You can do a lot with a CBCT scan and a digital scan,” she said. According to Prof. Nelson, segmentation is followed by manipulation of the data set. Thereafter, Dr Bach summarised one of the central messages of the three introductory lectures as follows: “Today, we are able to do a lot, but frankly, we have to be able to do a lot.” As part of the first round of the panel discussion, both Prof. Nelson and Prof. Ghanaati emphasised that the safe application of their preferred procedures requires an intensive and time-consuming training phase.

## Live surgeries

Now it was time to put what had been learned into practice or, rather, to see it put into practice: multi-channel livestreaming of surgical operations into the conference hall enabled the participants to gain a unique and fascinating insight into the work of renowned practitioners—in high definition. Live surgeries are a tradition at DGZI congresses. In introducing this novel format, DGZI broke new ground in continuing education at the time. Hamburg-based specialist Dr Jan Klenke carried out the first surgery, which involved an elaborate recession coverage with an acellular dermal matrix using the tunnel technique. Owing to the dual site (donor and recipient) morbidity, periodontal recession coverage employing autologous graft harvesting is not that frequently used these days. However, Dr Klenke proposed a novel therapeutic approach: with the insertion of an acellular dermal matrix, postoperative morbidity is significantly minimised, since there is no need to harvest an autologous connective tissue graft.

In the second livestreamed surgery, German Society of Oral Implantology President Prof. Daniel Grubeanu from Trier in Germany presented his ideas, approach and experiences in relation to immediate restoration concepts by means of a quite challenging patient case in which an unsalvageable tooth #23 had to be extracted. Immediate implant placement with immediate loading was planned, and he detailed this step-by-step, including planning, implant placement and placing the temporary prosthetic restoration. For this purpose, the extracted tooth was shortened and hollowed out and then converted into a soft-tissue stabilising crown. It was impressive to see that the soft tissue was supported in such a way (also using a PRF membrane) that there was no post-traumatic loss whatsoever. His approach was unquestionably technique-sensitive and complex, but the treatment result proved the appropriateness of his procedure.

## Table clinics and the digital poster presentation

For some, it was an unfamiliar sight: instead of the usual rows of seats facing towards the podium, round tables







8

were set out as one would expect for a banquet. Each exhibiting manufacturing company had been provided with a table, at which demonstrations on a wide variety of implantological topics were given by invited experts in three sessions and the arising discussions proved to be very insightful. This new format was met with high acceptance on the part of the congress participants and the industry exhibitors. Another highlight was the online and interactive digital poster presentation, which took place on both congress days, the poster presenters being available in a lounge in the exhibition area directly in front of the conference hall. All posters could also be accessed online via mobile devices. Three prize winners were selected among the submissions on Saturday morning by Dr Tuna. The first prize went to Dr Tim Hilgenfeld, a private lecturer from Heidelberg in Germany, the second prize to the working group of Prof. Christoph Bourauel, Dr Istabak Dörsam and Dr Ludger Keilig, and the third prize to Prof. Ralf Smeets and Dr Sogand Schäfer's Hamburg research group. On the podium, every winner was given the opportunity to briefly present their awarded work to the audience.

### Saturday—the day of science

After the first, quite practice-oriented congress day, the second day focused on the science of implant dentistry. Current trends were outlined, but the question "What will implantology look like in the future?" was given much

attention. Presidents and board members of implantological and other professional societies were invited to give lectures and present the latest trends and visions and their relevance to clinical practice. The Saturday programme of DGZI's annual congress offered scientific overview lectures on all relevant areas of oral implantology, including digital implantology and prosthetics, bone and soft tissue, materials and design. The participants were captivated with presentations on three themes: hard tissue, novel concepts, and soft tissue and its management.

### Session 1: Hard tissue

The scientific programme of the second congress day was kicked off by Prof. Knut A. Grötz, president of the Deutsche Gesellschaft für Implantologie (German society for implantology), who spoke about bone augmentation in locally and systemically compromised cases. In an exciting overview of the history of augmentative surgery, Prof. Grötz outlined how "all past paradigms have been surpassed". While there is still an isolated need for iliac crest grafts, their number continues to decrease in favour of local and regional augmentation. This is made possible primarily by osteosynthetic procedures and devices. Ultimately, the decisive factor is a systematic classification of patients who are systemically compromised, which, according to Prof. Grötz, is true of 95–97% of all patients with compromised bone. Such a classification would enable the choice to be made against augmentation and in favour of reduced-diameter and short implants. The credo of Prof. Grötz, who is an oral surgeon from Wiesbaden in Germany, is that the goal and key should be personalised implant dentistry.

Prof. Bilal Al-Nawas, director of maxillofacial surgery at the University Medical Center of Johannes Gutenberg University Mainz in Germany, demonstrated what has been made possible over the past 50 years with a view to implants, bone and soft tissue. In eloquent fashion, he stated, "with implantology, it's like with the miniskirt: it all returns eventually". Indeed, his literature review of publications from the 1970s proved that at the time there were already techniques available that worked and that satisfied patients. These were



10

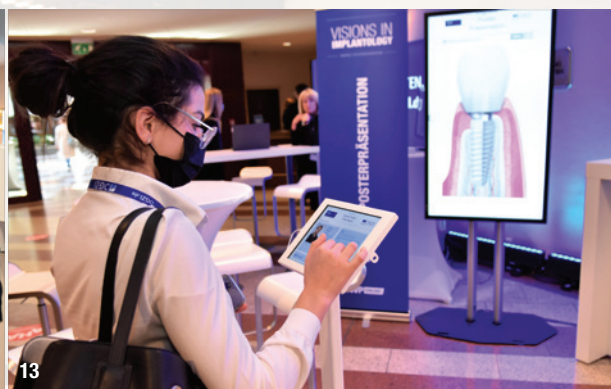

11





**Fig. 12:** CAMLOG dual leadership: Martin Lugert (left) and Markus Stammen.



**Fig. 13:** A highlight was the digital poster presentation, the winners of which were awarded prizes on Saturday afternoon.

refined, however, and new options were added. In this context, the focus on titanium as the implant material represented an important step, according to Prof. Al-Nawas. The 1990s were distinguished by the development of new implant systems, some of which are still on the market today. In the same period, new procedures with predictable results were established, such as the sinus lift. The years after the turn of the millennium were characterised by observations on late complications of implant treatment that are of a biological and technical nature. The speed of osseointegration was significantly increased by the development of new implant surfaces, and handling of the gingival cuff was significantly improved in implants with platform switching, which is vital when it comes to the interaction between gingiva and bone. Prof. Al-Nawas noted that the most recent achievements have included reduced-diameter and extremely short implants, as well as implants made from zirconia.

Prof. Christian Gernhardt, a university lecturer from Halle in Germany, continued to push boundaries, introducing himself as “the preserver of teeth who stands in the way of implant dentists”. In his lecture, he outlined when tooth preservation and when implant treatment is the better choice. Decision-making today is increasingly moving in the direction of tooth preservation and root canal therapy mainly owing to new techniques and procedures and industrial developments in the field of endodontics, he explained, and the debate around peri-implantitis has only spurred this on. According to Prof. Gernhardt, root canal therapy is the treatment of an infectious disease and the interface between endodontics and medicine plays a major role in this regard in the sense of individualised medicine. Prof. Gernhardt concluded his lecture by arguing that “tooth preservation always comes first”.

## Session 2: Novel concepts

Following on from his impressive live surgery on the previous day, Prof. Grubeanu once again emphasised the importance of immediate implant placement in daily practice as part of his lecture. He stressed that resorptive

processes always occur—regardless of way the socket is filled up. Placement of the implant 1 mm sub-crestally and in an optimal 3D position is a key prerequisite for this implantation protocol. Based on Wolff’s postulates from 1892, Prof. Grubeanu asserted that bone must be loaded in order for it to be preserved, substantiating his argument for immediate implant placement and immediate loading. Excellently documented case studies supported Prof. Grubeanu’s conclusion: “Immediate loading and immediate implant placement brings joy for both patient and dentist.” Prof. Smeets then defined risk factors in implant dentistry and pointed to the need to consider patients’ vitamin deficiencies, metabolic diseases and medications. He reported that 30% of patients have inadequate vitamin D levels, and he recommends supplementation ahead of major implant procedures, such as sinus lift. He also discussed the consequences of taking proton pump inhibitors—information that was met with great interest on the part of the attendees. Dr Wolfgang Jakobs, chairman of the Berufsverband Deutscher Oralchirurgen (professional association of German oral surgeons), subsequently elaborated on his main discipline: anaesthetic procedures in implantology. Dr Jakobs noted that psychosomatic disorders have increased by over 30% in recent years, and he provided practical tips on local anaesthesia in dentistry, current sedation procedures and general anaesthesia. According to Dr Jakobs, the titrated administration of midazolam has established itself as the gold standard for sedation owing to its high level of safety.

## Session 3: Soft tissue and its management

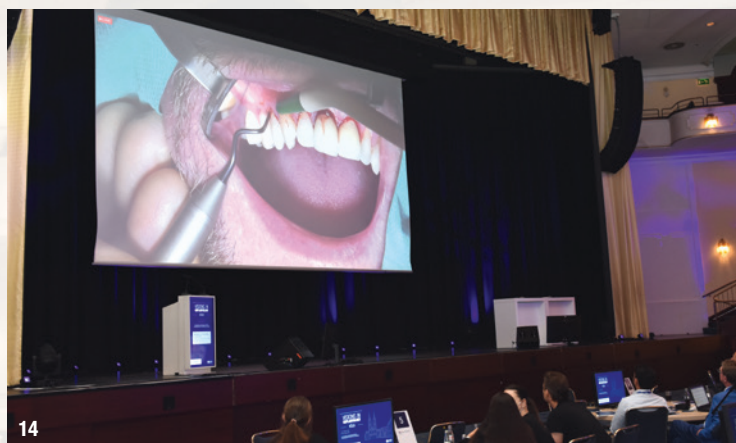The question of material was posed by Prof. Florian Beuer, who discussed different materials for implant prostheses. “Very often I see implant-supported restorations with excellent implant placement but only average prostheses,” said Prof. Beuer, chairman of the Department of Prosthodontics, Geriatric Dentistry and Craniomandibular Disorders at Charité—Universitätsmedizin Berlin. “That’s really a shame!” He believes that a remedy can be found in the continued exploration of material-specific potential, such



an example being tooth-coloured materials such as zirconium dioxide, which has proved to be advantageous in terms of aesthetics and biocompatibility. However, the pursuit of developing ever more translucent materials from zirconium dioxide has meant that losses in material strength have had to be accepted and so only first- and second-generation zirconium dioxide materials should be used in the posterior region. According to Prof. Beuer, it is furthermore impossible to imagine implant prostheses today without the modern generation of acrylics—especially since they can be processed in CAD/CAM procedures. For complex restorations, these new high-performance acrylics can be put to use successfully.

Subsequently, Prof. Thorsten M. Ausschill, a lecturer at the department of periodontics of the University of Marburg, posed the question “How do I create optimal tissue conditions?” and in his lecture addressed the topic of soft-tissue defects in answering this. Right at the beginning of his presentation, Prof. Ausschill clarified that untreated periodontitis and peri-implantitis lead to soft-tissue loss. His lecture put great focus on recessions and the treatment options for covering them. DGZI past president Prof. Friedhelm Heinemann, from the University of Greifswald in Germany, spoke about implant and prosthetic restorations and their potential. He began by revisiting an old topic, as he described it in his introductory remarks: bone stability around the implant. In this context, platform switching plays a central role, according to Prof. Heinemann, and stability is enhanced by a taper, because “we have to get away from the bone!” he explained. However, since the taper carries a rather high fracture risk and may have aesthetic disadvantages in the maxillary anterior region, Prof. Heinemann sought to incorporate both taper and platform switching in one implant system. He received support for this project from the working group headed by Prof. Bourauel, the results of which led to the development of a product line. Prof. Heinemann’s presentation was rounded off by the results of his own randomised controlled trial.


The closing lecture of the 50<sup>th</sup> DGZI annual congress was delivered by yet another DGZI past president: Prof. Frank Palm, who answered the question of how to preserve alveolar bone after tooth extraction. Prof. Palm heads the clinic for oral and maxillofacial surgery at Klinikum Konstanz hospital in the city of Constance in Germany and also a large outpatient clinic. He has been known for years as an eloquent and committed advocate of bone substitutes. His remarks at the congress were also dedicated to this topic. Prof. Palm presented a product he co-developed, CERASORB Foam, which is a beta-tricalcium phosphate foam designed to lead to the preservation of lamellar bone. In addition, this new material is particularly beneficial in terms of volume preservation, according to Prof. Palm. Should implant surgery be performed in such a pretreated bone area, a drilling protocol for soft bone is required. Small, not yet organised beta-tricalcium phosphate remnants can be left in a site like this.



**Fig. 14:** Transmission of the live operation into the conference hall of the Future Congress.

## A brief summary

At the 50 plus one congress in Cologne, participants experienced an outstanding and innovative continuing education event and a worthy anniversary celebration of the oldest European implantological expert society. But not only that: by looking at implantology from different angles—science, practice, politics and industry—a new level of interaction was achieved. By attempting to address the urgent question of what implantology will look like in five or perhaps ten years from now and what the political and economic framework conditions will be then, new ground was broken on the part of DGZI, whose members shared the stage with the who’s who in German-speaking dental implantology. “We are pleased, grateful and happy about this beautiful anniversary congress and we are glad that we have taken new paths with our Future Congress!” said Dr Bach. As a conclusion of the third Future Congress, it can be stated that, with regard to the implantological practice of the future, in addition to scientific and technological aspects, it is primarily a matter of answering strategic questions. DGZI will continue to work actively on this topic with the aim of demonstrating the importance and appeal of its professional society in the 50 (plus one) years to come.



## contact

**Dr Georg Bach**  
doc.bach@t-online.de

## CleanImplant Ambassadors' Summit 2021

## Safeguarding the established—Daring the new

On 3 November 2021, members of the scientific advisory board and ambassadors from 16 different nations met for the second



Members of the scientific advisory board and CleanImplant ambassadors at the Summit 2021 in Como, Italy.

CleanImplant Ambassadors' Summit at Lake Como in Italy. The independent foundation evaluates the quality of implants worldwide in officially accredited testing laboratories and awards its prestigious trusted quality award for implant types with a particularly clean surface. Prof. Tomas Albrektsson from the Sahlgrenska Academy in Gothenburg, Sweden, emphasised the necessity and the requirement that implants must not only be sterile when delivered from the factory but also free of foreign particles. Prof. Hugo de Bruyn, University of Nijmegen, Netherlands, presented interim results of a study analysing the presence of metal particles in the peri-implant sulcus fluid in correlation to the respective peri-implantitis status. Madris Kinard Tomes, data specialist and former FDA employee, broadcasted live from Pennsylvania to help interpret the rapidly increasing adverse events of oral implants. Dr Dirk U. Duddeck, CEO and head of research of the foundation, summarised the results of a recent comparative study of more than 100 implants. The participants discussed strategies for supporting manufacturers delivering uncompromised medical devices and how to defend the foundation against unjustified legal threads from manufacturers providing implants of inferior quality.

**Source: CleanImplant Foundation**

## Dr Elisabeth Jacobi-Gresser joins

## DGZI board as new education officer

On the day before the 3<sup>rd</sup> Future Congress and 50<sup>th</sup> International Annual Congress of the DGZI, the annual general meeting took place. In addition to the reports of the various board members and the presentation and approval of the budget, elections were held and important board positions were reassigned. Dr Elisabeth Jacobi-Gresser, an oral surgeon from Mainz, was elected the new education officer to the DGZI board. Dr Jacobi-Gresser has been associated with the DGZI for a long time and has already been intensively involved in the association's work in the scientific support of the *Lernbuch Implantologie*, the online campus and the continuing educational programme. The new training officer was also actively involved in the redesign of the successful implantology curriculum. Dr Jacobi-Gresser was and is the DGZI delegate to the guidelines conference of material incompatibility. There was also a change in the position of the DGZI auditor. The long-standing 1<sup>st</sup> cash auditor Dr Uwe Ryguschik was bid farewell and the Hamburg dentist Dr Marcus Quitzke was elected in his place. President Dr Georg Bach and the entire board of the DGZI welcomed the new election of Dr Jacobi-Gresser and see in the experienced dentist and oral surgeon a confirmation and the possibilities for further development of the innovative training activities of the DGZI.

With the new election of Dr Quitzke, the DGZI also takes an important step forward in placing younger dentists in important positions of the association and thus ensuring a long-term generational change.

**Source: DGZI**



Part of the new DGZI board (from left): Dr Georg Bach, Dr Arzu Tuna, Dr Elisabeth Jacobi-Gresser and Dr Rolf Vollmer.



Premium Partner:

**Geistlich**  
Biomaterials

---

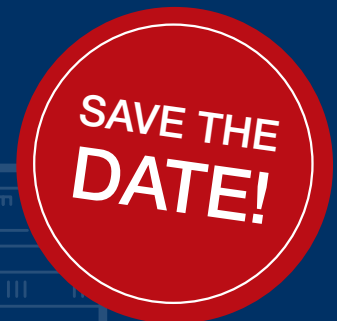# 51<sup>ST</sup> INTERNATIONAL ANNUAL CONGRESS OF **DGZI**

---

30 September/1 October 2022  
Hotel Berlin Central District



© Alexandr Bakanov – stock.adobe.com



**DGZI**  
Deutsche Gesellschaft für  
Zahnärztliche Implantologie e.V.

# Congresses, courses and symposia



## ADI Team Congress 2022

26–28 May 2022  
Manchester, UK  
[www.adi.org.uk](http://www.adi.org.uk)



## AAID Annual Conference

21–24 September 2022  
Dallas, TX, USA  
[www.aaid.com/annual\\_conference](http://www.aaid.com/annual_conference)



## 29<sup>th</sup> annual scientific meeting of EAO

29 September–1 October 2022  
Geneva, Switzerland  
[www.eao.org](http://www.eao.org)



## 51<sup>st</sup> International Annual Congress of DGZI

30 September–1 October 2022  
Berlin, Germany  
[www.dgzi-jahreskongress.de](http://www.dgzi-jahreskongress.de)

# implants

international magazine of oral implantology

## Imprint

### Publisher

Torsten R. Oemus  
[oemus@oemus-media.de](mailto:oemus@oemus-media.de)

### CEO

Ingolf Döbbecke  
[doebbecke@oemus-media.de](mailto:doebbecke@oemus-media.de)

### Member of the Board

Lutz V. Hiller  
[hiller@oemus-media.de](mailto:hiller@oemus-media.de)

### Chairman Science & BD

Jürgen Isbaner  
[isbaner@oemus-media.de](mailto:isbaner@oemus-media.de)

### Chief Editorial Manager

Dr Torsten Hartmann  
(V. i. S. d. P.)  
[hartmann@dentalnet.de](mailto:hartmann@dentalnet.de)

### Editorial Council

Dr Rolf Vollmer  
[info.vollmer@t-online.de](mailto:info.vollmer@t-online.de)

Dr Georg Bach  
[doc.bach@t-online.de](mailto:doc.bach@t-online.de)

Dr Suheil Boutros  
[SMBoutros@aol.com](mailto:SMBoutros@aol.com)

### Editorial Office

Georg Isbaner  
[g.isbaner@oemus-media.de](mailto:g.isbaner@oemus-media.de)

Johannes Liebsch  
[j.liebsch@oemus-media.de](mailto:j.liebsch@oemus-media.de)

Janine Conzato  
[j.conzato@oemus-media.de](mailto:j.conzato@oemus-media.de)

### Executive Producer

Gernot Meyer  
[meyer@oemus-media.de](mailto:meyer@oemus-media.de)

### Product Manager

Timo Krause  
[t.krause@oemus-media.de](mailto:t.krause@oemus-media.de)

### Art Director

Alexander Jahn  
[a.jahn@oemus-media.de](mailto:a.jahn@oemus-media.de)

### Designer

Franziska Schmid  
[grafik@oemus-media.de](mailto:grafik@oemus-media.de)

### Customer Service

Marius Mezger  
[m.mezger@oemus-media.de](mailto:m.mezger@oemus-media.de)

### Published by

OEMUS MEDIA AG  
Holbeinstraße 29  
04229 Leipzig, Germany  
Tel.: +49 341 48474-0  
Fax: +49 341 48474-290  
[kontakt@oemus-media.de](mailto:kontakt@oemus-media.de)

### Printed by

Silber Druck oHG  
Otto-Hahn-Straße 25  
34253 Lohfelden, Germany

**implants**  
**international magazine of** oral  
implantology is published in cooperation  
with the German Association of Dental  
Implantology (DGZI).

### DGZI

DGZI Central Office  
Paulusstraße 1  
40237 Düsseldorf, Germany  
Tel.: +49 211 16970-77  
Fax: +49 211 16970-66  
[office@dgzi-info.de](mailto:office@dgzi-info.de)

[www.dgzi.de](http://www.dgzi.de)

[www.oemus.com](http://www.oemus.com)

[www.implants.de](http://www.implants.de)



## Copyright Regulations

**implants international magazine of** oral implantology is published by OEMUS MEDIA AG and will appear with one issue every quarter in 2021. The magazine and all articles and illustrations therein are protected by copyright. Any utilisation without the prior consent of editor and publisher is inadmissible and liable to prosecution. This applies in particular to duplicate copies, translations, microfilms, and storage and processing in electronic systems.

Reproductions, including extracts, may only be made with the permission of the publisher. Given no statement to the contrary, any submissions to the editorial department are understood to be in agreement with a full or partial publishing of said submission. The editorial department reserves the right to check all submitted articles for formal errors and factual authority, and to make amendments if necessary. No responsibility shall be taken for unsolicited books and manuscripts. Articles bearing symbols other than that of the editorial department, or which are distinguished by the name of the author, represent the opinion of the aforementioned, and do not have to comply with the views of OEMUS MEDIA AG. Responsibility for such articles shall be borne by the author. Responsibility for advertisements and other specially labeled items shall not be borne by the editorial department. Likewise, no responsibility shall be assumed for information published about associations, companies and commercial markets. All cases of consequential liability arising from inaccurate or faulty representation are excluded. General terms and conditions apply, legal venue is Leipzig, Germany.

IT'S SIMPLE  
TO BE A  
**WINNER**



**MIS**® | **SEVEN**®

**PROVEN SUCCESS MEETS ENHANCED STABILITY. MAKE IT SIMPLE**

The biological stability and predictable esthetics of the SEVEN, combined with the extensive research and development process have given the SEVEN a potential advantage in soft tissue preservation and growth as well as an array of restorative benefits. Learn more about the SEVEN implant system and MIS at: [www.mis-implants.com](http://www.mis-implants.com)



# SOME STARS SHINE BRIGHTER THAN OTHERS.

**CLEANIMPLANT QUALITY EVALUATION**  
INDEPENDENT. THOROUGH. RELIABLE.

In-Kone  
**GLOBAL D**

AnyRidge  
**MEGAGEN**

ICX-Premium  
**MEDENTIS MEDICAL**

Patent/BioWin!  
**ZIRCON MEDICAL**

T6  
**NUCLEOSS**

Conelog  
**CAMLOG**

Prama  
**SWEDEN & MARTINA**

NobelActive  
**NOBEL BIOCARE**

UnicCa  
**BTI**

Standard SLA  
**STRAUMANN**

SDS  
**SWISS DENTAL  
SOLUTIONS**

BlueSky  
**BREDENT MEDICAL**

Kontakt S  
**BIOTECH DENTAL**



- We check the quality of implants you use in your practice.
- Provide more safety for your patients and avoid negligence claims.
- Win new patients as a CleanImplant Certified Dentist.
- Find out more. Join the project.



More information:  
[www.cleanimplant.com/dentists](http://www.cleanimplant.com/dentists)

**CLEAN IMPLANT**  
FOUNDATION